

Rahim & Yaqin 2022.docx

by Digital Creative

Submission date: 26-Jul-2024 06:00AM (UTC-0700)

Submission ID: 2421825697

File name: Rahim_Yaqin_2022.docx (337.81K)

Word count: 6638

Character count: 40307

RESEARCH ARTICLE

Histological Alteration of Green Mussel *Perna viridis* Organs Exposed to MicroplasticsNur Fadhillah¹, Nur Rahim¹ and Khusnu Yaqin^{2*}

OPEN ACCESS

¹ Aquatic Resource Management Study Program, Faculty of Fisheries and Marine, Universitas Muhammadiyah Mamuju, Mamuju, 1511, Indonesia

² Department of Fisheries, Faculty of Marine Science and Fisheries, Universitas Hasanudin, Makassar, 90245, Indonesia

* Corresponding Author: khusnu@unhas.ac.id

Received: 12 November 2021

Accepted: 9 March 2022

Published: 25 May 2022

Academic Editor: Dr. Nuning Vita Hidayati

¹ Squalen Bulletin of Marine and Fisheries, Fisheries and Biotechnology, 2021. Accreditation Number: 148/M/KPT/2020. ISSN: 2089-5690, e-ISSN: 2406-9272. <https://doi.org/10.15578/squalen.597>

Abstract

Microplastic in the oceans might interfere the health of marine organisms, including the green mussels (*Perna viridis*). This is due to microplastic accumulation in mussels organs, such as gills, hepatopancreas, and gonads. Therefore, tissue alteration is a good indicator for ecological risk analysis and other ecotoxicological study activities. Green mussels with shells 4.1 to 5.0 cm length were collected from Mandalle waters, Pangkep Regency (Pangkajene), Indonesia. Green mussels were exposed for seven days to microplastic with concentrations of 0.05 (A), 0.5 (B), and 5 (C) g/L. The results showed that higher the concentration of microplastics exposed to the green mussel, the higher the accumulation of microplastics in the body of the mussel, within the tested concentrations. The increased concentration of microplastics increased the level of tissue alteration in the gills, hepatopancreas, and gonads, with the most sensitive organ being the hepatopancreas. Overall, the study confirmed that the histological assay of mussel organs could be used as a biomarker in ecotoxicological studies.

Keywords: green mussel, microplastic concentration, tissue alteration

Introduction

Plastic is light, strong, durable, inexpensive (Gamarro et al., 2020), and corrosion-resistant. It is also a good thermal and electrical insulator (Dowarah et al., 2020). These versatile characteristics have made plastics extensively used in daily life (Gamarro et al., 2020). The amount of plastic waste has reached 368 million tonnes since it was produced in the 1950s (Plastics Europe, 2020). In 2100, about 9.6-48.8 particles/m of plastics are predicted to float around the ocean (Prokic et al., 2019). This rapid increase in the production and distribution of plastic materials has an enormous impact on the environment and ecology (Prokic et al., 2019) because they are naturally difficult to degrade (Ma et al., 2019).

Plastics exist nearly everywhere in the environment, i.e., water, soil, air, etc (Sun et al., 2020). Approximately 1.15 - 2.41 million tons of plastic waste enter the oceans and keep increasing every year (Lebreton et al., 2017). Blettler et al. (2018) said that 87% of plastic pollution studies are related to marine environments and only 13% to freshwater systems. The plastic debris existence in the environment has

attracted the attention of researchers, policymakers, the general public, and various environmental institutions (Gray et al., 2018).

Plastic particles with sizes less than 5 mm are called microplastics (Peixoto et al., 2019). Plastic materials are composed of polymers with varying types, sizes, shapes, and chemical compositions (Kühn et al., 2018). Microplastics may contain chemical pollutants like plastic monomers and additives that adsorb toxic contaminants from the marine environment (Boyle et al., 2020; Fernández et al., 2020; Luo et al., 2019; Zhang et al., 2020). Moreover, they could act as an additional exposure pathway to marine pollutants then transfer the hydrophobic contaminants to aquatic organisms (Webb et al., 2020). Hence, the impact of microplastics on marine life Occured individually and integrated with other marine pollutants (Gu et al., 2020).

Furthermore, the effects of microplastic exposure are varied across different marine and freshwater taxa (Foley et al., 2018). Microplastic exposure might affect feeding behavior, growth, reproduction, and survival (Galloway & Lewis, 2016). The size of microplastic makes them unintentionally consumed by various organisms, such as zooplankton (Botterell et al., 2019),

1 worms (Revel et al., 2018), mussels (Scott et al., 2019), sea urchins (Murano et al., 2020), and also on early life stages of marine bivalves (Bringer et al., 2020). Microplastics are bioavailable in every organism in trophic transfer by ingestion, bioaccumulation, and biomagnification (Au et al., 2017).

The mussel could accumulate microplastics during filter-feeding (Woods et al., 2018). Microplastics enter and meet the surface of the gills, then captured and trapped in the mucus. Thereafter, they will go through two processes. The first one is assimilated with the gill epithelium, or transported into the mouth and hepatopancreas (Bråte et al., 2018; Kolandhasamy et al., 2018). The second process is related to the feeding process, independent of the type of microplastics (Wei et al., 2021). Microplastic particles can reduce feeding activity through decreased filtration rate (Pedersen et al., 2020), affecting the immune (Sykdokur et al., 2020) growth and reproduction systems (Chae & An, 2017). They might change tissue morphology and even lead to tissue necrosis (Bråte et al., 2018).

Mussels are widely distributed, easily accumulate microplastics, and closely related to the food chain, making them a good sentinel organism for microplastic pollution (Li et al., 2019). They have physiological properties and biomarkers appropriate for assessing the effects of multiple stressors following environmental disturbances (Webb et al., 2020). Bivalve histopathology has become an essential instrument in aquatic toxicology, performed by many biomonitoring programmers worldwide (Cuevas et al., 2015). Woods et al. (2018) evaluated the ingestion rate and fate of microplastics taken up by *Mytilus edulis*; meanwhile, González-Soto et al. (2019) used *M. galloprovincialis* as a sentinel organism to observe the long-term effects of BaP-polystyrene exposure. Moreover, Webb et al. (2020) used *Perna canaliculatus* to examine the impact of microplastics individually or combined with triclosan. Dowarah et al. (2020) also used *P. viridis* to analyze the accumulation of microplastics from three estuaries.

Evaluating microplastic exposure in organisms from the natural environment is challenging. This is due to the microplastic heterogeneity and low abundance, in the wild. The effects of microplastics are also difficult to be distinguished from those of other xenobiotic (Prokic et al., 2019). Therefore, laboratory-based studies are necessary to generate potential impacts of microplastic exposure (Kühn et al., 2018). Most studies about the toxicity of microplastics have focused on their impacts on marine invertebrates and vertebrates in laboratory conditions (Prokic et al., 2019).

There are not many studies that determine the tissue damage of green mussel organs exposed to

microplastics. Information on tissue alteration is important to conduct ecological risk analysis and other ecotoxicological studies. Consequently, this paper will discuss the tissue alteration of green mussel *P. viridis* due to microplastic exposure.

Material and Methods

Sample Collection

A total of 144 green mussels ranging from 4.1 to 5.0 cm in size were obtained from Mandalle waters, Pangkep Regency (Pangkajene Islands) in July, 2019 (dry season). Green mussels were cleaned from biofouling, acclimatized for 14 days in an aquarium before the experiment, and fed with 1.2 g/L *Spirulina* sp daily before medium replacement (Rist et al., 2016). The acclimatization condition of the laboratory aquarium was as follows: 1 L seawater at 28 °C temperature, 35 ‰ salinity, and cell density of 77×10^6 cells/L (Yaqin et al., 2019). Prior to daily water replacement, pH, temperature, DO and salinity were measured (Lee et al., 2013).

Microplastic Preparation Methods

Microplastics were extracted from a commercial bath scrub. The bath scrub was dissolved with water then filtered using three different sieves (0.075, 0.125, and 0.180 mm). The particles were placed into a petri dish then heated in the oven at a temperature of 90 °C for 48 h (Bråte et al., 2018).

Exposure and Experimental Design

The samples were divided into four categories of treatments, i.e., control (no added pollutant), 0.05 (A), 0.5 (B), and 5 (C) g/L of microplastics, in triplicate (Santana et al., 2017). Each of microplastic concentration used in this study was higher than those observed in the natural habitat (Colen et al., 2021). Approximately 0.1 g of the added pollutant contained $3,309 \pm 239.4$ microplastic particles.

Every 12 green mussels were placed in an aquarium containing five liters of seawater from Sea Ranching and Ecosystem Rehabilitation Laboratory, Hasanuddin University. The seawater was filtered with Unilever Pure It Water Purifier. The green mussels were exposed to bath scrub microplastic mixed with *Spirulina* sp and starch flour as added pollutants for seven days (Paul-Pont et al., 2016).

The media was changed every day (Pittura et al., 2018) to ensure the depurated microplastics by them

1 green mussel, and were not re-filtered by the tested animals (Cauwenbergh & Janssen, 2014). Water quality measurements (pH, temperature, DO, and salinity) were carried out immediately before the media water replacement (Lee et al., 2013). The aquarium was aerated during the experiment to maintain the oxygen concentration required by the green mussels.

Microplastic and Histological Analysis

After seven days of exposure, the green mussels were removed from the aquarium; hereafter, the microplastics attached to the shells were cleaned using seawater. The green mussel tissue was dissected and transferred to a bottle containing 10% KOH solution. The volume of the KOH solution was three times the weight of the mussel tissue. Afterward, the tissue was stored for seven days at room temperature to digest the organic matter (Rochman et al., 2015). The dissolved green mussel tissue was then filtered using a vacuum pump by a 0.45 μm sterile membrane filter. Subsequently, the filtered microplastics were directly calculated and analyzed under a stereo microscope (Stereoblue - Euromex).

Histological analysis was performed to analyze tissue alteration of the gills, hepatopancreas, and gonads. The target organs of the mussel were dissected out from the mussel shell and fixed with Bouin's solution for 24 h. The organs were dehydrated using ethanol and xylene sequentially (80–100%) and embedded in paraffin. The embedded tissues were cut into a 4 μm section and mounted on a slide, followed by fixation and stained using hematoxylin-eosin according to the standard procedure. The stained slide was observed using a microscope (Olympus CX-23) for histological analysis (Arrighetti et al., 2018; Asaduzzaman et al., 2019).

Calculation of Histological Index (I_h)

Determination of gills, hepatopancreas, and gonads alteration can be seen in Table 1. The table summarized the observations of Bouallegui et al. (2017), Costa et al. (2013), and Cuevas et al. (2015). Each alteration has a different significance value (w_j) (ranging from 1 - 3), and each w_j value was followed by a score (a_{ij}). The score was assigned level 0 (no damage), 2 (minor), 4 (moderate), and 6 (severe). The provision as followed: the value of w_j = 1 for a = 2, w_j = 2 for a = 4, and w_j = 3 for a = 6. The histological index (I_h) of the gills, hepatopancreas, and gonads was calculated using the formula of Costa et al. (2013) as follows:

$$I_h = \frac{\sum w_j a_{ij}}{M_j}$$

Note:

- I_h = histological condition indices
- w_j = the weight of alteration
- a_{ij} = score of attribute
- M_j = the maximum attributable value

Data Analysis

The normality and homogeneity tests were used to process the data before analyzing the variance. The differences in microplastic accumulation were analyzed

Table 1. General histological alteration of mussel organs

Organ	Reaction pattern	Alteration	w _j
Gill	Cell alteration	lamellar fusion (Lf)	1
		Hyperplasia (hp)	2
		Loss of epithelia (Le)	3
		Necrosis (n)	3
Hepatopancreas	Tubule alteration	Vacuolisation (v)	1
		Hyperplasia (hp)	2
		Tubule regression (tr)	2
		Necrosis (n)	3
Gonad	Cell alteration	Intertubular alteration	3
		Hemocyte infiltration (hi)	1
		Necrosis (n)	3

1 statistically using Parametric ANOVA followed by post-hoc analysis. The histological alteration was observed descriptively.

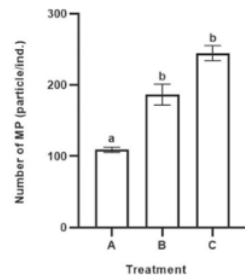
Results and Discussion

Microplastics Accumulation

The average microplastic accumulation by green mussels in treatments A, B, and C were 109, 186, and 244 particles/individual, respectively (Figure 1). The statistical tests showed significant differences (p<0.05) in the total microplastics between treatments A and B also A and C. However, there was no significant difference between treatments B and C, despite the increasing trend. The results showed that the higher the concentration of microplastics exposed to the green mussel, the higher the concentration of microplastics in the body of the mussel, within the tested concentrations.

Tissue Alteration

1 The histological feature of the target organs reflected the health condition of mussels due to microplastic



1 Note: Different letters indicate significant differences at $p < 0.05$.

Figure 1. The number of microplastic particles in the body of green mussel at each treatment.

exposures (Bråte et al., 2018). The comparison between control and the treatments showed no histological alteration in the control. Green mussels exposed to microplastics with various concentrations for seven days showed tissue alterations or damages in each organ. The level of alteration increased along with the increase of tested microplastic concentrations (Figures 2-4). Treatment A caused the gill tissue to experience hyperplasia. It has also caused the hepatopancreas tissue to encounter vacuolization, hyperplasia, and necrosis. Meanwhile, treatment B triggered lamellar fusion, loss of epithelia and necrosis as well as the increased level of alteration (vacuolization, hyperplasia, tubule regression, tubule & intertubular necrosis). Moreover, gonad tissue went through hemocyte infiltration caused by treatment A, followed the hemocyte infiltration and necrosis after exposure to treatment B (Figures 2 - 4). Koagou & Ciocan (2019) found different histological damage compared to every group treatment, indicating a correlation between higher concentrations of microplastics. The largest particles and higher concentrations lead to severe effects (Bour et al., 2018). Mussels living under pressures, such as microplastic exposure, for a long time would run into inflammatory responses and, later on, lower growth and survival (Gu et al., 2020). Some studies indicated that circulating and tissue-accumulated microplastics induced an injury-type inflammatory response (Prokic et al., 2019).

Microplastics enter the body of green mussels and pass through various vital organs. First of all, microplastics enter the gills by cilia movement. Pedersen et al. (2020) explained that the pathway for microplastic accumulation in *Dreissena bugensis* was likely mediated through microvilli on gill surfaces. Furthermore, they were creating passage into the gills via endocytosis. This is an additional potential pathway via ciliary movement, allowing transfer into the digestive tubules. The gills of mussels can regulate the filtration and

sorting of particles based on their size, shape, nutritional value, or chemical component on the surface of the particle. Subsequently, the more nutritious particles are transported to the mouth for ingestion (Xu et al., 2016). Afterward, it could be defined that the gills become a major protective organ toward the accumulation of contaminants, and important organs for metabolic processes of marine life (Zhu et al., 2020). Gills are susceptible organs to chemicals exposure because they have lamellae with a vast surface area that are easily exposed to contaminants in seawater (Au, 2004). Direct contact of the gill epithelium surface with pollutants in the environment will decrease the number of connections between filaments (Bråte et al., 2018).

The gills alterations of green mussels, such as lamellar fusion due to microplastic exposure, were characterized by attaching the two sides of the lamellae. Lamellar fusion is likely caused by lamella hyperplasia (Carvalho et al., 2020). This is also assumed to indicate cell degeneration and eventually a sign of early necrosis (Pribadi et al., 2017). Hyperplasia is characterized by enlargement of the epithelium due to an increasing number of cells that cause dilation on the lamellae; therefore, lamellar fusions were occurred (Figure 2). The histological changes included lamellar epithelium distortion hyperplasia, and cellular connection formed by the two neighbouring filaments, observed in green mussels (sample from the environment) with sizes 6 – 7 cm collected from India (Vasanthi et al., 2021). These alterations occurred in response to contaminants exposure which could interfere with the filtering rate, gas transportation, feeding of mussels (Hariharan et al., 2021), ion regulation, and excretion of catabolic products (Arrighetti et al., 2018).

The following process was the stretched epithelium (the outermost layer of gill tissue). This process is characterized by the incomplete cell structure. These epithelium alterations were followed by necrosis in the gill cilia attached to the epithelium (Figure 2). The ciliary structure of the gills could damage by the presence of plastic particles (Vasanthi et al., 2021). *M. edulis* with a shell length of 4 – 6 cm exposed to 20 $\mu\text{g/L}$ CdCl₂ for eight days experienced alterations of the gills such as epithelial necrosis and loss of cilia (Sheir et al., 2013). *M. galloprovincialis* (4–5 cm shell length) gills suffered thinning filament and decreased frontal and lateral cilia due to exposure to 5 and 10 mg/L TiO₂-NPs for eight days (Gornati et al., 2016). The destruction of the epithelial structure can affect the regular activities of the gill, such as filtering rate, gas transportation, and disrupted feeding (Hariharan et al., 2021).

The microplastic particles passed through the gill organs would be subsequently forwarded to the labial palps that rejected the unwanted particles. Furthermore,

they were disposed of in the form of pseudofaeces in sediment through the exhalant channel into the mouth, and then forwarded into the hepatopancreas. Since microplastics contaminated the hepatopancreas, vacuoles (vacuolization) appeared in the hepatopancreas epithelium. They were characterized by the appearance of irregular empty spaces (Figure 3). Forming of vacuoles can indirectly affect the feeding behavior (Hariharan et al., 2021), hence could inhibit the absorption of ions needed by the body.

The subsequent alteration was hyperplasia in the hepatopancreas epithelium, characterized by a wavy-looking epithelium (Figure 3). This was occurred due to an increasing number of cell epithelium. Hyperplasia disturbs the digestive gland, metabolic, homeostatic balance processes, and the immune system that causes non-optimally detoxification processes (Rocha et al., 2016). Disorders of the hepatopancreas inhibited digestive and metabolic processes (Zupan & Kalafatic, 2003) that could finally interfere the green mussels' fitness.

Tubular regression of hepatopancreas in green mussels could be seen from the unclear lumen shape and cell loss, which subsequently became necrosis

(Figure 3). Green mussels with sizes of 6–7 cm from Indian water experienced disruption in the lumen, i.e., lumen dilation and atrophy with the formation of cellular desquamate (Vasanthi et al., 2021). The destruction of cells in the tubules indicated necrosis (Katalay et al., 2016).

Intertubula plays a significant role in blood circulation. Hence, necrosis could obstruct blood circulation (Factor & Naar, 1985). Necrosis occurred in the tubules, and the intertubular could be seen from the irregular lumen structure; also the non-intact intertubular (Figure 3). Necrosis was also observed in intertubular tissue of *M. galloprovincialis* with sizes of 3.5–5.5 cm collected from sites contaminated with organic and inorganic toxicants along the coast (Cuevas et al., 2015). Microplastics last longer in the mollusc hepatopancreas (Woods et al., 2018) reasonably to their role in phases I and II detoxification (Arrighetti et al., 2018). Figure 3 shows the necrosis of the hepatopancreas tissue. The microplastic accumulation in the digestive gland has impaired mussel activities with a consequent decrease in feeding behavior and physiological changes (Vasanthi et al., 2021). Microplastic accumulation followed by

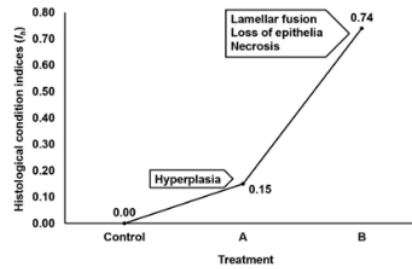
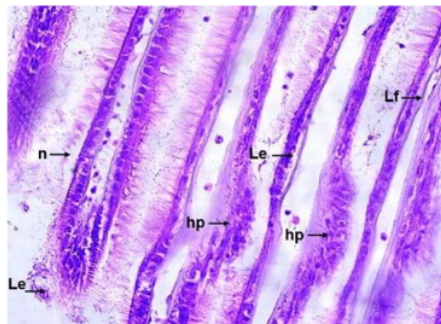


Figure 2. The gills tissue of green mussels (40x magnification). Lf: Lamellar fusion; hp: hyperplasia; Le: Loss of epithelia; n: necrosis (left). Histological index (I_g) of green mussels gills based on microplastics exposure level (right).

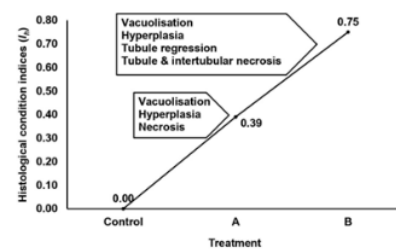
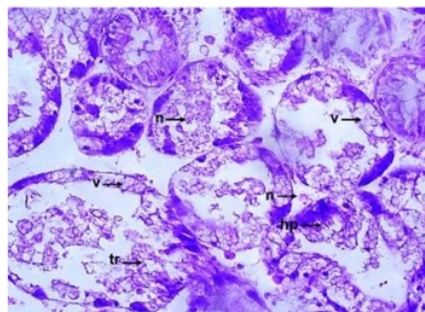


Figure 3. The hepatopancreas tissue of green mussels (40x magnification): v: vacuolisation; hp: hyperplasia; tr: tubule regression; n: necrosis (left). Histological index (I_h) of green mussels hepatopancreas based on the level of microplastics exposure (right).

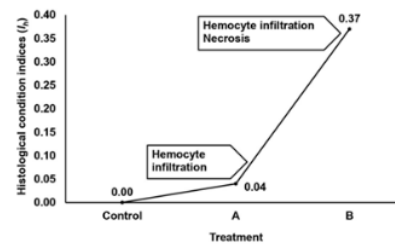
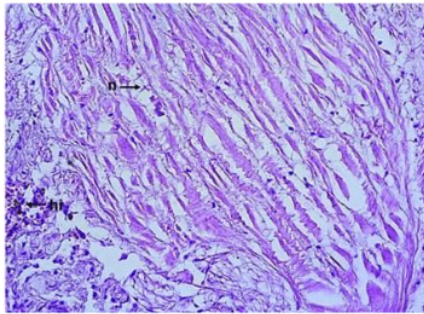


Figure 4. The gonadal tissue of green mussels female (40x magnification). hi: hemocyte infiltration; n: necrosis (left). Histological index (I_h) of green mussels gonad based on microplastics exposure level (right).

alterations of the tissue structures may affect biochemical pathways leading to failure of the digestive gland function. As a final consequence, it would lead to the death of the organism (Arrighetti et al., 2018).

The gonadal organs encountered hemocyte infiltrations indicated by an increase in the number of hemocytes (granular) in the tissue (Figure 4). Hemocyte infiltration is a histopathological condition frequently observed in animals after stress-inducing exposure (Koagouw & Ciocan, 2019). This was found in *M. galloprovincialis* (3.5-4.5 cm shell length) exposed to polystyrene microplastics alone and mixed with benzo[a]pyrene for 26 days (González-Soto et al., 2019). Hemocyte infiltration was also observed in the apple snail (*Pomacea canaliculata*) (\pm 3 cm shell length) exposed to the insecticide Cypermethrin (10, 25, & 100 μ g/L) for 14 days (Arrighetti et al., 2018) and in eastern oysters (*Crassostrea virginica*) exposed to graphene oxide (1 & 10 mg/L) for 72 h (Khan et al., 2019). In addition, brown mussel *P. perna* (6 cm shell length) exposed to toxic dinoflagellate (900 cells/ml) for 96 h was also experienced hemocyte infiltration (Neves et al., 2019).

Hemocyte infiltration was categorized as a mild level (Yee-Duarte et al., 2018) as a consequence of an initial response to the body's mechanism against the foreign substance. Hemocyte infiltration indicated a repairing process of damaged tissue (González-Soto et al., 2019); accordingly, the the damaged tissue showed an inflammatory response (Costa et al., 2013). The increased number of hemocytes in the hemolymph vessels and the invasion of hemocytes into cells were signals of the defense mechanism in the body (David et al., 2008).

This microplastic exposure also caused necrosis in egg cells (Figure 4). Bråte et al. (2018) observed that the gonad tissues underwent necrosis after exposure to microplastics. Necrosis was caused by the cessation

of egg maturation (Blazer, 2002). Based on the histopathological damage score, necrosis was categorized as the level of severe damage (Yee-Duarte et al., 2018). Necrosis in gonad tissue impaired the fecundity and fertility of the organism (Galloway et al., 2017). Gonadal tissue damage and gamete viability were among the worst impacts of water pollution. These damages led to the decrease of reproductive success rate and the fitness of organisms (Vaschenko et al., 2013). Galloway & Lewis (2016) explained that ingestion of microplastics during gametogenesis negatively impacts reproduction in oysters.

Green mussels exposed to pollutants experienced tissue alteration that could inhibit their life system and disturb the food chain. Farrell & Nelson (2013) found microplastics in the hemolymph of crabs (*Carcinus maenas*), consuming mussels *edulis* exposed to microplastics. Wright et al. (2013) also stated that microplastics would be initiated into the food chain by prey activity. Besides, microplastic exposed to oysters during gametogenesis could have adverse effects and would interfere with individual development in the future (Sussarellu et al., 2016).

Conclusion

This study provides information on the effects of microplastic exposure on tissue alterations of green mussels. Our findings are important to conduct ecological risk analysis and other ecotoxicological studies. Information on green mussel histology could complement a more comprehensive status of quality. The effects of microplastics on other mussel organs, such as intestine and mantle need to be carried out in further studies. Within the tested concentrations, the higher the microplastic concentration exposed to the green mussel, the higher the concentration of microplastics in the body of the mussel. Microplastic

1 exposure led to tissue alteration in the gills, hepatopancreas, and gonads. The severity level of alteration was increased along with the increased of microplastic exposure.

Sp. ETP

Acknowledgment

The author(s) received no financial support for this research and/or the publication of this article.

Supplementary Material

Supplementary material is not available for this article.

References

- Arrighetti, F., Ambrosio, E., Astiz, M., Capitulo, A. R., & Lavarías, S. (2018). Differential response between histological and biochemical biomarkers in the apple snail (*Pomacea canaliculata*) (Gasteropoda: Amulariidae) exposed to cypermethrin. *Aquatic Toxicology*, 194, 140–151. <https://doi.org/10.1016/j.aquatox.2017.11.014>
- Asaduzzaman, M., Noor, A. R., Rahman, M. M., Akter, S., Hoque, N. F., Shakil, A., & Wahab, M. A. (2019). Reproductive biology and ecology of the green mussel *Perna viridis*: A multidisciplinary approach. *Biology*, 8(4), 1–26. <https://doi.org/10.3390/biology8040088>
- Au, D. W. T. (2004). The application of histo-cytopathological biomarkers in marine pollution monitoring: A review. *Marine Pollution Bulletin*, 48, 817–834. <https://doi.org/10.1016/j.marpolbul.2004.02.032>
- Au, S. Y., Lee, C. M., Weinstein, J. E., Hurk, P. V. D., & Klaine, S. J. (2017). Trophic transfer of microplastics in aquatic ecosystems: identifying critical research needs. *Integrated Environmental Assessment and Management*, 13(3), 505–509. <https://doi.org/10.1002/ieam.1907>
- Beyer, J., Green, N. W., Brooks, S., Allan, I. J., Ruus, A., Gomes, T., Bråte, I. L. N., & Schøyen, M. (2017). Blue mussels (*Mytilus edulis* spp.) as sentinel organisms in coastal pollution monitoring: A review. *Marine Environmental Research*, 130, 338–365. <https://doi.org/10.1016/j.marenvres.2017.07.024>
- Blazer, V. S. (2002). Histopathological assessment of gonadal tissue in wild fishes. *Fish Physiology and Biochemistry*, 26, 85–101. <https://doi.org/10.1023/A:1023332216713>
- Blettler, M. C. M., Abrial, E., Khan, F. R., Sivri, N., & Espinola, L. A. (2018). Freshwater plastic pollution: Recognizing research biases and identifying knowledge gaps. *Water Research*, 143, 416–424. <https://doi.org/10.1016/j.watres.2018.06.015>
- Botterell, Z. L. R., Beaumont, N., Dorrington, T., Steinke, M., Thompson, R. C., & Lindeque, P. K. (2019). Bioavailability and effects of microplastics on marine zooplankton: A review. *Environmental Pollution*, 245, 98–110. <https://doi.org/10.1016/j.envpol.2018.10.065>
- Bouallegui, Y., Younes, R. B., Bellamine, H., & Oueslati, R. (2017). Histopathological indices and inflammatory response in the digestive gland of the mussel *Mytilus galloprovincialis* as biomarker of immunotoxicity to silver nanoparticles. *Biomarkers*, 1–11. <https://doi.org/10.1080/1354750X.2017.1409803>
- Bour, A., Haarr, A., Keiter, S., & Hylland, K. (2018). Environmentally relevant microplastic exposure affects sediment-dwelling bivalves. *Environmental Pollution*, 236, 652–660. <https://doi.org/10.1016/j.envpol.2018.02.006>
- Boyle, D., Catarino, A. I., Clark, N. J., & Henry, T. B. (2020). Polyvinyl chloride (PVC) plastic fragments release Pb additives that are bioavailable in zebrafish. *Environmental Pollution*, 263, 1–8. <https://doi.org/10.1016/j.envpol.2020.114422>
- Bråte, I. L. N., Blázquez, M., Brooks, S. J., & Thomas, K. V. (2018). Weathering impacts the uptake of polyethylene microparticles from toothpaste in Mediterranean mussels (*M. galloprovincialis*). *Science of the Total Environment*, 626, 1310–1318. <https://doi.org/10.1016/j.scitotenv.2018.01.141>
- Bringer, A., Thomas, H., Prunier, G., Dubillot, E., Bossut, N., Churlaud, C., Clérandeau, C., Le Bihanic, F., & Cachot, J. (2020). High density polyethylene (HDPE) microplastics impair development and swimming activity of Pacific oyster D-larvae, (*Crassostrea gigas*), depending on particle size. *Environmental Pollution*, 260, 1–9. <https://doi.org/10.1016/j.envpol.2020.113978>
- Carvalho, T. L. A. B., Nascimento, A. A., Gonçalves, C. F. S., Santos, M. A. J., & Sales, A. (2020). Assessing the histological changes in fish gills as environmental bioindicators in paraty and sepetiba bays in Rio de Janeiro, Brazil. *Latin American Journal of Aquatic Research*, 48(4), 590–601. <https://doi.org/10.3856/vol48-issue4-fulltext-2351>
- Cauwenberghe, V. L., & Janssen, C. R. (2014). Microplastics in bivalves cultured for human consumption. *Environmental Pollution*, 193, 65–70. <https://doi.org/10.1016/j.envpol.2014.06.010>
- Chae, Y., & An, Y. J. (2017). Effects of micro- and nanoplastics on aquatic ecosystems: Current research trends and perspectives. *Marine Pollution Bulletin*, 124(2), 624–632. <https://doi.org/10.1016/j.marpolbul.2017.01.070>
- Colen, C. V., Moereels, L., Vanhove, B., Vrielinck, H., & Moens, T. (2021). The biological plastic pump: Evidence from a local case study using blue mussel and infaunal benthic communities. *Environmental Pollution*, 274, 1–8. <https://doi.org/10.1016/j.envpol.2020.115825>
- Costa, P. M., Carreira, S., Costa, M. H., & Caeiro, S. (2013). Development of histopathological indices in a commercial marine bivalve (*Ruditapes decussatus*) to determine environmental quality. *Aquatic Toxicology*, 126, 442–454. <https://doi.org/10.1016/j.aquatox.2012.08.013>
- Cuevas, N., Zorita, I., Costa, P. M., Franco, J., & Larreta, J. (2015). Development of histopathological indices in the digestive gland and gonad of mussels: Integration with contamination levels and effects of confounding factors. *Aquatic Toxicology*, 162, 152–164. <https://doi.org/10.1016/j.aquatox.2015.03.011>
- David, J. A. O., Salaroli, R. B., & Fontanetti, C. S. (2008). The significance of changes in *Mytella falcata* (Orbigny, 1842) gill filaments chronically exposed to polluted environments. *Micron*, 39, 1293–1299. <https://doi.org/10.1016/j.micron.2008.03.001>

- Dowarah, K., Patchaiyappan, A., Thirunavukkarasu, C., Jayakumar, S., & Devipriya, S. P. (2020). Quantification of microplastics using Nile Red in two bivalve species *Perna viridis* and *Meretrix meretrix* from three estuaries in Pondicherry, India and microplastic uptake by local communities through bivalve diet. *Marine Pollution Bulletin*, 153, 1–9. <https://doi.org/10.1016/j.marpolbul.2020.110982>
- Factor, J. R., & Naar, M. (1985). The digestive system of the Lobster, *Homarus americanus* : I. connective tissue of the digestive gland. *Journal of Morphology*, 184, 311–321. <https://doi.org/10.1002/jmor.1051840306>
- Farrell, P., & Nelson, K. (2013). Trophic level transfer of microplastic: *Mytilus edulis* (L.) to *Carcinus maenas* (L.). *Environmental Pollution*, 177, 1–3. <https://doi.org/10.1016/j.envpol.2013.01.046>
- Fernández, B., Santos-Echeandía, J., Rivera-Hernández, J. R., Garrido, S., & Albentosa, M. (2020). Mercury interactions with algal and plastic microparticles: Comparative role as vectors of metals for the mussel, *Mytilus galloprovincialis*. *Journal of Hazardous Materials*, 396, 1–13. <https://doi.org/10.1016/j.jhazmat.2020.122739>
- Foley, C. J., Feiner, Z. S., Malinich, T. D., & Höök, T. O. (2018). A meta-analysis of the effects of exposure to microplastics on fish and aquatic invertebrates. *Science of the Total Environment*, 631–632, 550–559. <https://doi.org/10.1016/j.scitotenv.2018.03.046>
- Galloway, T. S., Cole, M., & Lewis, C. (2017). Interactions of microplastic debris throughout the marine ecosystem. *Nature Ecology and Evolution*, 1(5), 1–8. <https://doi.org/10.1038/s41559-017-0116>
- Galloway, T. S., & Lewis, C. N. (2016). Marine microplastics spell big problems for future generations. *Proceedings of the National Academy of Sciences*, 113(9), 2331–2333. <https://doi.org/10.1073/pnas.1600715113>
- Gamarro, E. G., Ryder, J., Elvevoll, E. O., & Olsen, R. L. (2020). Microplastics in fish and shellfish—A threat to seafood safety? *Journal of Aquatic Food Product Technology*, 29(4), 417–425. <https://doi.org/10.1080/10498850.2020.1739793>
- González-Soto, N., Hatfield, J., Katsumiti, A., Duroudier, N., Lacave, J. M., Bilbao, E., Orbea, A., Navarro, E., & Cajaraville, M. P. (2019). Impacts of dietary exposure to different sized polystyrene microplastics alone and with sorbed benzo[a]pyrene on biomarkers and whole organism responses in mussels *Mytilus galloprovincialis*. *Science of the Total Environment*, 684, 548–566. <https://doi.org/10.1016/j.scitotenv.2019.05.161>
- Gornati, R., Longo, A., Rossi, F., Maisano, M., Mauceri, A., Bernardini, G., & Fasulo, S. (2016). Effects of titanium dioxide nanoparticle exposure in *Mytilus galloprovincialis* gills and digestive gland. *Nanotoxicology*, 10(6), 807–817. <https://doi.org/10.3109/17435390.2015.1132348>
- Gray, A. D., Wertz, H., Leads, R. R., & Weinstein, J. E. (2018). Microplastic in two South Carolina Estuaries: Occurrence, distribution, and composition. *Marine Pollution Bulletin*, 128, 223–233. <https://doi.org/10.1016/j.marpolbul.2018.01.030>
- Gu, H., Wei, S., Hu, M., Wei, H., Wang, X., Shang, Y., Li, L., Shi, H., & Wang, Y. (2020). Microplastics aggravate the adverse effects of BDE-47 on physiological and defense performance in mussels. *Journal of Hazardous Materials*, 398, 1–9. <https://doi.org/10.1016/j.jhazmat.2020.122909>
- Hariharan, G., Purvaja, R., Anandavelu, I., Robin, R. S., & Ramesh, R. (2021). Accumulation and ecotoxicological risk of weathered polyethylene (wPE) microplastics on green mussel (*Perna viridis*). *Ecotoxicology and Environmental Safety*, 208, 1–11. <https://doi.org/10.1016/j.ecoenv.2020.111765>
- Katalay, S., Yavaşoğlu, A., Yiğittürk, G., Oltulu, F., Sarý, G., & Yavaşoğlu, N. U. K. (2016). Histological effects of pollution on gill and hepatopancreas tissues of black mussels (*M. galloprovincialis* L.) from Izmir Bay of Turkey. *Fresenius Environmental Bulletin*, 25(5), 1460–1466.
- Khan, B., Adeleye, A. S., Burgess, R. M., Smolowitz, R., Russo, S. M., & Ho, K. T. (2019). A 72-h exposure study with eastern oysters (*Crassostrea virginica*) and the nanomaterial graphene oxide. *Environmental Toxicology and Chemistry*, 38(4), 820–830. <https://doi.org/10.1002/etc.4367>
- Koagouw, W., & Ciocan, C. (2019). Effects of short-term exposure of paracetamol in the gonads of blue mussels (*Mytilus edulis*). *Environmental Science and Pollution Research*, 27(25), 30933–30944. <https://doi.org/10.1007/s11356-019-06861-w>
- Kolandhasamy, P., Su, L., Li, J., Qu, X., Jabeen, K., & Shi, H. (2018). Adherence of microplastics to soft tissue of mussels: A novel way to uptake microplastics beyond ingestion. *Science of the Total Environment*, 610–611, 635–640. <https://doi.org/10.1016/j.scitotenv.2017.08.053>
- Kühn, S., Oyen, A. V., Booth, A. M., Meijboom, A., & Franeker, J. A. V. (2018). Marine microplastic: Preparation of relevant test materials for laboratory assessment of ecosystem impacts. *Chemosphere*, 213, 103–113. <https://doi.org/10.1016/j.chemosphere.2018.09.032>
- Lebreton, L. C. M., Van Der Zwet, J., Damsteeg, J. W., Slat, B., Andrady, A., & Reisser, J. (2017). River plastic emissions to the world's oceans. *Nature Communications*, 8, 1–10. <https://doi.org/10.1038/ncomms15611>
- Lee, K. W., Shim, W. J., Kwon, O. Y., & Kang, J. H. (2013). Size-dependent effects of micro polystyrene particles in the marine copepod *Tigriopus japonicus*. *Environmental Science and Technology*, 47(19), 11278–11283. <https://doi.org/10.1021/es401932b>
- Li, J., Lusher, A. L., Rotchell, J. M., Deudero, S., Turra, A., Bråte, I. L. N., Sun, C., Hossain, M. S., Li, Q., Kolandhasamy, P., & Shi, H. (2019). Using mussel as a global bioindicator of coastal microplastic pollution. *Environmental Pollution*, 244, 522–533. <https://doi.org/10.1016/j.envpol.2018.10.032>
- Luo, H., Li, Y., Zhao, Y., Xiang, Y., He, D., & Pan, X. (2019). Effects of accelerated aging on characteristics, leaching, and toxicity of commercial lead chromate pigmented microplastics. *Environmental Pollution*, 257, 1–42. <https://doi.org/10.1016/j.envpol.2019.113475>
- Ma, P., Wang, M. W., Liu, H., Chen, Y. F., & Xia, J. (2019). Research on ecotoxicology of microplastics on freshwater aquatic organisms. *Environmental Pollutants and Bioavailability*, 31(1), 131–137. <https://doi.org/10.1080/26395940.2019.1580151>
- Murano, C., Agnisola, C., Caramiello, D., Castellano, I., Casotti, R., Corsi, I., & Palumbo, A. (2020). How sea urchins face microplastics: Uptake, tissue distribution and immune system response. *Environmental Pollution*, 264, 1–10. <https://doi.org/10.1016/j.envpol.2020.114685>

- Neves, R. A. F., Santiago, T. C., Carvalho, W. F., Silva, E. S., da Silva, P. M., & Nascimento, S. M. (2019). Impacts of the toxic benthic dinoflagellate *Prorocentrum lima* on the brown mussel (*Perna perna*): Shell-valve closure response, immunology, and histopathology. *Marine Environmental Research*, 146, 35–45. <https://doi.org/10.1016/j.marenvres.2019.03.006>
- Paul-Pont, I., Lacroix, C., González Fernández, C., Hégaret, H., Lambert, C., Le Goïc, N., Frère, L., Cassone, A. L., Sussarellu, R., Fabioux, C., Guyomarch, J., Albertosa, M., Huvet, A., & Soudant, P. (2016). Exposure of marine mussels *Mytilus spp.* to polystyrene microplastics: Toxicity and influence on fluoranthene bioaccumulation. *Environmental Pollution*, 216, 724–737. <https://doi.org/10.1016/j.envpol.2016.06.039>
- Pedersen, A. F., Gopalakrishnan, K., Boegehold, A. G., Peraino, N. J., Westrick, J. A., & Kashian, D. R. (2020). Microplastic ingestion by quagga mussels (*Dreissena bugensis*) and its effects on physiological processes. *Environmental Pollution*, 260, 1–8. <https://doi.org/10.1016/j.envpol.2020.113964>
- Peixoto, D., Pinheiro, C., Amorim, J., Oliva-Teles, L., Guilhermino, L., & Vieira, M. N. (2019). Microplastic pollution in commercial salt for human consumption: A review. *Estuarine, Coastal and Shelf Science*, 219, 161–168. <https://doi.org/10.1016/j.ecss.2019.02.018>
- Pittura, L., Avio, C. G., Giuliani, M. E., D'Errico, G., Keiter, S. H., Cormier, B., Gorb, S., & Regoli, F. (2018). Microplastics as vehicles of environmental PAHs to marine organisms: Combined chemical and physical hazards to the Mediterranean mussels, (*Mytilus galloprovincialis*). *Frontiers in Marine Science*, 5(103), 1–17. <https://doi.org/10.3389/fmars.2018.00103>
- Plastics Europe. (2020). Plastics-the Facts 2020. An analysis of European plastics production, demand and waste data. <https://www.plasticseurope.org>.
- Pribadi, T. D. K., Syahidah, D., Harjanti, S. D., & Malini, D. M. (2017). Alteration of gills and liver histological structure of *Cyprinus carpio* exposed to leachate. *Biosaintifika: Journal of Biology & Biology Education*, 9(2), 289–297. <https://doi.org/10.15294/biosaintifika.v9i2.8680>
- Prokic, M. D., Radovanovic, T. B., Gavric, J. P., & Faggio, C. (2019). Ecotoxicological effects of microplastics: Examination of biomarkers, current state and future perspectives. *Trends in Analytical Chemistry*, 111, 37–46. <https://doi.org/10.1016/j.trac.2018.12.001>
- Revel, M., Yakovenko, N., Caley, T., Guillet, C., Châtel, A., & Mouneyrac, C. (2018). Accumulation and immunotoxicity of microplastics in the estuarine worm *Hediste diversicolor* in environmentally relevant conditions of exposure. *Environmental Science and Pollution Research*, 27, 3574–3583. <https://doi.org/10.1007/s11356-018-3497-6>
- Rist, S. E., Assidqi, K., Zamani, N. P., Appel, D., Perschke, M., Huhn, M., & Lenz, M. (2016). Suspended micro-sized PVC particles impair the performance and decrease survival in the Asian green mussel *Perna viridis*. *Marine Pollution Bulletin*, 111(1–2), 213–220. <https://doi.org/10.1016/j.marpolbul.2016.07.006>
- Rocha, T. L., Saboia-Morais, S. M. T., & Bebianno, M. J. (2016). Histopathological assessment and inflammatory response in the digestive gland of marine mussel *Mytilus galloprovincialis* exposed to cadmium-based quantum dots. *Aquatic Toxicology*, 177, 306–315. <https://doi.org/10.1016/j.aquatox.2016.06.003>
- Rochman, C. M., Tahir, A., Williams, S. L., Baxa, D. V., Lam, R., Miller, J. T., Teh, F. C., Werorilangi, S., & Teh, S. J. (2015). Anthropogenic debris in seafood: Plastic debris and fibers from textiles in fish and bivalves sold for human consumption. *Scientific Reports*, 5, 1–10. <https://doi.org/10.1038/srep14340>
- Santana, M. F. M., Moreira, F. T., & Turra, A. (2017). Trophic transference of microplastics under a low exposure scenario: Insights on the likelihood of particle cascading along marine food-webs. *Marine Pollution Bulletin*, 121(1–2), 154–159. <https://doi.org/10.1016/j.marpolbul.2017.05.061>
- Scott, N., Porter, A., Santillo, D., Simpson, H., Lloyd-Williams, S., & Lewis, C. (2019). Particle characteristics of microplastics contaminating the mussel *Mytilus edulis* and their surrounding environments. *Marine Pollution Bulletin*, 146, 125–133. <https://doi.org/10.1016/j.marpolbul.2019.05.041>
- Sheir, S. K., Handy, R. D., & Henry, T. B. (2013). Effect of pollution history on immunological responses and organ histology in the marine mussel *Mytilus edulis* exposed to cadmium. *Archives of Environmental Contamination and Toxicology*, 64(4), 701–716. <https://doi.org/10.1007/s00244-012-9868-y>
- Sýkdokur, E., Belivermiş, M., Sezer, N., Pekmez, M., Bulan, Ö. K., & Kılıç, Ö. (2020). Effects of microplastics and mercury on manila clam (*Ruditapes philippinarum*): Feeding rate, immunomodulation, histopathology and oxidative stress. *Environmental Pollution*, 262, 1–12. <https://doi.org/10.1016/j.envpol.2020.114247>
- Sun, Q., Ren, S. Y., & Ni, H. G. (2020). Incidence of microplastics in personal care products: An appreciable part of plastic pollution. *Science of the Total Environment*, 742, 1–40. <https://doi.org/10.1016/j.scitotenv.2020.140218>
- Sussarellu, R., Suquet, M., Thomas, Y., Lambert, C., Fabioux, C., Pernet, M. E., Goic, N. L., Quillien, V., Mingant, C., Epelboin, Y., Corporeau, C., Guyomarch, J., Robbins, J., Paul-Pont, I., Soudant, P., & Huvet, A. (2016). Oyster reproduction is affected by exposure to polystyrene microplastics. *PNAS*, 113(9), 2430–2435. <https://doi.org/10.1073/pnas.1519019113>
- Vasanthi, R. L., Arulvasu, C., Kumar, P., & Srinivasan, P. (2021). Ingestion of microplastics and its potential for causing structural alterations and oxidative stress in Indian green mussel (*Perna viridis*)— A multiple biomarker approach. *Chemosphere*, 283, 1–10. <https://doi.org/10.1016/j.chemosphere.2021.130979>
- Vaschenko, M. A., Hsieh, H. L., & Radashevsky, V. I. (2013). Gonadal state of the oyster *Crassostrea angulata* cultivated in Taiwan. *Journal of Shellfish Research*, 32(2), 471–482. <https://doi.org/10.2983/035.032.0227>
- Webb, S., Gaw, S., Marsden, I. D., & Merae, N. K. (2020). Biomarker responses in New Zealand green-lipped mussels (*Perna canaliculus*) exposed to microplastics and triclosan. *Ecotoxicology and Environmental Safety*, 201, 1–9. <https://doi.org/10.1016/j.ecoenv.2020.110871>
- Wei, Q., Hu, C. Y., Zhang, R. R., Gu, Y. Y., Sun, A. L., Zhang, Z. M., Shi, X. Z., Chen, J., & Wang, T. Z. (2021). Comparative evaluation of high-density polyethylene and polystyrene

- microplastics pollutants: Uptake, elimination and effects in mussel. *Marine Environmental Research*, 169, 1–10. <https://doi.org/10.1016/j.marenvres.2021.105329>
- Woods, M. N., Stack, M. E., Fields, D. M., Shaw, S. D., & Matrai, P. A. (2018). Microplastic fiber uptake, ingestion, and egestion rates in the blue mussel (*Mytilus edulis*). *Marine Pollution Bulletin*, 137, 638–645. <https://doi.org/10.1016/j.marpolbul.2018.10.061>
- Wright, S. L., Thompson, R. C., & Galloway, T. S. (2013). The physical impacts of microplastics on marine organisms: A review. *Environmental Pollution*, 178, 483–492. <https://doi.org/10.1016/j.envpol.2013.02.031>
- Xu, X. Y., Lee, W. T., Chan, A. K. Y., Lo, H. S., Shin, P. K. S., & Cheung, S. G. (2016). Microplastic ingestion reduces energy intake in the clam *Acteocina striata*. *Marine Pollution Bulletin*, 124(2), 798–802. <https://doi.org/10.1016/j.marpolbul.2016.12.027>
- Yaqin, K., Rahim, N. F., Fachruddin, L., & Tambaru, R. (2019). Preliminary study of quick assessment of Spirulina density using turbiditymeter for ecotoxicological studies in 4.0 industrial revolution era. *Jurnal Pengelolaan Perairan*, 2(1), 11–19.
- Yee-Duarte, J. A., Ceballos-Vázquez, B. P., Arellano-Martínez, M., Camacho-Mondragón, M. A., & Uría-Galicia, E. (2018). Histopathological alterations in the gonad of *Megapitaria squalida* (Mollusca: Bivalvia) inhabiting a heavy metals polluted environment. *Journal of Aquatic Animal Health*, 30(2), 144–154. <https://doi.org/10.1002/aah.10015>
- Zhang, X., Yan, B., & Wang, X. (2020). Selection and optimization of a protocol for extraction of microplastics from *Macraa veneriformis*. *Science of the Total Environment*, 746, 1–11. <https://doi.org/10.1016/j.scitotenv.2020.141250>
- Zhu, X., Qiang, L., Shi, H., & Cheng, J. (2020). Bioaccumulation of microplastics and its *in vivo* interactions with trace metals in edible oysters. *Marine Pollution Bulletin*, 154, 1–8. <https://doi.org/10.1016/j.marpolbul.2020.111079>
- Zupan, I., & Kalafatic, M. (2003). Histological effects of low atrazine concentration on Zebra Mussel (*Dreissena polymorpha* Pallas). *Environmental Contamination and Toxicology*, 70, 688–695. <https://doi.org/10.1007/s00128-003-0039-8>

ORIGINALITY REPORT

98%

SIMILARITY INDEX

16%

INTERNET SOURCES

98%

PUBLICATIONS

3%

STUDENT PAPERS

PRIMARY SOURCES

1	Nur Fadhilah Rahim, Khusnul Yaqin. "Histological Alteration of Green Mussel Perna viridis Organs Exposed to Microplastics", Squalen Bulletin of Marine and Fisheries Postharvest and Biotechnology, 2022 Publication	92%
2	www.bbp4b.litbang.kkp.go.id Internet Source	4%
3	Submitted to Universitas Sebelas Maret Student Paper	1%
4	Submitted to University of Southern Queensland Student Paper	<1%

Exclude quotes On

Exclude matches Off

Exclude bibliography On



Sp. This word is misspelled. Use a dictionary or spellchecker when you proofread your work.



Sp. This word is misspelled. Use a dictionary or spellchecker when you proofread your work.



Sp. This word is misspelled. Use a dictionary or spellchecker when you proofread your work.



Sp. This word is misspelled. Use a dictionary or spellchecker when you proofread your work.



Sp. This word is misspelled. Use a dictionary or spellchecker when you proofread your work.



Sp. This word is misspelled. Use a dictionary or spellchecker when you proofread your work.



Sp. This word is misspelled. Use a dictionary or spellchecker when you proofread your work.



Sp. This word is misspelled. Use a dictionary or spellchecker when you proofread your work.



Sp. This word is misspelled. Use a dictionary or spellchecker when you proofread your work.



Sp. This word is misspelled. Use a dictionary or spellchecker when you proofread your work.



Sp. This word is misspelled. Use a dictionary or spellchecker when you proofread your work.



Sp. This word is misspelled. Use a dictionary or spellchecker when you proofread your work.



Proofread This part of the sentence contains a grammatical error or misspelled word that makes your meaning unclear.



Sp. This word is misspelled. Use a dictionary or spellchecker when you proofread your work.



Sp. This word is misspelled. Use a dictionary or spellchecker when you proofread your work.



Sp. This word is misspelled. Use a dictionary or spellchecker when you proofread your work.



Sp. This word is misspelled. Use a dictionary or spellchecker when you proofread your work.



Sp. This word is misspelled. Use a dictionary or spellchecker when you proofread your work.



Sp. This word is misspelled. Use a dictionary or spellchecker when you proofread your work.



Sp. This word is misspelled. Use a dictionary or spellchecker when you proofread your work.



Sp. This word is misspelled. Use a dictionary or spellchecker when you proofread your work.



Sp. This word is misspelled. Use a dictionary or spellchecker when you proofread your work.



Sp. This word is misspelled. Use a dictionary or spellchecker when you proofread your work.



Sp. This word is misspelled. Use a dictionary or spellchecker when you proofread your work.



Sp. This word is misspelled. Use a dictionary or spellchecker when you proofread your work.



Sp. This word is misspelled. Use a dictionary or spellchecker when you proofread your work.



Sp. This word is misspelled. Use a dictionary or spellchecker when you proofread your work.



Sp. This word is misspelled. Use a dictionary or spellchecker when you proofread your work.



Sp. This word is misspelled. Use a dictionary or spellchecker when you proofread your work.



Missing ", " You have a spelling or typing mistake that makes the sentence appear to have a comma error.



Sp. This word is misspelled. Use a dictionary or spellchecker when you proofread your work.



Sp. This word is misspelled. Use a dictionary or spellchecker when you proofread your work.



Sp. This word is misspelled. Use a dictionary or spellchecker when you proofread your work.



Sp. This word is misspelled. Use a dictionary or spellchecker when you proofread your work.



Sp. This word is misspelled. Use a dictionary or spellchecker when you proofread your work.



Sp. This word is misspelled. Use a dictionary or spellchecker when you proofread your work.



Sp. This word is misspelled. Use a dictionary or spellchecker when you proofread your work.



Sp. This word is misspelled. Use a dictionary or spellchecker when you proofread your work.



Sp. This word is misspelled. Use a dictionary or spellchecker when you proofread your work.



Sp. This word is misspelled. Use a dictionary or spellchecker when you proofread your work.



Sp. This word is misspelled. Use a dictionary or spellchecker when you proofread your work.



Sp. This word is misspelled. Use a dictionary or spellchecker when you proofread your work.



Article Error You may need to use an article before this word.



Sp. This word is misspelled. Use a dictionary or spellchecker when you proofread your work.



Sp. This word is misspelled. Use a dictionary or spellchecker when you proofread your work.



Sp. This word is misspelled. Use a dictionary or spellchecker when you proofread your work.



Sp. This word is misspelled. Use a dictionary or spellchecker when you proofread your work.



Sp. This word is misspelled. Use a dictionary or spellchecker when you proofread your work.



Prep. You may be using the wrong preposition.



Sp. This word is misspelled. Use a dictionary or spellchecker when you proofread your work.



Sp. This word is misspelled. Use a dictionary or spellchecker when you proofread your work.



Sp. This word is misspelled. Use a dictionary or spellchecker when you proofread your work.



Sp. This word is misspelled. Use a dictionary or spellchecker when you proofread your work.



Sp. This word is misspelled. Use a dictionary or spellchecker when you proofread your work.



Sp. This word is misspelled. Use a dictionary or spellchecker when you proofread your work.



Sp. This word is misspelled. Use a dictionary or spellchecker when you proofread your work.



Sp. This word is misspelled. Use a dictionary or spellchecker when you proofread your work.



Sp. This word is misspelled. Use a dictionary or spellchecker when you proofread your work.



Sp. This word is misspelled. Use a dictionary or spellchecker when you proofread your work.



Sp. This word is misspelled. Use a dictionary or spellchecker when you proofread your work.



Sp. This word is misspelled. Use a dictionary or spellchecker when you proofread your work.



Sp. This word is misspelled. Use a dictionary or spellchecker when you proofread your work.



Sp. This word is misspelled. Use a dictionary or spellchecker when you proofread your work.

PAGE 3



Article Error You may need to remove this article.



Sp. This word is misspelled. Use a dictionary or spellchecker when you proofread your work.



P/V You have used the passive voice in this sentence. Depending upon what you wish to emphasize in the sentence, you may want to revise it using the active voice.



Article Error You may need to use an article before this word.



P/V You have used the passive voice in this sentence. Depending upon what you wish to emphasize in the sentence, you may want to revise it using the active voice.



Article Error You may need to remove this article.



Sp. This word is misspelled. Use a dictionary or spellchecker when you proofread your work.



Sp. This word is misspelled. Use a dictionary or spellchecker when you proofread your work.



Article Error You may need to use an article before this word.



Missing ", " You may need to place a comma after this word.



Sp. This word is misspelled. Use a dictionary or spellchecker when you proofread your work.



Missing ", " You may need to place a comma after this word.



Sp. This word is misspelled. Use a dictionary or spellchecker when you proofread your work.



Sp. This word is misspelled. Use a dictionary or spellchecker when you proofread your work.



Sp. This word is misspelled. Use a dictionary or spellchecker when you proofread your work.



Sp. This word is misspelled. Use a dictionary or spellchecker when you proofread your work.



P/V You have used the passive voice in this sentence. Depending upon what you wish to emphasize in the sentence, you may want to revise it using the active voice.



Sp. This word is misspelled. Use a dictionary or spellchecker when you proofread your work.



Sp. This word is misspelled. Use a dictionary or spellchecker when you proofread your work.



Sp. This word is misspelled. Use a dictionary or spellchecker when you proofread your work.



Sp. This word is misspelled. Use a dictionary or spellchecker when you proofread your work.



Article Error You may need to use an article before this word.



Sp. This word is misspelled. Use a dictionary or spellchecker when you proofread your work.



Proofread This part of the sentence contains a grammatical error or misspelled word that makes your meaning unclear.



P/V You have used the passive voice in this sentence. Depending upon what you wish to emphasize in the sentence, you may want to revise it using the active voice.



Sp. This word is misspelled. Use a dictionary or spellchecker when you proofread your work.



Sp. This word is misspelled. Use a dictionary or spellchecker when you proofread your work.



Sp. This word is misspelled. Use a dictionary or spellchecker when you proofread your work.



Sp. This word is misspelled. Use a dictionary or spellchecker when you proofread your work.



Article Error You may need to use an article before this word.



Sp. This word is misspelled. Use a dictionary or spellchecker when you proofread your work.



Proofread This part of the sentence contains a grammatical error or misspelled word that makes your meaning unclear.



Sp. This word is misspelled. Use a dictionary or spellchecker when you proofread your work.



Sp. This word is misspelled. Use a dictionary or spellchecker when you proofread your work.



Article Error You may need to remove this article.



P/V You have used the passive voice in this sentence. Depending upon what you wish to emphasize in the sentence, you may want to revise it using the active voice.



Sp. This word is misspelled. Use a dictionary or spellchecker when you proofread your work.



Sp. This word is misspelled. Use a dictionary or spellchecker when you proofread your work.



Sp. This word is misspelled. Use a dictionary or spellchecker when you proofread your work.



Sp. This word is misspelled. Use a dictionary or spellchecker when you proofread your work.



Sp. This word is misspelled. Use a dictionary or spellchecker when you proofread your work.



Sp. This word is misspelled. Use a dictionary or spellchecker when you proofread your work.



Article Error You may need to use an article before this word.



Sp. This word is misspelled. Use a dictionary or spellchecker when you proofread your work.



Possessive You may need to use an apostrophe to show possession.



Sp. This word is misspelled. Use a dictionary or spellchecker when you proofread your work.



Sp. This word is misspelled. Use a dictionary or spellchecker when you proofread your work.



P/V You have used the passive voice in this sentence. Depending upon what you wish to emphasize in the sentence, you may want to revise it using the active voice.



Article Error You may need to remove this article.



Sp. This word is misspelled. Use a dictionary or spellchecker when you proofread your work.



Sp. This word is misspelled. Use a dictionary or spellchecker when you proofread your work.



Sp. This word is misspelled. Use a dictionary or spellchecker when you proofread your work.



Proofread This part of the sentence contains a grammatical error or misspelled word that makes your meaning unclear.



P/V You have used the passive voice in this sentence. Depending upon what you wish to emphasize in the sentence, you may want to revise it using the active voice.



Sp. This word is misspelled. Use a dictionary or spellchecker when you proofread your work.



Sp. This word is misspelled. Use a dictionary or spellchecker when you proofread your work.



Sp. This word is misspelled. Use a dictionary or spellchecker when you proofread your work.



P/V You have used the passive voice in this sentence. Depending upon what you wish to emphasize in the sentence, you may want to revise it using the active voice.



Sp. This word is misspelled. Use a dictionary or spellchecker when you proofread your work.



P/V You have used the passive voice in this sentence. Depending upon what you wish to emphasize in the sentence, you may want to revise it using the active voice.



Sp. This word is misspelled. Use a dictionary or spellchecker when you proofread your work.



Sp. This word is misspelled. Use a dictionary or spellchecker when you proofread your work.



Sp. This word is misspelled. Use a dictionary or spellchecker when you proofread your work.



Sp. This word is misspelled. Use a dictionary or spellchecker when you proofread your work.



Sp. This word is misspelled. Use a dictionary or spellchecker when you proofread your work.



Sp. This word is misspelled. Use a dictionary or spellchecker when you proofread your work.



Confused You have used **of** in this sentence. You may need to use **off** instead.



Sp. This word is misspelled. Use a dictionary or spellchecker when you proofread your work.



Sp. This word is misspelled. Use a dictionary or spellchecker when you proofread your work.



Sp. This word is misspelled. Use a dictionary or spellchecker when you proofread your work.



Sp. This word is misspelled. Use a dictionary or spellchecker when you proofread your work.



Sp. This word is misspelled. Use a dictionary or spellchecker when you proofread your work.



Sp. This word is misspelled. Use a dictionary or spellchecker when you proofread your work.



P/V You have used the passive voice in this sentence. Depending upon what you wish to emphasize in the sentence, you may want to revise it using the active voice.



Sp. This word is misspelled. Use a dictionary or spellchecker when you proofread your work.



Sp. This word is misspelled. Use a dictionary or spellchecker when you proofread your work.



Sp. This word is misspelled. Use a dictionary or spellchecker when you proofread your work.



Sp. This word is misspelled. Use a dictionary or spellchecker when you proofread your work.



Proofread This part of the sentence contains a grammatical error or misspelled word that makes your meaning unclear.



Article Error You may need to remove this article.



Sp. This word is misspelled. Use a dictionary or spellchecker when you proofread your work.



Sp. This word is misspelled. Use a dictionary or spellchecker when you proofread your work.



Sp. This word is misspelled. Use a dictionary or spellchecker when you proofread your work.



Possessive You may need to use an apostrophe to show possession.



Wrong Article You may have used the wrong article or pronoun. Proofread the sentence to make sure that the article or pronoun agrees with the word it describes.



Sp. This word is misspelled. Use a dictionary or spellchecker when you proofread your work.



Article Error You may need to use an article before this word.



Proofread This part of the sentence contains a grammatical error or misspelled word that makes your meaning unclear.



Sp. This word is misspelled. Use a dictionary or spellchecker when you proofread your work.



Sp. This word is misspelled. Use a dictionary or spellchecker when you proofread your work.



Wrong Article You may have used the wrong article or pronoun. Proofread the sentence to make sure that the article or pronoun agrees with the word it describes.



Sp. This word is misspelled. Use a dictionary or spellchecker when you proofread your work.



Sp. This word is misspelled. Use a dictionary or spellchecker when you proofread your work.



Sp. This word is misspelled. Use a dictionary or spellchecker when you proofread your work.



Wrong Article You may have used the wrong article or pronoun. Proofread the sentence to make sure that the article or pronoun agrees with the word it describes.



Sp. This word is misspelled. Use a dictionary or spellchecker when you proofread your work.



Article Error You may need to use an article before this word.



Sp. This word is misspelled. Use a dictionary or spellchecker when you proofread your work.



Wrong Form You may have used the wrong form of this word.



Sp. This word is misspelled. Use a dictionary or spellchecker when you proofread your work.



Sp. This word is misspelled. Use a dictionary or spellchecker when you proofread your work.



Sp. This word is misspelled. Use a dictionary or spellchecker when you proofread your work.



Article Error You may need to use an article before this word.



Sp. This word is misspelled. Use a dictionary or spellchecker when you proofread your work.



Sp. This word is misspelled. Use a dictionary or spellchecker when you proofread your work.



Sp. This word is misspelled. Use a dictionary or spellchecker when you proofread your work.



Sp. This word is misspelled. Use a dictionary or spellchecker when you proofread your work.

PAGE 7



Sp. This word is misspelled. Use a dictionary or spellchecker when you proofread your work.



Sp. This word is misspelled. Use a dictionary or spellchecker when you proofread your work.

PAGE 8

PAGE 9

PAGE 10
