

# Histopathology of Liver and Kidney of the River Catfish (*Mystus nemurus*) as a Bioindicator of Satui River Water Quality, South Kalimantan, Indonesia

*by* H.B. Santoso

---

**Submission date:** 05-Jun-2024 07:44AM (UTC+0700)

**Submission ID:** 2395448949

**File name:** of\_Liver\_and\_Kidney\_of\_the\_River\_Catfish\_Mystus\_nemurus\_as\_a.pdf (1.65M)

**Word count:** 9174

**Character count:** 50119



## Histopathology of Liver and Kidney of the River Catfish (*Mystus nemurus*) as a Bioindicator of Satui River Water Quality, South Kalimantan, Indonesia

9  
Dinda Triana<sup>1</sup>, Heri Budi Santoso<sup>1\*</sup> and Anang Kadarsah<sup>1</sup>  
Department of Biology, Faculty of Mathematics and Natural Sciences, Lambung Mangkurat University,  
Banjarbaru, South Kalimantan, Indonesia

\*Corresponding Author: [heribudisantoso@ulm.ac.id](mailto:heribudisantoso@ulm.ac.id)

### 28 ARTICLE INFO

#### Article History:

Received: July 31, 2023

Accepted: Aug. 29, 2023

Online: Oct. 30, 2023

#### Keywords:

Histopathology,  
Water quality,  
River catfish,  
Pollution index,  
Biomonitoring,  
Satui River

### ABSTRACT

Due to their ability to accumulate pollutants, fish are commonly used as bioindicators in river ecosystems. Their direct contact with dissolved substances has given the chance for the livers and kidneys of fish to be affected by chemical changes in aquatic environments. Thus, concerns have emerged regarding the potential degradation of water quality in the Satui River due to human activities, where *Mystus nemurus* is commonly found. In response, this study aimed to evaluate the histopathological alterations in the liver and kidney of the river catfish, as well as assessing the water quality of the Satui River. Histopathological lesions are detected through fin-based microtechniques. While pollution index methodology is employed to evaluate river water quality according to the Water Quality Standards as specified in Government Regulation No. 22 of 2021 of the Republic of Indonesia. The present study utilized a scoring-based qualitative descriptive histopathological analysis to investigate the histological characteristics of the liver and kidneys. The Satui River's water quality was classified as "lightly polluted" based on the average pollution index values of 1.11 and 2.31 for the first and second samplings, respectively. Fat degeneration, congestion and necrosis were monitored as the characteristic features of liver histopathological damage in river catfish. Simultaneously, the histopathological analysis discloses the existence of melanomacrophage center (MMC), congestion and glomerular swelling as observable manifestations of kidney damage. Based on the obtained scoring results, a score of 1 was recorded, which indicates the occurrence of relatively minor damage, encompassing a range of 25-50%. Between stations 1 & 2, no significant difference ( $P > 0.05$ ) was observed in the histological damage for the liver and kidneys of river catfish. To conclude, the utilization of histopathological assessment for river catfish offers significant benefits since it allows accurate evaluation of the health of both fish and water at any given time.

### INTRODUCTION

Environmentalists express significant concern regarding the pervasive freshwater source contamination caused by various pollutants. Fish undergo stress due to diverse abiotic environmental factors, such as changes in water temperature, pH levels, oxygen concentration in addition to water contaminants including pesticides and heavy metals. Furthermore, biotic stressors can be observed in fishing activities associated with human intervention, parasitic and bacterial infestations, and the influence of predators. Toxic substances in the aquatic environment can also alter the water quality parameters, affecting the fish's histology indices (El-shenawy *et al.*, 2021). Histopathology is a valuable tool for assessing the potential

impact of water quality degradation on human health. The histology approach can facilitate identifying histopathological changes induced by exposure to anthropogenic pollutants, potentially adversely impacting fish health (Feist *et al.*, 2015). The Satui River is in the Tanah Bumbu district of the South Kalimantan province. It flows through the Satui sub-district. The river in question, with a length of 58,596.66 meters, is a vital link between multiple communities within the Satui sub-district. Water pollution in the Satui River is believed to result from various human activities, such as agricultural practices, mining operations, domestic tasks, the passage of large vessels and the transportation of fishing boats. According to Yulistia (2020), escalating water usage can lead to unregulated waste production, negatively impacting water quality.

The quality of the aquatic environment influences the maintenance of physiological functions in fish. The consumption of fish inhabiting polluted waters can potentially jeopardize human health and pose significant risks to individuals (Dwiyitno *et al.*, 2008). Hence, it is imperative to assess water quality by evaluating physical and chemical characteristics, followed by analysis using the pollution index method. The pollution index value quantifies the pollution level of the required water quality standard in river water sources (Marganingrum *et al.*, 2013). Due to their capacity to highlight the risks of introducing dangerous compounds into aquatic habitats, fish are frequently used as important control organisms in toxicological investigations (Goenarso, 1988; Safratilofa, 2017; Ibrahim & Elbastamy, 2023). Fish serve as effective bioindicators due to their easily identifiable taxonomy, extensive geographical range, substantial population sizes and quantifiability. Additionally, their amenability to laboratory examination, heightened sensitivity or resistance to environmental pressures, and capacity to tolerate adverse conditions further enhance their suitability (Purwati, 2015). The presence of river catfish in the Satui River is notable due to their wide distribution and high population levels, making them a relevant example of this characteristic.

The species *Mystus nemurus* is a type of river catfish that belong to the taxonomic classification of phylum Chordata, class Pisces, subclass Siluridae, family Bagridae and genus *Mystus* (Imaki *et al.*, 1978; Kottelat *et al.*, 1993). The river catfish, also called *Baung fish* by locals, is an indigenous species in Indonesia. This species holds considerable economic importance in South Kalimantan due to its highly palatable flavor and the lucrative market value it commands (Komari *et al.*, 2012). River catfish individuals exhibit a nocturnal behavior pattern and prefer temperatures ranging from 20 to 33°C (Izquierdo *et al.*, 2001). Biologically, river catfish grows and develops in tropical waters; this fish species has additional respiratory organs in the form of arborescent organs. In response to environmental conditions, river catfish exhibit a behavioral adaptation wherein they ascend to the water's surface when oxygen levels are depleted, enabling them to extract oxygen directly from the atmosphere (Nuraeni *et al.*, 2022).

Given the increased anthropogenic activity in the Satui River, particularly in East Satui Village, and the lack of data on the health quality of the Satui River waters up until this point, it is essential to biomonitor water quality using a histopathological evaluation approach on river catfish, which is widely consumed by the general public. Histopathological evaluation in river catfish is highly advantageous due to its ability to assess fish health at any given moment accurately. Due to the negative effects of pollution, changes in fish's liver and kidney tissue can effectively provide information on the physiological status and health of fish, making them ideal candidates for biomonitoring programs.

The study aimed to assess histopathological abnormalities in the liver and kidneys of river catfish and test the physical and chemical quality of the water in the Satui River using the pollution index method.

31

## MATERIALS AND METHODS

### Study area

The Satui River is in the Satui sub-district, part of the Tanah Bumbu district in the South Kalimantan Province of Indonesia. The Satui River, with a length of 58,596.66 meters, originates from the Batulaki River and flows downstream along the West Satui coast. Station 1, situated at coordinates 3°46'47.3"S 115°26'13.4"E, represents the shipping dock area, while station 2, located at coordinates 3°46'43.7"S 115°25'15.9"E, corresponds to the residential area (Fig. 1). Additionally, Fig. (2) illustrates anthropogenic activities associated with the Satui River.

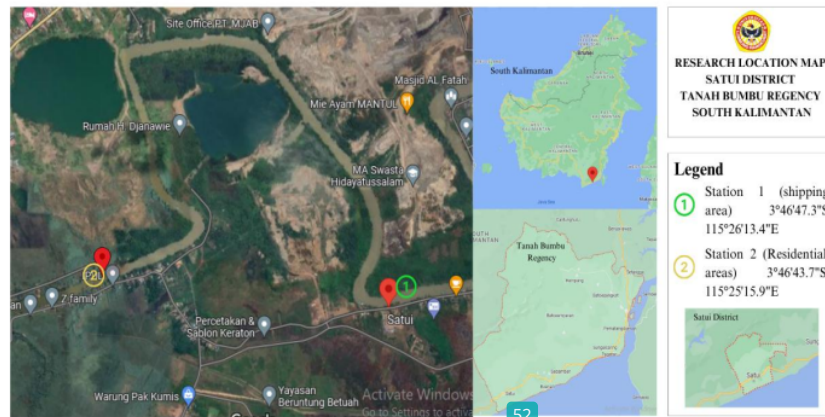

Fig. 1. Map of sampling location



Fig. 2. Satui River utilization showing: (A) Shipping dock; (B) Household liquid waste disposal; (C) Agricultural irrigation; (D) Diesel warehouse; (e) Fishing, and (F) Household plastic waste.

### Samples collection

The method employed for fish and water sampling is "purposive sampling," which involves selecting samples based on specific research requirements. According to Sugiyono (2014), purposive sampling is a method used to select data sources based on specific criteria.

The focus of this study revolved around the anthropogenic activities that serve as sources of pollution. The study sampled two distinct stations: Station 1, characterized by a high concentration of large ships, and Station 2, which represents a residential area.

The collection of water and fish samples was conducted on two occasions, specifically in February and April 2023. The sampling methodology for river water followed the guidelines outlined in the Indonesian National Standard (SNI) 8995:2021\*\*\*. Fish specimens were procured through fishing techniques or the deployment of traps with the aid of proficient fishermen. Six river catfish were collected from each sampling station, with a length range of 20- 23cm and a weight range of 200- 500g. The fish specimens were carefully transferred into water containers and subsequently transported to the laboratory to facilitate the extraction of their liver and kidney tissues.

#### Physical and chemical examination

The variables for measuring physical water quality included temperature, total suspended solids (TSS) and salinity. The chemical quality measurement included pH, biochemical oxygen demand (BOD) and dissolved oxygen (DO). The measurement procedure pertains to the Indonesian Standardisation Agency (SNI), as indicated in Table (1).

**Table 1.** Physical and chemical parameters and the corresponding methods of analysis

No	Parameter	Unit	Method Specification
<b>Field</b>			
1.	Temperature	°C	Thermometer
2.	pH	-	pH indicator
<b>Laboratory</b>			
3.	BOD	mg/L	SNI 6989.72:2009
4.	TSS	mg/L	SNI 06-6989.3:2019
5.	COD	mg/L	SNI 6989.2:2019
6.	DO	mg/L	digital DO meter

#### Histopathological examination

This study utilized the liver and kidneys of the river catfish (*Mystus nemurus*) for histological preparations. The initial stage of the preparation process involves the extraction of the liver and kidneys. Subsequently, the liver and kidneys of the catfish were subjected to fixation in a 10% buffered neutral formalin solution (BNF), followed by a series of dehydration steps using alcohol concentrations of 70%, 80%, 90% and absolute alcohol. Furthermore, xylol was employed for two cycles, followed by two cycles of infiltration lasting 1.5 hours each. The specimen was then embedded in a paraffin block in preparation for sectioning. The tissue bands were sectioned using a microtome set to a thickness of 5 microns. Next, the hematoxylin- eosin staining technique was employed to introduce chromaticity. According to Abdel-Moneim et al. (2012), paraffin microtechniques employing split preparations are utilized to identify histopathological lesions. Histopathological examination of liver and kidney tissues was conducted using an Olympus CX 41 light microscope and an Olympus DP 20 camera. The examination commenced by employing a 4x objective lens to acquire a comprehensive tissue perspective, followed by objective lenses with higher magnification power, specifically 10x, 20x, 40x, and 100x, to discern and identify any lesions present.

#### Data analysis

The water quality measurements were compared to the water quality standards outlined in the Government Regulation of the Republic of Indonesia Number 22 of 2021, which

pertains to the Implementation of Environmental Protection and Management regarding the Allocation of River Water Quality Standards. Moreover, the analysis was conducted utilizing the pollution index (PI) methodology stipulated in Decree No. 115 of 2003 issued by the State Minister of Environment of the Republic of Indonesia. The status of the waters is classified as good criteria if the PI value is at a score of  $0 \leq Pij \leq 1.0$ ; lightly polluted if the PI value is at a score of  $1.0 < Pij \leq 5.0$ ; fairly polluted if the PI value is at a score of  $5.0 < Pij \leq 10$ , and heavily polluted if the PI value is at a score of  $Pij > 10$ . Histopathological assessment is conducted using a qualitative descriptive analysis. The analysis involved the microscopic examination of histopathological images in liver and kidney tissues. The images were subsequently juxtaposed with the histological images sourced from the Atlas of Fish Histology and other relevant references (Genten *et al.*, 2009). Table (2) presents the analysis conducted using the scoring methodology, and the quantified extent of damage presented in the study of Lestari *et al.* (2018).

**Table 2.** Histopathological damage scoring value

Damage (%)	Score	Category
< 25%	0	Normal
25% - 50%	1	Light
50% - 75%	2	Fair
>75%	3	Heavy

## RESULTS

### 1. Physical and chemical analysis

Table (3) displays the physical and chemical characteristics of water in the examined area of the Satui River. The initial sampling occurred in February, followed by a subsequent sampling in April.

**Table 3.** River water quality measurement results

Parameter	Unit	Average		Class II quality standard according to Gov. regulation No 22 of 2021
		P1	P2	
pH	-	7.5	8	6 – 9
Temperature	°C	27	28.5	28 – 30
BOD <sub>5</sub>	mg/l	2.9	7.8	3
COD	mg/l	0	27	25
DO	mg/l	6.45	5.3	4
TSS	mg/l	36.1	27.5	50

Description: <sup>1)</sup> P1 (1<sup>st</sup> sampling) & P2 (2<sup>nd</sup> sampling)

<sup>2)</sup> Government Regulation Number 22 of 2021 concerning the Implementation of Environmental Protection and Management concerning the Allocation of River Water Quality Standards

### 2. Pollution index analysis

Table (4) exhibits the findings of the water quality assessment and pollution index for the Satui River during February and April.

**Table 4.** Water quality analysis by pollution index

Average pollution index value		Index pollution	Category
P1	P2		
1.11	2.31	1.0<PI≤5.0	Lighty polluted

Description: <sup>1)</sup> P1 (1<sup>st</sup> sampling) & P2 (2<sup>nd</sup> sampling)

<sup>2)</sup> Decree of the State Minister of Environment of the Republic of Indonesia number 115 of 2003

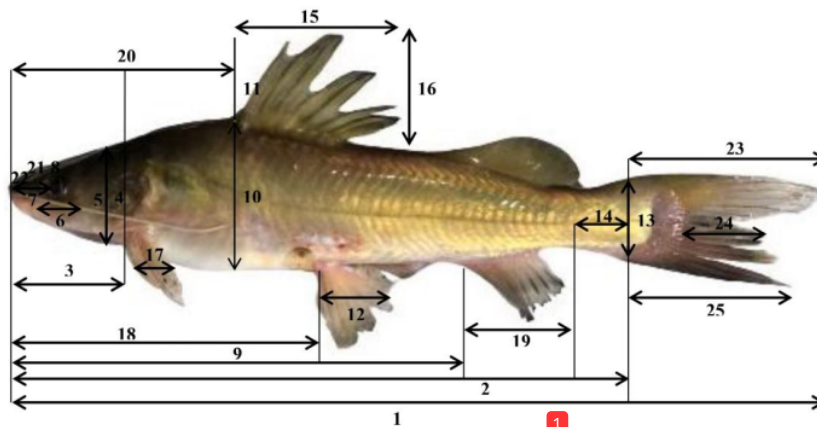
### 3. Morphometric characters

The morphometric character measurements of *Mystus nemurus* are presented in Table (5) and illustrated in Fig. (3).

**Table 5.** Morphometric character measurement results of *Mystus nemurus* (average ± SD) during February and April

Characters	N	February 2023	April 2023
TL	6	21.3 ± 0.79	21.6 ± 0.49
SL	6	16.1 ± 0.60	16.3 ± 0.27
HL	6	5.7 ± 0.37	5.8 ± 0.25
HW	6	4.0 ± 0.07	4.0 ± 0.00
HD	6	3.6 ± 0.05	3.6 ± 0.05
ED	6	1.0 ± 0.00	1.0 ± 0.00
SNL	6	1.5 ± 0.11	1.5 ± 0.00
IW	6	3.0 ± 0.03	3.0 ± 0.00
PAL	6	9.6 ± 0.08	9.6 ± 0.09
BD	6	4.5 ± 0.00	4.5 ± 0.04
BW	6	7.3 ± 0.18	7.3 ± 0.20
PVL	6	2.0 ± 0.00	2.0 ± 0.00
CPD	6	2.0 ± 0.00	2.0 ± 0.00
CPL	6	2.5 ± 0.03	2.5 ± 0.00
DBL	6	3.5 ± 0.03	3.5 ± 0.00
DFH	6	3.0 ± 0.07	3.0 ± 0.00
PCL	6	1.5 ± 0.00	1.5 ± 0.00
PPL	6	4.7 ± 0.22	4.8 ± 0.24
ABL	6	3.0 ± 0.07	3.0 ± 0.00
PDL	6	7.1 ± 0.15	7.1 ± 0.10
SNBL	6	1.0 ± 0.07	1.0 ± 0.00
MXBL	6	1.5 ± 0.04	1.6 ± 0.05
LUCL	6	4.5 ± 0.03	4.5 ± 0.00
LMCL	6	1.0 ± 0.07	1.0 ± 0.00
LCLL	6	4.1 ± 0.09	4.1 ± 0.10

Characters appreviations as in Fig. (3); N (Sum); SD (Standard deviation)



**Fig. 3.** Morphometric measurement scheme of river catfish showing: 1. Total length (TL); 2. Standard length (SL); 3. Head length (HL); 4. Head width (HW); 5. Head depth (HD); 6. Eye diameter (ED); 7. Snout length (SNL); 8. Interorbital width (IW); 9. Pre-anal fin length (PAL); 10. Body depth (BD); 11. Body width (BW); 12. Ventral fin length (PVL); 13. Caudal peduncle depth (CPD); 14. Caudal peduncle length (CPL); 15. Dorsal base length (DBL); 16. Dorsal fin height (DFH); 17. Pectoral fin length (PCL); 18. Pre-pelvic fin length (PPL); 19. Anal fin base length (ABL); 20. Pre-dorsal fin length (PDL); 21. Muzzle beard length (SNBL); 22. Maxillary barbels length (MXBL); 23. Length of upper caudal fin (LUCL); 24. Length middle caudal fin (LMCL), and 25. Length caudal lower fin (LCLL) (Personal Documentation, 2023).

## 4. Histopathological examination

### 4.1 Examination of the liver

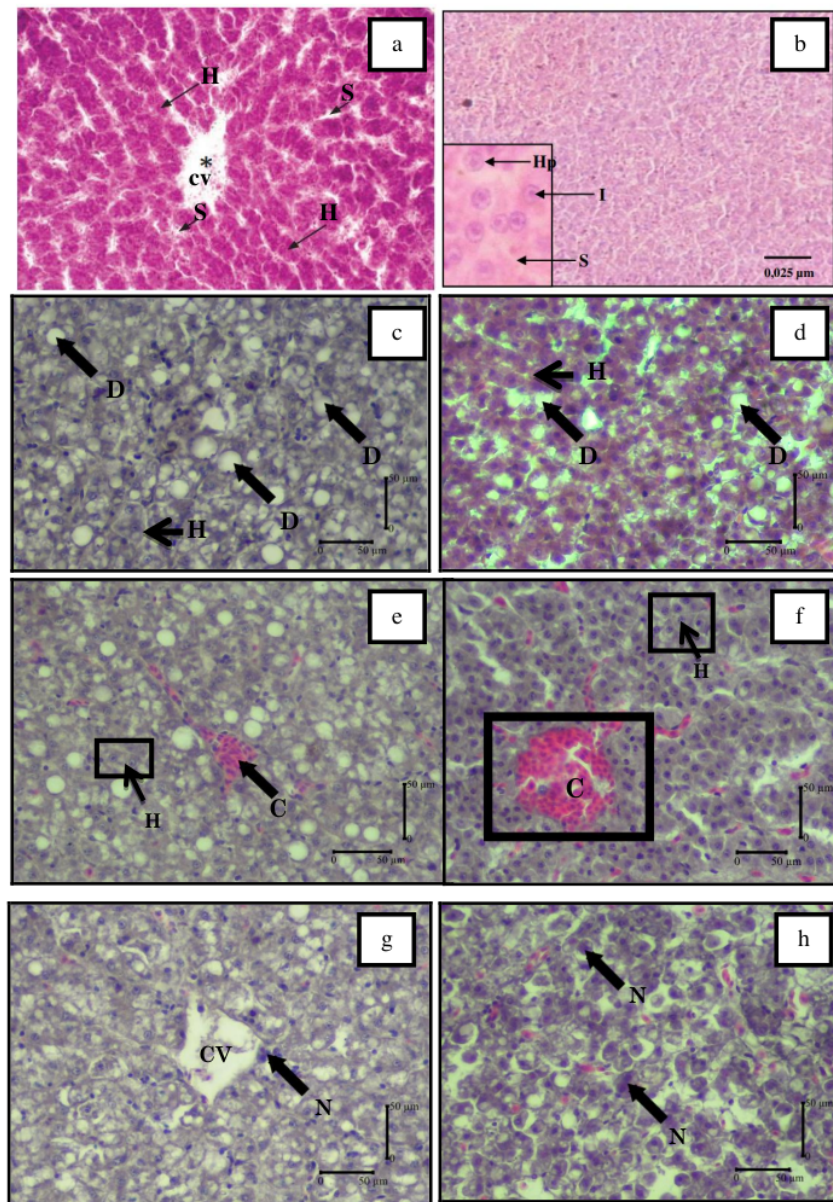
The results in Table (6) show the average histological damage score in the liver of *Mystus nemurus* from different sample specimens during this study. These results revealed that there were no significant differences ( $P > 0.05$ ). Moreover, Fig. (4) illustrates that the histological changes in liver of catfish, *Mystus nemurus*. The components of a typical fish liver are shown in Fig. (4 a), which included hepatocytes, sinusoids and central veins. Fig. (4b) depicts the histological composition of river catfish livers, encompassing hepatocytes, sinusoids and cell nuclei. Fig. (4c, d) shows the phenomenon of cell degeneration. Fig. (4e, f) depicts the instances of congestion, while Fig. (4g, h) illustrates the occurrences of necrosis.

**Table 6.** Average histological damage score of *Mystus nemurus* liver (average  $\pm$  S.D) during the present study from different sampling specimens

No	Group	Station	Liver histology damage score (average $\pm$ SD)		
			Degeneration	Congestion	Necrosis
1	P 1	1	1.26 $\pm$ 0.30 <sup>a</sup>	1.13 $\pm$ 0.23 <sup>a</sup>	1.13 $\pm$ 0.23 <sup>a</sup>
		2	1.06 $\pm$ 0.11 <sup>a</sup>	1.60 $\pm$ 0.20 <sup>a</sup>	1.00 $\pm$ 0.00 <sup>a</sup>
2	P 2	1	1.00 $\pm$ 0.00 <sup>a</sup>	1.93 $\pm$ 0.61 <sup>a</sup>	1.00 $\pm$ 0.00 <sup>a</sup>
		2	1.33 $\pm$ 0.30 <sup>a</sup>	1.66 $\pm$ 0.98 <sup>a</sup>	1.33 $\pm$ 0.57 <sup>a</sup>

Note: Numbers followed by the same letter in the same column showed no significant difference ( $P > 0.05$ ).

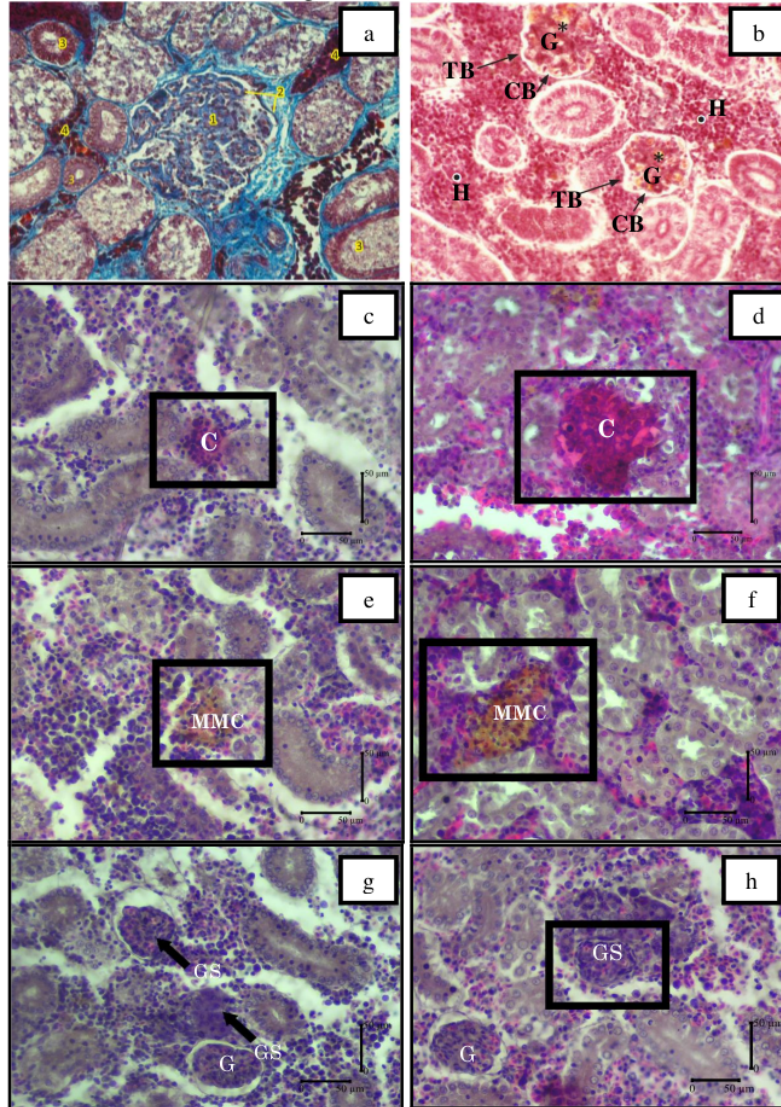




**Fig. 4.** River catfish heart stained with H&E indicated (a): Normal fish liver with hepatocytes (A), sinusoids (B), and central vein (CV) (*Genten et al., 2009*), x 100; (b): Normal fish liver with hepatocytes (Hp), sinusoids (S), and cell nuclei (I) (*Jumaida et al., 2022*), x 400; (c&d): Liver showed degeneration of cells (D) and hepatocytes (H), x 400; (e) Liver showed congestion (C) and hepatocytes (H), x 400; (f) Liver showed congestion (C) and Hepatocytes (H), x 400; (g&h) Liver showed necrosis in hepatocytes (N), Central Vein (CV), x 400.

#### 4.2 Examination of the kidney

The results revealed that the kidneys of typical fish consist of glomerulus, lumens, tubules and blood vessels, as depicted in Figs. (5.1, 5.2). The examination of the kidney structure in the river catfish specimens revealed the presence of congestion, as depicted in Figs. (5.3, 5.4). The Melano Macrophage Center (MMC) was also observed, as illustrated in Figs. (5.5, 5.6). Furthermore, glomerular swelling was detected, as shown in Figs. (5.7, 5.8).



**Fig. 5.** H&E stained kidneys of river catfish indicated (a) normal fish kidneys with glomerulus (1), lumens (2), tubules (3), and blood vessels (4) (Genten *et al.*, 2009), x 100; (b) normal fish kidney with glomerulus (G), Bowman's Capsule (CB), tubules (T), and Hemapoetik (H) (Genten *et al.*, 2009), x 100; (c&d) kidney shows congestion (□) (K), x 400; (e&f) kidney shows Melanomacrophage Center (□) (MMC), x 400; (g) kidney show swelling of glomerular (GS), glomerular (G) x 400; (h) kidneys show glomerular swelling (□) (GS) x 400.

**Table 7.** Average histological damage score of *Mystus nemurus* kidney (Average  $\pm$  S.D)

No	Group	Station	Kidney Histology Damage Score (Average $\pm$ SD)		
			MMC	Glomerular swelling	Congestion
1	P 1	1	1.00 $\pm$ 0.00 <sup>a</sup>	1.06 $\pm$ 0.11 <sup>a</sup>	1.00 $\pm$ 0.00 <sup>a</sup>
		2	1.06 $\pm$ 0.11 <sup>a</sup>	1.00 $\pm$ 0.00 <sup>a</sup>	1.13 $\pm$ 0.23 <sup>a</sup>
2	P 2	1	1.00 $\pm$ 0.00 <sup>a</sup>	1.00 $\pm$ 0.00 <sup>a</sup>	1.13 $\pm$ 0.11 <sup>a</sup>
		2	1.20 $\pm$ 0.39 <sup>a</sup>	1.00 $\pm$ 0.00 <sup>a</sup>	1.06 $\pm$ 0.11 <sup>a</sup>

Note: Numbers followed by the same letter in the same column show no significant difference ( $P > 0.05$ )

## DISCUSSION

In general, pollution from human activities causes considerable changes in freshwater quality. This pollution contributes to the instability and destruction of ecosystems. Globally, the contamination of freshwater by organic and inorganic pollutants is a big issue. Inorganic pollutants are common and can hinder various biological processes in aquatic organisms, particularly fish (Hussain *et al.*, 2019). The Satui River is a source of surface freshwater that offers numerous benefits to the local population. Heavy activity along the Satui River is suspected to contribute to water contamination. The quality of rivers will fluctuate according to the development of the aquatic environment, which is influenced by various human activities and existence (Mardhia & Abdullah, 2018). The quality of aquatic well-being can be determined by analyzing water's physical and chemical characteristics.

The analysis of the Satui River water acidity indicated that the pH levels observed during the initial and subsequent samplings fell within the acceptable range of 6 to 9, as specified by the class II water quality standards. The pH rose from the first measurement of 7.5 to the second measurement of 8. Organic and inorganic waste dumped into rivers (Yulastuti, 2011) increase the pH value. Based on the foundation, as mentioned earlier, the observed rise in pH levels of the Satui River water during the initial and subsequent samplings can be ascribed to the discharge of industrial, residential and agricultural effluents that infiltrate the Satui River. Aquatic organisms may face lethal consequences due to fluctuations in pH levels resulting from industrial discharges (Yulis, 2018).

The outcomes of the temperature measurements conducted on the Satui River indicate that the water temperature ranged between 27 & 29°C during the initial and subsequent samplings at Station 1 and Station 2. The maximum temperature recorded during the second sampling period was 29°C. The ideal temperature for organisms to live in water is 25°C to 30°C (Mardhia & Abdullah, 2018). Since the sampling site is situated in an unobstructed area that receives direct sunlight, the incident solar radiation reaching the aquatic environment is characterized by a notably high intensity, leading to elevated water temperatures (Marlina *et al.*, 2017). This is consistent with the study of Irianto (2003) who stated that, fluctuations in water temperature are caused by heat absorption and release, as well as scorching sun.

Chemical oxygen demand (COD) is the amount of oxygen required to oxidize organic matter, both chemically biodegradable and non-biodegradable (Marlina *et al.*, 2017). During the initial sampling, the Satui River water exhibited undetectable levels (0) of the chemical oxygen demand (COD) parameter. However, the COD measurement yielded a 27mg/ L result in the subsequent sampling. As per Government Regulation of the Republic of Indonesia

Number 22 of 2021, the established quality standard for chemical oxygen demand (COD) is 25mg/ L. The elevated COD readings observed in the second sampling event can be attributed to multiple berthing vessels near the sampling location and the discharge of residential waste from the surface that was subsequently carried away by the prevailing current. Yudo (2010) claimed that, an elevated proportion of chemical oxygen demand (COD) in water indicates heightened pollution. Prolonged exposure to elevated chemical oxygen demand (COD) concentrations can result in mortality among fish species (Purwanto *et al.*, 2014).

The recorded measurements for the concentration of biochemical oxygen demand (BOD) in the water of the Satui River were 2.9mg/ L during the initial sampling and 7.8mg/ L during the subsequent sampling. The elevated biochemical oxygen demand (BOD) concentration indicates the presence of contaminants in the water (Mahyudin *et al.*, 2015). Yohannes *et al.* (2019) stated that an elevated biochemical oxygen demand (BOD) value signifies a substantial presence of organic substance within a water body. This is because the BOD value serves as an indicator of the quantity of oxygen required by bacteria to oxidize organic matter present in water. The second sampling, conducted in the morning, yielded the highest biochemical oxygen demand (BOD) level of 7.8 mg/L. During the second sampling, it is hypothesized that numerous residents dispose of waste from dishwashing, bathing, and laundry activities. Moreover, many vessels were moored along the banks of the river during the subsequent sampling period. Consequently, water bodies are contaminated by a diverse range of pollutants originating from domestic sewage. According to Kartika *et al.* (2016), the wastes that produce significant levels of BOD are home and industrial waste. High BOD value indicates a low dissolved oxygen content in the waters, causing death in fish due to a lack of oxygen (anoxia). High BOD levels can also affect fish populations in bodies of water (Daroini & Arisandi, 2020).

The initial sampling of Satui River water yielded a dissolved oxygen (DO) measurement of 6.45mg/ L; whereas, the subsequent sampling recorded a DO measurement of 5.3mg/ L. The concentration of dissolved oxygen (DO) in water can be affected by various factors, including the content of total suspended solids (TSS), salinity, temperature, degradation of organic matter, rate of photosynthesis and atmospheric pressure (Christiana *et al.*, 2020). In comparison to class II water quality standards for dissolved oxygen (DO) parameters as stipulated in the Government Regulation of the Republic of Indonesia No. 22 of 2021, which sets the threshold at four mg/L, the current state of the Satui River's water quality with regards to DO parameters remains within the prescribed limits. Dissolved oxygen (DO) significantly impacts fish's life, particularly in growth, tissue regeneration and reproductive processes. Oxygen depletion in contaminated aquatic environments leads to mortality among fish populations (Astuti & Lismining, 2018).

The initial measurement of total suspended solids (TSS) yielded a result of 36.1mg/ L, while the second measurement recorded a value of 27.5mg/ L. The Satui River's TSS value remains below the established water quality standard of 50mg/ L, thus making it suitable for utilizing in TSS parameter designations. Effendi (2003) suggests that TSS values ranging from 25 to 80mg/ L are appropriate for fisheries. Elevated turbidity levels can potentially interfere with the osmoregulatory mechanisms of aquatic organisms. The TSS measurements from the Satui River exhibit a range of 21-37.5mg/ L. Notably, these values do not have any discernible impact on fish farming operations, as per their designated threshold.

Examining the current state of river water quality about established water quality standards provides insights into the pollution level of a specific water source at a given moment. A river is considered polluted when it cannot fulfill its intended purpose. The

analysis of the pollution index calculation reveals a noticeable rise in the pollution index, with an increase from 1.11 during the first sampling to 2.31 during the second sampling. According to the analysis conducted using the pollution index (PI) methodology, the water quality classification of the Satui River falls within the lightly polluted category. This condition is believed to be attributed to the discharge of domestic/household waste and waste generated by ships near the sampling site. This finding aligns with the research conducted by **Sofiana *et al.* (2022)**, which indicates that various human activities carried out by the local community residing along the Martapura River in Banjar District have led to the contamination of water resources.

Fig. (3) displays the morphometric attributes of river catfish inhabiting the Satui River. The findings from morphological observations indicated that river catfish exhibit a yellowish-gray hue on the dorsal region of their body. Furthermore, their body structure is elongated, lacking scales, and possessing a smooth texture. The observed fish exhibited a discernible dark lateral line from the gill cover to the caudal peduncle. River catfish individual possesses three barbels around the oral region and an additional pair adjacent to the respiratory apertures. The caudal fin exhibits a bifurcated structure, while the dorsal fin possesses rigid, pointed appendages. The patil spines can be observed on the pectoral and dorsal fins. The morphometric characteristics of river catfish exhibited minimal variation in terms of body sizes. The mean total length of river catfish collected at station 1 was 21.45cm, while at station 2, it was 21.85cm. The morphometric averages of male and female river catfish from two locations were statistically insignificant, as demonstrated in a prior study conducted by **Firiola and Elvyra (2022)**.

The productivity and development of fish can be influenced by the quality of the water in which they reside. Favorable water quality conditions benefit fish's life, while unsuitable water quality can impede their growth and development, resulting in suboptimal outcomes (**Ayuniar & Hidayat, 2018**). The study's findings indicated variation in the morphometrics of the river catfish, leading to the classification of the water quality as lightly polluted. According to **Dauhan *et al.* (2014)**, fish's morphometric growth is influenced by water quality parameters. In their study, **Gunawan *et al.* (2019)** described that morphometric characters are correlated with water quality parameters since they are influenced by the prevailing water conditions that facilitate the elongation of these morphometric characters. For river catfish to achieve optimal growth and development, providing them with a conducive aquatic environment is imperative.

In numerous research investigations, histological alterations have been widely employed to explore various human and animal diseases and assess the impact of chemical contaminants on fish tissue. Moreover, histology proves to be highly advantageous due to its ability to accurately assess the physiological condition of fish at a given moment. Examining liver and kidney tissue in fish can yield valuable insights into their physiological well-being and overall health in response to the detrimental impacts of pollution. Therefore, it is appropriate to implement biomonitoring programs (**Giltrap *et al.*, 2020**). The presence of pollution can lead to a decline in the quality of water, which in turn can result in structural and functional harm to the organs of different fish species (**Mandia *et al.*, 2013**). Fish absorb pollutants directly from the water and indirectly through food (**Luczynska *et al.*, 2018**). According to **Altinok and Capkin (2007)**, the histopathological method has been documented as an effective means of identifying and characterizing pathological alterations in the organs of fish exposed to contaminants. **Pieterse (2008)** elucidated that histopathology is a valuable tool for evaluating the extent of contamination.

The liver and kidneys are essential organs frequently employed as bioindicators of fish health in freshwater ecosystems. Tissues that encounter external contaminants are more susceptible to adverse effects when subjected to elevated levels of chemical pollutants. Using histopathological examination to assess pollutant exposure is a valuable approach for evaluating the extent of pollution. Pollution induces morphological and cytological alterations in aquatic organisms' hepatic and kidney tissue, specifically fish. The condition causes harm to the nephrons of the kidneys resulting in decreased kidney function (Hussain *et al.*, 2019).

27 The study revealed histological alterations in river catfish's hepatic and kidney tissues. The liver is an organ that plays a significant role in the processes of detoxification and biotransformation (Camargo & Martinez, 2007). Pollutants frequently impact the liver due to their crucial functions in metabolism, nutrition, carbohydrate metabolism, protein synthesis and enzymatic processes. The assessment of liver histopathology serves as a crucial determinant in evaluating the extent of fish pollutants and the overall health condition of fish (Oz *et al.*, 2020). Based on data on the liver histopathology of river catfish, it was observed that the damage manifested in the form of cellular degeneration, congestion and necrosis. Consequently, it can be inferred that the pollutants present in the Satui River possess toxic characteristics.

The degeneration of liver cells in river catfish is marked by the progressive reduction in the size of cell nuclei, increased concentration of color, and the presence of cytoplasmic vacuoles containing fat. Cellular degeneration results from the failure to eliminate excess fat from the cells (Lekatompessy *et al.*, 2021). Silviany (2004) stated that exposure of fish to lead has been found to induce fatty degeneration in the liver, resulting in a decline in the overall complexity of liver function. In addition, cells undergoing persistent degeneration will encounter congestion (Juanda & Edo, 2018). According to Sari and Perwira (2016), microscopic examination revealed the presence of cell degeneration, characterized by the appearance of vacuoles containing fat in the cytoplasm of the liver. Additionally, core damage was observed, accompanied by a reduction in the size of liver tissue (Fig. 4c, d). This is in line with the results of Abdel-Moneim *et al.* (2012) who reported that cell degeneration is a frequently observed phenomenon that is readily discernible.

Congestion is the pathological accumulation of densely packed red blood cells in fish's blood vessels, indicating abnormal liver conditions (Sulistyorinie *et al.*, 2020). The present study demonstrated that the liver tissue exhibited a heightened reddish hue, which can be attributed to the accumulation of red blood cells within the blood vessels, signifying a state of congestion (Fig. 4e, f). According to Masfiah *et al.* (2018), congestion arises due to an inflammatory response that manifests as a discernible alteration in the hue of the red blood cells. The onset of congestion is characterized by the progressive degeneration of cells, thereby classifying it as a moderate level of damage. Additionally, congestion may arise due to physical trauma caused by parasitic infections or disorders of the circulatory system (Juanda & Edo, 2018).

In addition, the liver observations indicated the presence of necrosis, a form of tissue damage. Necrosis is the demise of cellular and tissue structures in fish organs, resulting from metabolic dysfunctions induced by pollutants. This is reinforced in the study of Triadayani *et al.* (2010); necrosis refers to the phenomenon of cellular demise accompanied by the rupture of the plasma membrane. In their findings, Wolf and Wheeler (2018) stated that, numerous histopathological alterations such as necrosis in fish can be attributed to endocrine system dysfunction resulting from exposure to pollutants. Nurdin (2008) postulated that, the exposure of goldfish to pesticides has been found to induce necrotic damage in the liver. Fat

accumulation in significant amounts leads to liver cell death due to pesticide toxicity. Additional investigation is required within this particular framework to ascertain the origin of pollution in the Satui River.

Due to fish kidneys' direct and constant exposure to dissolved chemicals in aquatic environments, they exhibit a heightened sensitivity to chemical fluctuations in freshwater ecosystems. The kidneys play a vital role in regulating the body's pH, maintaining fluid volume, and facilitating erythropoiesis. Fish maintain water and electrolyte balance to ensure a stable internal environment. Because of these characteristics, the kidneys are a remarkable indicator of potential contamination and environmental stress in the vicinity of fish (Hussain *et al.*, 2019). The kidneys' primary function is to eliminate waste and xenobiotics from the circulatory system, thereby ensuring a stable internal environment regarding water and salt metabolism and excretory function (Santoso *et al.*, 2021). The kidneys are organs that exhibit susceptibility to the adverse effects of chemical pollutants (Metcalf, 1998). Hence, the kidneys are prone to exposure to various toxic substances, which can lead to histopathological impairments, including congestion, Melano Macrophage Center (MMC) presence, and glomerular swelling. These damages can be attributed to the exposure of the kidneys to heavy metals and other pollutants.

Congestion in the kidneys of river catfish inhabiting the Satui River was hypothesized to be attributed to compromised blood flow, leading to an inadequate supply of oxygen and essential nutrients. Congestion is defined by a red hue within the cellular composition due to increased erythrocytes leading to intravascular coagulation (Parameswari *et al.*, 2013). Histopathological alterations characterized by congestion signify an elevation in the number of blood cells within the blood vessels, resulting in the capillaries appearing to be maximally dilated and occupied by erythrocytes (Wagih *et al.*, 2014). The kidney congestion in river catfish can be observed in Fig. (5c, d). Guardiola *et al.* (2013) found that cadmium pollutants in *Sparus aurata* fish leads to congestion, as evidenced by a distinct red coloration in the blood vessels.

The presence of melanomacrophage centers (MMC) in fish organs tends to exhibit an increase in quantity during chronic stress although their continued existence is not always guaranteed (Pratiwi *et al.*, 2019). According to Roberts (1978), MMC in cells is a protective mechanism against the harmful effects of toxic substances, particularly heavy metals. MMC is a collection of macrophages that indicate inflammation. The presence of MMC in cells is attributed to an inherent mechanism of self-defense in response to the invasion of foreign bodies. Reasonable quantities of MMC involve components derived from fish's immune system, allowing the process of phagocytosis (Sianturi *et al.*, 2022). Agius and Roberts (2003) stated that certain toxic chemicals have the potential to induce a rise in the quantity of melanomacrophage centers within the kidneys. The presence of MMC in the kidneys of river catfish is evident from the observations made in Fig. (5e, f). Its brown pigment distinguishes this MMC.

The kidneys of river catfish obtained from the Satui River exhibited signs of glomerular swelling, indicating damage. The glomerulus experiences swelling due to the obstruction caused by toxic compounds in the glomerulus. Despite the low concentration of these compounds, their prolonged presence in the fish's body leads to contamination. Glomerular swelling refers to the pathological condition wherein the glomerulus undergoes tissue damage, resulting in an enlargement of its size and the formation of adhesions between the glomerulus and Bowman's capsule (Aliza, 2020). Handy and Penrince (1993) found swelling in the glomerulus of the kidney of the fish *Oncorhynchus mykiss* contaminated by

mercury chloride. **Camargo and Mertinez (2007)** also found glomerular swelling in the kidneys of *Prochilodus lineatus* contaminated with mercury waste.

The findings from the biomonitoring study utilizing histopathological bioindicator tools on the liver and kidneys of river catfish indicated that these organs exhibited a moderate level of damage, ranging from 25% to 50%, as indicated by a score of 1. Additionally, the present study observed insignificant differences ( $P > 0.05$ ) in the histopathological impairment of the liver and kidneys in river catfish located at stations 1 and 2. Based on the assessment of pollution levels in the first and second samplings, it can be concluded that the Satui River exhibited a low degree of pollution. Nevertheless, if this scenario persists without proper regulation and regular monitoring by concerned entities like the Environmental Agency, pollution's proliferation and origins will escalate with the rise in human-induced activities in the Satui area. The cause of histopathological damage observed in river catfish is hypothesized to be associated with exposure to chemical pollutants, including domestic waste, heavy metals and pesticides. Consequently, it is recommended that further investigations should be conducted to clarify the specific sources and origins of these pollutants. The significance of this matter lies in the economic value of river catfish, which is highly regarded for its nutritional content and palatability. By mitigating the detrimental impacts of pollutants on river catfish populations, the potential risks to public health can be reduced.

## CONCLUSION

The water quality in the Satui River is classified as lightly polluted, and the river catfish, which is abundant in the area and holds economic and nutritional importance, has exhibited histopathological liver damage characterized by fatty degeneration, congestion and necrosis. In the context of the river catfish, histopathological alterations observed in the kidney encompass the presence of melanomacrophage centers (MMCs), glomerular congestion and glomerular swelling. Histological examinations conducted on river catfish to evaluate contamination levels in aquatic environments can yield valuable insights into the overall ecological well-being of these ecosystems. The liver and kidneys of river catfish serve as valuable bioindicators for biomonitoring since they allow for the assessment of potential contamination and the presence of pressure or stress in the aquatic environment.

## REFERENCES

- Abdel-Moneim, A.M.; Al-Kahtani, M.A. and Elmenhawy, O.M. (2012).** Histopathological biomarkers in gills and liver of *Oreochromis niloticus* from polluted wetland environments, Saudi Arabia. *Chemosphere*, **88**(8): 1028-1035. DOI:[org/10.1016/j.chemosphere.2012.04.001](https://doi.org/10.1016/j.chemosphere.2012.04.001)
- Agius, C. and Roberts R.J. (2003).** Melano-macrophage centers and their role in fish pathology, *J. Fish. Dis.*, **26**: 499-509. DOI: [org/10.1046/j.1365-2761.2003.00485.x](https://doi.org/10.1046/j.1365-2761.2003.00485.x)
- Aliza, D. (2020).** Histopathological Picture of Mujair Fish Kidney (*Oreochromis mossambicus*) exposed to mercury chloride ( $HgCl_2$ ). *Jurnal Ilmiah Mahasiswa Veteriner*, **5**(1). DOI: [org/10.21157/j.med.vet.v7i2.2950](https://doi.org/10.21157/j.med.vet.v7i2.2950)
- Altinok, I. and Capkin, E. (2007).** Histopathology of rainbow trout exposed to sublethal concentrations of methiocarb or endosulfan. *Toxicologic Pathology*, **35**(3): 405-410. DOI:



[org/10.1080/01926230701230353](https://doi.org/10.1080/01926230701230353)

- Astuti, Y. S. D. L. P. and Lismining, P. (2018).** Dissolved Oxygen Response to Pollution and Its Effects on the Existence of Fish Resources in the Citarum River. *Journal of Environmental Technology*, **19**(2): 203.
- Ayuniar, L. N. and Hidayat, J. W. (2018).** Analysis of the physical and chemical quality of water in the aquaculture area of Majalengka Regency. *EnviScience Journal (Environment Science)*, **2**(2): 68-74. DOI: [org/10.30736/2ijev.v2iss2.67](https://doi.org/10.30736/2ijev.v2iss2.67)
- Camargo, M.M.P. and Martinez, C.B.R. (2007).** Histopathology of gills, kidney and liver of a Neotropical fish caged in an urban stream. *Neotropical Ichthyology*, **5**(3): 327–336. DOI: [org/10.1590/s1679-62252007000300013](https://doi.org/10.1590/s1679-62252007000300013)
- Christiana, R.; Anggraini, I.M. and Syahwanti, H. (2020).** Analysis of Water Quality and Quality Status As well as the Pollution Burden of the Mahap River in Sekadau Regency, West Kalimantan. *Jurnal Serambi Engineering*, **5**(2). DOI: [org/10.32672/jse.v5i2.1921](https://doi.org/10.32672/jse.v5i2.1921)
- Daroini, T.A. and Arisandi, A. (2020).** Analisis BOD (*Biological Oxygen Demand*) di Perairan Desa Prancak Kecamatan Sepulu, Bangkalan. *Juvenil*, **1**(4): 558–566.
- Dauhan, R.E.S. and Efendi, E. (2014).** The effectiveness of the aquaponics system in reducing ammonia concentrations in fish farming systems. *E-Journal of aquaculture engineering and technology*, **3**(1): 297-302.
- Dwiyitno; Aji, N. and Indriati, N. (2008).** Heavy Metal Residues in Fish. *Journal of Postharvest and Marine and Fisheries Biotechnology*, **3**(2): 147–155. DOI: [org/10.15578/jpbkp.v3i2.19](https://doi.org/10.15578/jpbkp.v3i2.19)
- Effendi, H. (2003).** Study of Water Quality for Resource and Environmental Managemen. Kanisius. Yogyakarta.
- El-Shenawy, N.S.; EL-Hak, H.N.G.; Ghobashy, M.A.; Mansour, F.A.; and Soliman, M. F. (2021).** Using antioxidant changes in liver and gonads of *Oreochromis niloticus* as biomarkers for the assessment of heavy metals pollution at Sharkia province, Egypt. *Regional Studies in Marine Science*, **46**: 101863. DOI: [org/10.1016/j.rsma.2021.101863](https://doi.org/10.1016/j.rsma.2021.101863)
- Feist, S.W.; Stentiford, G.D.; Kent, M.L.; Santos, A.R. and Lorange, P. (2015).** Histopathological assessment of liver and gonad pathology in continental slope fish from the northeast Atlantic Ocean. *Marine Environmental Research*, **106**: 42-50. DOI: [org/10.1016/j.marenvres.2015.02.004](https://doi.org/10.1016/j.marenvres.2015.02.004)
- Giltrap, M.; Ronan, J.; Tanner, C.; Beirn, F.X.O. and Lyons, B. P. (2020).** Application of a weight of evidence approach utilising biological effects, histopathology and contaminant levels to assess the health and pollution status of Irish blue mussels (*Mytilus edulis*) n a. *Marine Environmental Research*, **122**: 33-45. DOI: [org/10.1016/j.marenvres.2016.09.004](https://doi.org/10.1016/j.marenvres.2016.09.004)
- Firiola, S. and Elvyra, R. (2022).** Morphometric Characteristics of mg / L (*Hemibagrus hoevernii*, Bleeker 1846) in Langgam and Tambak Village, Kampar River, Riau Province. *Biospecies*, **15**(2): 61-72. DOI: [org/10.22437/biospecies.v15i2.12887](https://doi.org/10.22437/biospecies.v15i2.12887)
- Genten, F.; Terwinghe, E. and Danguy, A. (2009).** *Atlas Of Fish Histology*. Science Publishers. USA.

- Goenarso, D. (1988).** *Changes in Fish Physiology as an Indicator of the Presence of Insecticides and Detergents In water.* Dissertation. ITB. Bandung.
- Guardiola, F.A.; Cuesta, A.; Meseguer, J.; Martínez, S.; Martínez-Sánchez, M.J.; Pérez-Sirvent, C. and Esteban, M.A. (2013).** Accumulation, histopathology and immunotoxicological effects of waterborne cadmium on gilthead seabream (*Sparus aurata*). *Fish & shellfish immunology*, **35**(3): 792-800. DOI: [org/10.1016/j.fsi.2013.06.011](https://doi.org/10.1016/j.fsi.2013.06.011)
- Gunawan, H.; Tang, U.M. and Mulyadi, M. (2019).** The effect different of temperature on growth and survival rate of *Kryptopterus lois*. *Journal of Fisheries and Marine Affairs*, **24**(2): 101-105.
- Handy, R.D. and Penrice, W.S. (1993).** The influence of high oral doses of mercuric chloride on organ toxicant concentrations and histopathology in rainbow trout, *Oncorhynchus mykiss*. *Comparative Biochemistry and Physiology Part C: Pharmacology, Toxicology and Endocrinology*, **106**(3): 717-724. DOI: [org/10.1016/0742-8413\(93\)90232-A](https://doi.org/10.1016/0742-8413(93)90232-A)
- Hussain, B.; Fatima, M.; Al-ghanim, K.A. and Mahboob, S. (2019).** Environmentally induced nephrotoxicity and histopathological alternations in *Wallago attu* and *Cirrhinus mrigla*. *Saudi Journal of Biological Sciences*, **26**(4): 752-757. DOI: [org/10.1016/j.sjbs.2019.02.003](https://doi.org/10.1016/j.sjbs.2019.02.003)
- Ibrahim, L.A. and Elbastamy, E. (2023).** The influence of water quality on fish tissues and blood profile in Arab. *The Egyptian Journal of Aquatic Research*, **49**(2): 235-243 DOI: [org/10.1016/j.ejar.2023.01.006](https://doi.org/10.1016/j.ejar.2023.01.006)
- Imaki, A.; Kawamoto, A. and Suzuki, A. (1978).** A History of Freshwater Fishes Collected from the Kapuas Rivers, Kalimantan Indonesia. The Institute for Breeding. Tokay University of Agriculture.
- Irianto, A. (2003).** *Probiotic Aquaculture*. Gadjah Mada University Press. Yogyakarta.
- Izquierdo, M.S.; Fernandez-Palacios, H. and Tacon, A.G.J. (2001).** Effect of broodstock nutrition on reproductive performance of fish. *Aquaculture*, **197**(1-4), 25-42. DOI: [org/10.1016/S0044-8486\(01\)00581-6](https://doi.org/10.1016/S0044-8486(01)00581-6)
- Juanda, S.J. and Edo, S.I. (2018).** Histopathology of Gills, Liver and Intestines of Catfish (*Clarias gariepinus*) in Kupang City, East Nusa Tenggara. *Fisheries Science: Indonesian Journal of Fisheries Science and Technology*, **14**(1): 23-29. DOI: [org/10.14710/ijfst.14.1.23-29](https://doi.org/10.14710/ijfst.14.1.23-29)
- Jumaida, Morina R, S., and Iesje, L. (2022).** Histopathology of *Mystus nemurus* Liver That Were Fed With Feed Added With *Psidium guajava* and *Andrographis paniculata* NESS. *Diss. Riau University*, **10**(1), 1-52.
- Kartika, Dita, Nurjazuli and Budiyo. (2016).** The Ability of Java Tamarind Seed Powder in Reducing TSS, Trubidity, and Ammonia Liquid Waste Treatment PT. Utama Multiniaga Indonesia. *Journal of Public Health*. **4**(4): 917-924.
- Komari, N.; Irawati, U. and Novita, E. (2012).** Content of Cadmium and Zinc in Baung Fish (*Hemibagrus nemurus*) in the Trisakti Waters of Banjarmasin, South Kalimantan. *Sains Dan Terapan Kimia*, **7**(1): 42-49. <https://ppjp.ulm.ac.id/journal/index.php/jstk/article/view/2119>

- Kottelat, M., Whitten, A.J., Kartikasari, S.N & Wirjoatmojo, S. (1993):** Freshwater fishes of western Indonesia and Sulawesi. Hong Kong, Perpilus Edition.
- Lekatompessy, A.A., Pattipeiluhu, S.M. and Pattiasina, B.J. (2021).** Histopathology and Expression TNF- $\alpha$  (Tumor Necrosis Factor- $\alpha$ ) Against Liver Damage due to Parasite Invasion in Mackerel (*Rastrelliger brachysoma*). Jurnal Sumberdaya Akuatik Indopasifik, **5**(4): 447-452. DOI: [org/10.46252/jsai-fpik-unipa.2021.vol.5.no.4.176](https://doi.org/10.46252/jsai-fpik-unipa.2021.vol.5.no.4.176)
- Lestari, W.P.; Wiratmini, N.I. and Dalem, A.A.G.R. (2018).** Histological Structure of Fish Gills Mujair (*Oreochromis mossambicus* L.) As an Indicator of Water Quality in Lagoon Nusa Dua, Bali. Simbiosis, **6**(2): 45-49. DOI: [org/10.24843/jsimbiosis.2018.v06.i02.p03](https://doi.org/10.24843/jsimbiosis.2018.v06.i02.p03)
- Łuczynska, J.; Paszczyk, B. and Łuczynski, M.J. (2018).** Fish as a bioindicator of heavy metals pollution in aquatic ecosystem of Pluszne Lake, Poland, and risk assessment for consumer's health. Ecotoxicology and environmental safety, **153**: 60-67. DOI:[org/10.1016/j.ecoenv.2018.01.057](https://doi.org/10.1016/j.ecoenv.2018.01.057)
- Mahyudin, M.; Soemarno, S. and Prayogo, T.B. (2015).** Water quality analysis and strategy control of Metro River water pollution in Kepanjen City, Malang Regency. Indonesian Journal of Environment and Sustainable Development, **6**(2). DOI: <https://jpal.ub.ac.id/index.php/jpal/article/view/193>
- Mandia, S.; Marusin, N. and Santoso, P. (2013).** Histological analysis of kidney of Asang fish (*Osteochilus hasseltii*) in lakes Maninjau and Singkarak, West Sumatra. UNAND Journal of Biology, **2**(3): 194-200.
- Mardhia, D. and Abdullah, V. (2018).** Analysis of the water quality analysis of the Brangbiji river, Sumbawa Big. Journal of Tropical Biology, **18**(2): 182-189. DOI:[org/10.29303/jbt.v18i2.860](https://doi.org/10.29303/jbt.v18i2.860)
- Marlina, N.; Hudori, H. and Hafidh, R. (2017).** Effect of Channel Roughness and River Water Temperature on Water Quality Parameters COD, TSS in the Winongo River Using QUAL2Kw Software. Journal of Environmental Science & Technology, **9**(2): 122-133. DOI: [org/10.20885/jstl.vol9.iss2.art6](https://doi.org/10.20885/jstl.vol9.iss2.art6)
- Masfiah, I.; Andayani, S. and Suprastyani, H. (2018).** The effect of crude extract of dragon fruit peel (*Hylocereus costaricensis*) on the histopathology of tilapia liver (*Oreochromis niloticus*) infected with *Aeromonas hydrophila*. JFMR (Journal of Fisheries and Marine Research), **2**(3): 149-159. DOI: [org/10.21776/ub.jfmr.2018.002.03.2](https://doi.org/10.21776/ub.jfmr.2018.002.03.2)
- Metcalf, C.D. (1998).** Toxicopathic responses to organic compounds in: fish disease and disorders, in J.F Leatherland. CABI Publishing, New York. **2**: 133-162.
- Nuraeni, A.; Samosir, A. and Sulistiono, S. (2022).** Lead heavy metal (Pb) accumulation in the liver of catfish (*Pangasius djambal*) in Saguling Reservoir, West Java. Journal of Fisheries and Marine Technology, **12**(2): 113–123. DOI: [org/10.24319/jtpk.12.113-123](https://doi.org/10.24319/jtpk.12.113-123)
- Nurdin, M. (2008).** Effect of US Paraquat Noxone 297 Pesticide on Survival, Growth and Liver Histology of Goldfish Fry (*Cyprinus Carpio*). Thesis. Department of Aquaculture. Faculty of Agriculture. Sriwijaya University. Palembang.
- Öz, M.; Yavuz, O. and Bolukbas, F. (2020).** Histopathology changes in the rainbow trout (*Onchorhynchus mykiss*) consuming boric acid supplemented fish fodder. Journal of Trace Elements in Medicine and Biology, **62**: 126581. DOI: [org/10.1016/j.jtemb.2020.126581](https://doi.org/10.1016/j.jtemb.2020.126581)
- Parameswari, W.; Sasanti, A.D. and Muslim, M. (2013).** Bacterial Population,

- Histopathology, Survival and Growth of Snakehead Fish Seeds reared in Media with the Addition of Probiotics. *Journal of Indonesian Swamp Aquaculture*, **1**(1): 76-89. <https://ejournal.unsri.ac.id/index.php/jari/article/view/1781>
- Pieterse, G.M. (2008).** *Histopathological changes in the testis of Oreochromis mossambicus (Cichlidae) as a biomarker of heavy metal pollution.* University of Johannesburg (South Africa).
- Pratiwi, D.; Aliza, D.; Nazarudin, N.; Zuhrawati, Z.; Budiman, H. and Daud, R. (2019).** The distribution of melanomacrophage center in liver and kidney of Tilapia fish that infected by *Aeromonas hydrophilic*. *Jurnal Medika Veterinaria*, **13**(2): 248-252. DOI: [org/10.21157/j.med.vet.v13i2.3648](https://doi.org/10.21157/j.med.vet.v13i2.3648)
- Purwanto, H.; Pribadi, T.A. and Martuti, N.K.T. (2014).** Community structure and distribution of fish in the waters of the Juwana Pati River. *Life Science*, **3**(1): 59-67.
- Purwati, S.U. (2015).** Characteristics of cisadane bioindicators: Study of macrobenthic utilization to assess the quality of the Cisadane River. *Ecolab*, **9**(2): 47-59. DOI: [org/10.20886/jklh.2015.9.2.47-59](https://doi.org/10.20886/jklh.2015.9.2.47-59)
- Roberts, J.R. (1978).** *Fish Patalogy.* University of Stirling. Scotland, London..
- Safratilofa, S. (2017).** Histopathology of Liver and Kidney of Catfish (*Pangasionodon hypophthalmus*) injected bacteria *Aeromonas hydrophila*. *Journal of River And Lake Aquaculture*, **2**(2): 83-88. DOI: [org/10.33087/akuakultur.v2i2.21](https://doi.org/10.33087/akuakultur.v2i2.21)
- Santoso, H.B.; Hidayaturrahmah, and Bambang, S.S. (2021).** Application of Histopathological Biomarkers of Liver and Kidney of Timpakul Fish (*Periophthalmodon schlosseri*) as an Early Warning of Lead (Pb) Heavy Metal Toxicity in the Barito River Estuary. In: *Proceedings of the National Seminar on Wetland Environment*, **6**(3).
- Sari, A.H.W. and Perwira, I.M. (2019).** Histopathological biomarkers of mullet liver (tiny cephalus) as an early warning of chromium (Cr) toxicity in Muara Tukad, Bali. Udayana University. Bali.
- Sianturi, I.T.; Kamlasi, Y.; Panuntun, M.F. and Oktovianto, H.A. (2022).** Organ Histopathology Goldfish Goldfish Gills and Hearts (*Cyprinus carpio*) Cultivator Seed Results in Batuplat, Kupang City, East Nusa Tenggara. In: *Proceedings of the National Research Seminar*, **5**(1).
- Silviany, V. (2004).** The Effect of Lead on the Morphology and Histology of Carp Livers (*Cyprinus Carpio*). Thesis. Biology Department. Faculty of Mathematics and Natural Sciences. Universitas Sriwijaya. Palembang.
- Sofiana, M.; Kadarsah, A. and Sofarini, D. (2022).** Quality Affected by Waste as an Indicator of Sustainable Development in Martapura Sub Watershed, Banjar Regency. *Jukung Journal of Environmental Engineering*, **8**(1). DOI: [org/10.20527/jukung.v8i1.12966](https://doi.org/10.20527/jukung.v8i1.12966)
- Sugiyono. (2014).** *Qualitative Quantitative Research Methods and R&D.* Alfabeta. Bandung.
- Sulistiyorinie, D.R.; Andayani, S. and Suprastyani, H. (2020).** The Effect of Crude Extract of Fire-Fire Leaves (*Avicennia marina*) on Histopathology of Koi Fish Liver (*Cyprinus carpio*) Infected with *Aeromonas hydrophilla* Bacteria. *JFMR (Journal of Fisheries and Marine Research)*, **4**(2): 263-273. DOI: [org/10.21776/ub.jfmr.2020.004.02.10](https://doi.org/10.21776/ub.jfmr.2020.004.02.10)
- Triadayani, A.D.; Aryawati, R. and Diansyah, G. (2010).** Effect of lead metal (pb) on liver

tissue of duck grouper (*Cromileptes altivelis*). Maspari Journal, **1**(1): 42 – 47.

**Wagiman, W.; Yusfiati, Y. and Elvyra, R. (2014).** The kidney structure of Selais fish (Ompokhypophthalmusbleeker, 1846) in the waters of the Siak River in Pekanbaru City. Student Online Journal (JOM) in the Field of Mathematics and Natural Sciences, **1**(2): 9.

**Wolf, J.C. and Wheeler, J.R. (2018).** A critical review of histopathological findings associated with endocrine and non-endocrine hepatic toxicity in fish models. *Aquatic Toxicology*, **197**: 60-78.

**Yohannes, B.Y.; Utomo, S.W. and Agustina, H. (2019).** River Water Quality Studies and Efforts Water Pollution Control. "IJEEM" Indonesian Journal of Environmental Education and Management, **4**(2): 136-155. DOI: [org/10.21009/ijeem.042.05](https://doi.org/10.21009/ijeem.042.05)

**Yudo, S. (2010).** The condition of the Ciliwung River Water Quality in the DKI Jakarta Region in terms of Organic Parameters, Ammonia, Phosphates, Detergents and Coli Bacteria. *Journal of Indonesian Aquaculture*, **6**: 34 - 42. DOI: [org/10.29122/jai.v6i1.2452](https://doi.org/10.29122/jai.v6i1.2452)

**Yuliasuti, E. (2011).** *Water Quality Study of Ngringo Karanganyar River in Efforts to Control Water Pollution*. Thesis. Diponegoro University Postgraduate Program, Semarang.

**Yulistia, E. (2020).** The Impact of Community Activities on the River Rim on Water Quality Ogan River in Baturaja City, OKU Regency. *Environmental Engineering Journal (UEEJ)*, **1**(1): 26-31. <https://www.journal.unbara.ac.id/index.php/UEEJ/article/view/735>

**Yulis, P.A.R. (2018).** Analysis of levels of mercury (Hg) and (Ph) in Kuantan River water affected by unlicensed gold mining (PETI). *Orbital: Journal of Chemistry Education*, **2**(1): 28-36. DOI: [org/10.19109/ojpk.v2i1.2167](https://doi.org/10.19109/ojpk.v2i1.2167)

\*\*\* **Indonesian National Standard.** (2009). 6989.3:2019 Water and Wastewater - Part 3: Method of Testing Total Suspended Solids (TSS) Gravimetrically. National Standardization Agency, Jakarta. [in Indonesian].

\*\*\* **Indonesian National Standard.** (2008). 6989.57: 2008 Water and Wastewater– Part 57: Surface Water Sampling Method. National Standardization Agency, Jakarta. [in Indonesian].

\*\*\* **Indonesian National Standard.** (2019). 6989.2:2019. Water and Wastewater – Part 73: How to test Chemical Oxygen Demand/COD with closed reflux by titrimetry. National Standardization Agency, Jakarta. [in Indonesian].

\*\*\* **Indonesian National Standard.** (2019). 6989.72:2009 Water and Wastewater – Part 72: Biochemical Oxygen Demand Test Method (BOD). National Standardization Agency, Jakarta. [in Indonesian].

\*\*\* **Republic of Indonesia Government.** (2021). Government Regulation of the Republic of Indonesia Number 22 of 2021: Implementation of Environmental Protection and Management of River Water Quality Standards, Government of the Republic of Indonesia, Jakarta. [in Indonesian].

\*\*\* **State Ministry of Environment.** (2003). Decree of the State minister for the Environment number No 115/2003 Appendix II: Guidelines for Determining Water Quality Status. State Ministry of Environment, Jakarta.

# Histopathology of Liver and Kidney of the River Catfish (Mystus nemurus) as a Bioindicator of Satui River Water Quality, South Kalimantan, Indonesia

## ORIGINALITY REPORT

12%

SIMILARITY INDEX

6%

INTERNET SOURCES

11%

PUBLICATIONS

1%

STUDENT PAPERS

## PRIMARY SOURCES

- 1** Yulia A. Kartika, Zaenal Akbar, Ariani Indrawati, Dadan R. Saleh, Haryono, Aris Yaman. "Revealing the Development of Fish Species Identification Process through An Ontology Mapping Approach", 2023 International Conference on Computer, Control, Informatics and its Applications (IC3INA), 2023  
Publication 1%
- 2** Ranwa A. Elrayess et al.. "Histopathology and Ultrastructure in Liver and Gonads of the Nile Tilapia (Oreochromis niloticus) as a Bio-Monitor for Water Quality Assessment in Lake Manzalah", Egyptian Journal of Aquatic Biology and Fisheries, 2022  
Publication 1%
- 3** docsdrive.com  
Internet Source <1%

4

Satria Bagus Nuringtyas, Rika Harini, Prima Widayani. "Study of water degradation due to community activities in The Lake Batur ecosystem, Bangli District, Bali", E3S Web of Conferences, 2023

Publication

<1 %

5

[scetcivil.weebly.com](http://scetcivil.weebly.com)

Internet Source

<1 %

6

Nuning Vita Hidayati, Ariani Dian Kartikaputri, Hernayanti Hernayanti, Arif Mahdiana. "Water Quality and Pollution Level in Plawangan Barat, Segara Anakan, Cilacap Based on Pollution Index Approach", Omni-Akuatika, 2023

Publication

<1 %

7

Bilal Hussain, Maleeha Fatima, Khalid Abdullah Al-Ghanim, Shahid Mahboob. "Environmentally induced Nephrotoxicity and histopathological alternations in Wallago attu and Cirrhinus mrigla", Saudi Journal of Biological Sciences, 2019

Publication

<1 %

8

Ahmed Y. H. Elwasify et al.. "Effect of bioaccumulation and biosedimentation of some heavy metals on histological features in the cichlid fish, Tilapia zillii inhabiting Lake Qarun, Egypt.", Egyptian Journal of Aquatic Biology and Fisheries, 2021

<1 %

9 [www.bioflux.com.ro](http://www.bioflux.com.ro) <1 %  
Internet Source

---

10 Asus Maizar Suryanto Hertika, Diana Arfiati, Evellin Dewi Lusiana, Renanda B.D.S. Putra. "Effect of environmental factors on hematology profile of *Gambusia affinis* caught at Brantas River watershed, Indonesia", F1000Research, 2021  
Publication

---

11 [www.kimiafarma.co.id](http://www.kimiafarma.co.id) <1 %  
Internet Source

---

12 Mustafa Öz, Orhan Yavuz, Ferhan Bolukbas. "Histopathology changes in the rainbow trout (*Onchorhyncus mykiss*) consuming boric acid supplemented fish fodder", Journal of Trace Elements in Medicine and Biology, 2020  
Publication

---

13 Submitted to Universitas Islam Indonesia <1 %  
Student Paper

---

14 [addi.ehu.es](http://addi.ehu.es) <1 %  
Internet Source

---

15 [talenta.usu.ac.id](http://talenta.usu.ac.id) <1 %  
Internet Source

---

16 [www.mdpi.com](http://www.mdpi.com) <1 %  
Internet Source

---



17

Nahla S. El-Shenawy, Heba N. Gad EL-Hak, Mahi A. Ghobashy, Farida A. Mansour, Maha F.M. Soliman. "Using antioxidant changes in liver and gonads of *Oreochromis niloticus* as biomarkers for the assessment of heavy metals pollution at Sharkia province, Egypt", *Regional Studies in Marine Science*, 2021

Publication

&lt;1 %

18

M A Adam, A Khumaidi, Ramli, Ernawati, I M Widiastuti, Y Risjani, A Soegianto. "Environmental Quality Identification of Wangi the River Polluted by Waste Based on the Environmental Pollution Index", *IOP Conference Series: Earth and Environmental Science*, 2022

Publication

&lt;1 %

19

"Fish Pathology", Wiley, 2012

Publication

&lt;1 %

20

Jori A. Bremer, Lisa A. Lobry de Bruyn, R. Geoff B. Smith, Wahyu Darsono, Tjeppey D. Soedjana, Frances C. Cowley. "Prospects and problems: considerations for smallholder cattle grazing in oil palm plantations in South Kalimantan, Indonesia", *Agroforestry Systems*, 2022

Publication

&lt;1 %

21

Arif Rohman, Adam Irwansyah Fauzi, Nesya Hafiza Ardani, Muhammad Ulin Nuha, Redho

&lt;1 %

Surya Perdana, Rian Nurtyawan, Aynaz Lotfata. "Monitoring Biochemical Oxygen Demand (BOD) Changes During a Massive Fish Kill Using Multitemporal Landsat-8 Satellite Images in Maninjau Lake, Indonesia", Forum Geografi, 2023

Publication

22

Submitted to Federal University of Technology

Student Paper

<1 %

23

Submitted to Massey University

Student Paper

<1 %

24

Nanik Retno Buwono, Yenny Risjani, Agoes Soegianto. "Distribution of microplastic in relation to water quality parameters in the Brantas River, East Java, Indonesia", Environmental Technology & Innovation, 2021

Publication

<1 %

25

[ijaeb.org](http://ijaeb.org)

Internet Source

<1 %

26

Ihya Sulthonuddin, Herdis Herdiansyah. "Sustainability of Batik wastewater quality management strategies: analytical hierarchy process", Applied Water Science, 2021

Publication

<1 %

27

Submitted to University of Johannesburg

Student Paper

<1 %

28

Internet Source

&lt;1 %

29

[ijariie.com](http://ijariie.com)

Internet Source

&lt;1 %

30

[www.mona.uwi.edu](http://www.mona.uwi.edu)

Internet Source

&lt;1 %

31

Hatice Dane, Turgay Şişman. "Histopathological changes in gill and liver of living in the Karasu River, Erzurum", *Environmental Toxicology*, 2015

Publication

&lt;1 %

32

Pitso, Khesa Mampho. "The Effect of Chronic Efavirenz Exposure on the Organ Health and Haematology of the Red-Strain Mozambique Tilapia *Oreochromis mossambicus*", University of Johannesburg (South Africa), 2021

Publication

&lt;1 %

33

Restu Juniah, Hisni Rahmi. "The influence of sand mining towards the sustainability of power support and capacity of Lambidaro River", AIP Publishing, 2017

Publication

&lt;1 %

34

[journal.tu.edu.ye](http://journal.tu.edu.ye)

Internet Source

&lt;1 %

35 Edi Rusdiyanto, Abdillah Munawir, Nurhasanah Nurhasanah, Imam Rozali Fathar, Jose Carlos Mierzwa. "Ozone Method Recycling Domestic Waste To Prevent Waste Water Pollution", Journal of Ecological Engineering, 2023  
Publication

---

36 Gatot Prayoga, Bagus Amalrullah Utomo, Hefni Effendi. "Heavy Metals Contamination and Water Quality Parameter Conditions in Jatiluhur Reservoir, West Java, Indonesia", BIOTROPIA, 2022  
Publication

---

37 Yuliati Yuliati, Eni Sumiarsih, Adriman Adriman, Efawani Efawani, Daniel Poima Saputra Napitupulu. "Water quality assesment of Pengambang River, Pekanbaru City, Riau Province, Indonesia using pollution index (PI)", BIO Web of Conferences, 2023  
Publication

---

38 [ejournal.undip.ac.id](http://ejournal.undip.ac.id)  
Internet Source

---

39 [ijoems.com](http://ijoems.com)  
Internet Source

---

40 [ouci.dntb.gov.ua](http://ouci.dntb.gov.ua)  
Internet Source

---

41

Internet Source

<1 %

42

Baadruzzoha Sarker, Bipresh Das, Shawon Chakraborty, Mohammad Amzad Hossain et al. "Optimization of 17 $\alpha$ -methyltestosterone dose to produce quality mono-sex Nile tilapia *Oreochromis niloticus*", Heliyon, 2022

Publication

<1 %

43

Patrick Amoatey, Mahad Said Baawain. "Effects of pollution on freshwater aquatic organisms", Water Environment Research, 2019

Publication

<1 %

44

[digitalcommons.usf.edu](https://digitalcommons.usf.edu)

Internet Source

<1 %

45

[dspace.plymouth.ac.uk](https://dspace.plymouth.ac.uk)

Internet Source

<1 %

46

[ejournals.epublishing.ekt.gr](https://ejournals.epublishing.ekt.gr)

Internet Source

<1 %

47

[irispublishers.com](https://irispublishers.com)

Internet Source

<1 %

48

[journal.unismuh.ac.id](https://journal.unismuh.ac.id)

Internet Source

<1 %

49

[journals.innovareacademics.in](https://journals.innovareacademics.in)

Internet Source

<1 %

50	<a href="http://journals.ums.ac.id">journals.ums.ac.id</a> Internet Source	<1 %
51	<a href="http://link.springer.com">link.springer.com</a> Internet Source	<1 %
52	<a href="http://repo-dosen.ulm.ac.id">repo-dosen.ulm.ac.id</a> Internet Source	<1 %
53	<a href="http://studentsrepo.um.edu.my">studentsrepo.um.edu.my</a> Internet Source	<1 %
54	Talkhan, Ola F. A., Safaa A. E. Abd Elwahab, and Ebtessam M. Shalapy. "Biochemical studies on the effect of different water resources in Hail region on liver and kidney functions of rats", Environmental Monitoring and Assessment, 2016. Publication	<1 %
55	Bilal Hussain, Hira Yaseen, Khalid-Al-Ghanim, F. Al-Misned, Muhammad Qasim, N. Al-Mulhm, Shahid Mahboob. "A study on risk assessment of effect of hematoxylin dye on cytotoxicity and nephrotoxicity in freshwater fish: Food and water security prospective research", Saudi Journal of Biological Sciences, 2021 Publication	<1 %
56	Susila Arita, Devi Kristianti, Leily Nurul Komariah. "Effectiveness of biomass-based fly	<1 %

ash in pulp and paper liquid waste treatment", South African Journal of Chemical Engineering, 2022

Publication

---

57

Y Martinus, W Astono, D Hendrawan. "Water quality study of Sunter River in Jakarta, Indonesia", IOP Conference Series: Earth and Environmental Science, 2018

Publication

---

<1 %

---

Exclude quotes Off

Exclude matches Off

Exclude bibliography On

# Histopathology of Liver and Kidney of the River Catfish (Mystus nemurus) as a Bioindicator of Satui River Water Quality, South Kalimantan, Indonesia

GRADEMARK REPORT

FINAL GRADE

GENERAL COMMENTS

**/0**

PAGE 1

PAGE 2

PAGE 3

PAGE 4

PAGE 5

PAGE 6

PAGE 7

PAGE 8

PAGE 9

PAGE 10

PAGE 11

PAGE 12

PAGE 13

PAGE 14

PAGE 15

PAGE 16

PAGE 17

PAGE 18

PAGE 19

PAGE 20



