

**Azerbaijan Medical Journal**  
Verify Mail  
To: irham.taufiqurrahman@ulm.ac.id

Inbox - ULM 2 May 2023 13:19

---

**Azerbaijan Medical Journal**

---

Sub: Verify Email Address

Dear **Irham**,

Please click the button below to verify your email address

[Verify Email Address](#)

If you're having trouble clicking the "Verify Email Address" button, copy and paste the URL below into your web browser:  
<https://www.azerbaijanmedicaljournal.com/author/verification-done/2/Dr/Irham/Taufiqurrahman/irham.taufiqurrahman@ulm.ac.id/Lambung%20Mangkurat%20University/department/Indonesia/Irham@999/default.png>

Thank you,  
Admin Board  
Azerbaijan Medical Journal

---

N.B: For Any Queries, Please mail to [support@azerbaijanmedicaljournal.com](mailto:support@azerbaijanmedicaljournal.com) and related documents mail to [admin@azerbaijanmedicaljournal.com](mailto:admin@azerbaijanmedicaljournal.com)

---

Azerbaijan Medical Journal, Azerbaijan © 2021 All rights reserved.  
Don't like these emails? [Unsubscribe](#).

**Azerbaijan Medical Journal**  
Thank you for your submission  
To: Irham Taufiqurrahman

Inbox - ULM 8 May 2023 17:01

---

**Azerbaijan Medical Journal**

---

Date: 08 May 2023  
Sub: Submission Succeeded  
Paper ID: **AMJ-08-05-2023-11469**

Dear **Dr Irham**,

Thank you for your submission into "Azerbaijan Medical Journal". Please use this paper ID: "AMJ-08-05-2023-11469" for your further inquiry for the publication. The paper will now go through peer review process and you will be notified within 7 working days about your submitted paper.

Thank you,  
Admin Board  
Azerbaijan Medical Journal

---

N.B: For Any Queries, Please mail to [support@azerbaijanmedicaljournal.com](mailto:support@azerbaijanmedicaljournal.com) and related documents mail to [admin@azerbaijanmedicaljournal.com](mailto:admin@azerbaijanmedicaljournal.com)

---

Azerbaijan Medical Journal, Azerbaijan © 2021 All rights reserved.  
Don't like these emails? [Unsubscribe](#).

**DASHBOARD**

SUBMISSION

- Submissions
- New Submit

Submission Guideline

Home Page

Irham

Show 10 entries Search:

#Sl#	Paper ID	OTP Code	Paper Title	Date	Status	Payment	Action
1	AMJ-08-05-2023-11469	Not Available	The Effect Of Binjal Leaves Extract Gel (Mangifera Caesia) And Ramania Leaves Extract Gel (Bouea Macrophylla Griffith) On The Number Of Fibroblast Cells In Incisional Wound Of Male Rats (Rattus Norvegicus)	08 May 2023	Pending	Wait for Approved	 



**Irham Taufiqurrahman**

Correspondence

To: support@azerbaijanmedicaljournal.com, admin@azerbaijanmedicaljournal.com

Sent - ULM 9 May 2023 16:57

Date: 9 May 2023

Title: The Effect Of Binjai Leaves Extract Gel (Mangifera Caesia) And Ramania Leaves Extract Gel (Bouea Macrophylla Griffith.) On The Number Of Fibroblast Cells In Incisional Wound Of Male Rats (Rattus Norvegicus)

Sub: Manuscript Submission

Paper ID: AMJ-08-05-2023-11469

Dear, **Admin Board Azerbaijan Medical Journal**

Thank you for responding to the submission of our manuscript to the "Azerbaijan Medical Journal". We have followed all the rules regarding the writing of manuscripts from this journal. We ask to directions and responses regarding writing from abstracts to bibliography.

Thank you,  
Dr Irham  
Corresponding author



**Azerbaijan Medical Journal**

Your paper has been revised

To: Irham Taufiqurrahman

Inbox - ULM 11 May 2023 20:32

## Azerbaijan Medical Journal

Date: 11 May 2023

Sub: Paper Revised

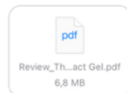Paper ID: **AMJ-08-05-2023-11469**

Dear Dr. **Irham**,

Thank you for Submitting your manuscript into **Azerbaijan Medical Journal**. We are Pleased and honored to inform you that your paper "**The Effect of Binjai Leaves Extract Gel (Mangifera Caesia) And Ramania Leaves Extract Gel (Bouea Macrophylla Griffith.) On The Number Of Fibroblast Cells In Incisional Wound Of Male Rats (Rattus Norvegicus)**" has been revised by our Editorial board.

If you have any query, Please do not hesitate to mail us. Please fill your paper ID in to the subject of the mail for further inquiry. We eagerly await your response.

Thank you,  
Admin Board  
Azerbaijan Medical Journal



**N.B:** For Any Queries, Please mail to

[support@azerbaijanmedicaljournal.com](mailto:support@azerbaijanmedicaljournal.com) and related documents mail to

[admin@azerbaijanmedicaljournal.com](mailto:admin@azerbaijanmedicaljournal.com)

# The Effect Of *Binjai* Leaves Extract Gel And *Ramania* Leaves Extract Gel On The Number Of Fibroblast Cells In Incisional Wound Of Male Rats

Azerbaijan Medical Journal  
the Latin name is included in the title

Irham Taufiqurrahman,<sup>1,2</sup> Isyana Erlita,<sup>3</sup> Rifka Amaliah,<sup>4</sup> Benje Kumala Dewi,<sup>5</sup> Andi Zulkifli,<sup>6</sup> Veni Hadju,<sup>6</sup>  
Eka Subardana<sup>7</sup>

<sup>1</sup> Doctoral Program, Faculty of Public Health, Hasanuddin University, Makassar, Indonesia,

<sup>2</sup> Departement of Oral and Maxillofacial Surgery, Faculty of Dental Medicine, Lambung Mangkurat University, Banjarmasin – Indonesia

<sup>3</sup> Departement of Conservative Dentistry, Faculty of Dentistry, Lambung Mangkurat University, Banjarmasin - Indonesia

<sup>4</sup> Faculty of Dentistry, Lambung Mangkurat University, Banjarmasin – Indonesia

<sup>5</sup> Departement of Pediatric Dentistry, Faculty of Dentistry, Lambung Mangkurat University, Banjarmasin - Indonesia

<sup>6</sup> Faculty of Public Health, Hasanuddin University, Makassar - Indonesia

<sup>7</sup> Departement of Medical Chemistry/Biochemistry, Faculty of Medicine, Lambung Mangkurat University, Banjarbaru, South Kalimantan - Indonesia

\*Corresponding author : [irham.taufiqurrahman@ulm.ac.id](mailto:irham.taufiqurrahman@ulm.ac.id)

**Abstract**— Wound is the discontinuity of tissue structure at epithelium layer. Wound healing process involves 3 phases, namely inflammation, proliferation, and remodeling. Fibroblast cell on proliferation phase play an important role in wound healing process. Fibroblast will achieve its peak on the 7<sup>th</sup> day and will decrease on the 14<sup>th</sup> days for collagen synthesis. *Binjai* leaves (*Mangifera coccia*) and *ramania* leaves (*Bouea macrophylla* Griffith.) contain secondary metabolites, one of them is flavonoid which can help wound healing process and affect the number of fibroblast cells. Objectives this research study is to prove the effect of 15% *binjai* leaves extract gel and 15% *ramania* leaves extract gel to the number of fibroblast cells on day 7 and 14 in incisional wound of male rats. A true experimental study with posttest-only control design was conducted. The sample using 18 male rats which is divided into 3 groups. Control group was given placebo gel, treatment group was given *binjai* leaves gel extract 15% and *ramania* leaves gel extract 15%. The result of two-way *Anova* showed that there are significant difference based on treatments ( $p < 0.05$ ) and based on days ( $p < 0.05$ ). Furthermore, it showed there was no interaction between treatments and days ( $p > 0.05$ ). Post-hoc Bonferroni test showed that there are significance difference ( $p < 0.05$ ). *Binjai* leaves gel extract and *ramania* leaves gel extract have an effect to the number of fibroblast on day 7<sup>th</sup> and 14<sup>th</sup>.

Azerbaijan Medical Journal  
Please describe the sample used

**Keywords**— *Binjai* leaves gel extract, *Ramania* leaves gel extract

Azerbaijan Medical Journal  
Minimum 3 keywords

## 1. Introduction

The wound is discontinuity of structure at epithelium layer of the skin.<sup>1</sup> The wound will be followed by wound healing process that consist of 3 phases<sup>2</sup>

During wound healing process, medications such as non-steroid anti-inflammatory drugs (NSAID) will be given to relieve pain and as an antiinflammation.<sup>3</sup> Administration of NSAID may have side effect such as gastric ulcer with anemia.<sup>4</sup> Based on that, people start to use traditional herbal medicine to minimize the side effect. Traditional herbal medicines that can be found in South Kalimantan are *binjai* (*Mangifera coccinea*) and *ramania* (*Bouea macrophylla* Griffith.)

*Binjai* and *ramania* contain secondary metabolites like alkaloids, triterpenoid, flavonoid, saponin, and tannin.<sup>5,6</sup> Flavonoid will work as antioxidant to balance the amount of reactive oxygen species (ROS).<sup>7</sup> Flavonoid can protect the body and support the wound healing process to achieve the proliferation of fibroblast for collagen synthesis.<sup>8,9</sup> Fibroblast begin to active 72 hours after wound occur, then it is increased on the 7<sup>th</sup> day to start collagen synthesis, and decrease on the 14<sup>th</sup> day in remodelling stage.<sup>10,11,12</sup>

*Binjai* extract and *ramania* extract can be made as topical gel formulation for faster absorption, better deliverance, and afford cool sensation on skin.<sup>13,14</sup>

## 2. Materials & method

The research process was started through the submission of ethical clearance that was later issued by Ethics Committee of Faculty of Dentistry, University of Lambung Mangkurat No. 075/KEPKG-FKGULM/EC/I/2020. The research method involved true experimental with posttest-only control group design. The sample used was 18 male *wistar* rat (*Rattus norvegicus*) with a body weight of 200-250 gram and 2-3 months old which was divided into 3 groups.

The making process of *binjai* leaves extract used maceration method. A total of 5 kilograms leaves were collected and washed in water. The leaves were dried then mashed up to obtain *simplicia* powder. It was macerated for 3 days in 70% ethanol. The result was filtered and concentrated using rotary evaporator at 50°C then it was evaporated using *waterbath* until it formed a thick ethanol extract. The extract was added with propylene glycol, tween 20, nipagin and *nipasol*, HPMC, and *aquades*.

The method process of *ramania* leaves extract started with the leaves washed in water, dried using oven at 50°C for 4 hours then mashed up to obtain *simplicia* powder. The *simplicia* powder was maceration in 95% ethanol. After 3 days, it was filtered and concentrated using rotary evaporator at 50°C then it was evaporated using *waterbath* until it formed a thick ethanol extract. The extract added with propylene glycol, tween 20, nipagin and *nipasol*, HPMC, and *aquades*.

The rats were adapted for a week while given regular feed and drink. The rats were anesthetized using a combination injection of ketamine-xylazine peritoneally. The back of rat was cleaned with 70% alcohol and shaved with a size of 3 cm. The wound was made using scalpel no. 15 until the depth of subcutaneous layer.

The topical application of extract gel was performed using cotton bud once daily for 14 days and was later wrapped with gauze. The rats on each group were sacrificed on the 7<sup>th</sup> day and the 14<sup>th</sup> day using the combination injection of ketamine (100 mg/kg)-xylazine (20 mg/kg). Afterward, excision for tissue extraction was conducted using scalpel and tissue scissors around 3 cm long and 3 cm width in a depth of subcutaneous layer. The corpse *were* put in a container and buried within 50 cm depth.

The tissue was fixed in 10% formalin solution, cut to the size of 1 cm length and packed in tissue cassette. Dehydration process was performed using tissue processing for ±18 hours and the tissue was later

Azerbaijan Medical Journal  
Describe what is meant by the 3 phases

Azerbaijan Medical Journal  
What type of dryer do you use?

Azerbaijan Medical Journal  
explain dosage

taken out. The tissue was transferred into base mold filled by paraffin liquid, then put in embedding cassette until it freeze. Paraffin block were cut off with a thickness of 5 microns. After that, the block was put on water bath, and later fixated on the object glass. Then the specimen was stained using Hematoxylin Eosin (HE). The preparations were observed using microscope with 40x10 magnifications in 5 observing fields.

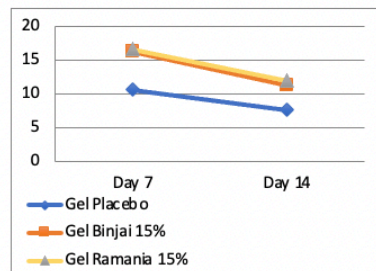
Statistical analysis used Shapiro-Wilk's normality test and Levene's homogeneity test. Afterward, Two-Way Anova with a confidence level of 95% was followed by Post-Hoc Bonferroni analysis to determine the value of significance.

### 3. Results

The mean value of fibroblast cells number in incisional wound healing on the back wound of rat in day 7<sup>th</sup> and day 14<sup>th</sup> is illustrated in Table 1 and Figure 1.

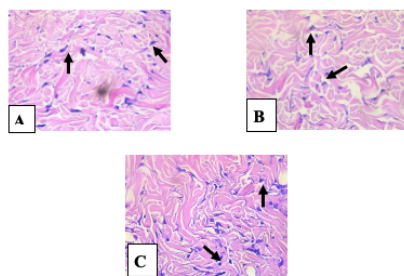
**Table 1.** Descriptive Result of Fibroblast Cells Number in Incisional Wound Healing of Rat

Treatment	Day Group	Mean	Standard Deviation
Placebo Gel	Day 7 <sup>th</sup>	10.67 (9-12 cells)	1.53
	Day 14 <sup>th</sup>	7.67 (7-8 cells)	0.58
15% Ramania Gel	Day 7 <sup>th</sup>	16.67 (15-18 cells)	1.16
	Day 14 <sup>th</sup>	12.00 (10-14 cells)	2.00
15% Binjai Gel	Day 7 <sup>th</sup>	16.33 (14-18 cells)	1.53
	Day 14 <sup>th</sup>	11.33 (9-13 cells)	2.08



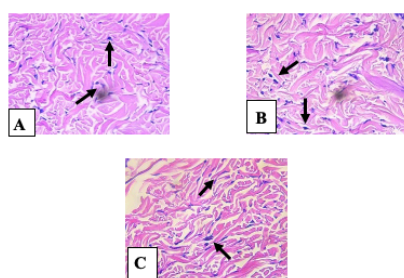
**Figure 1.** Mean of Fibroblast Cells in Incisional Wound Healing of Rat on Day 7<sup>th</sup> and Day 14<sup>th</sup>.

Figure 1 shows the mean of fibroblast cells in incisional back wound of rat in each group on day 7<sup>th</sup> and day 14<sup>th</sup>. The highest number of fibroblast cells on day 7<sup>th</sup> in order is 15% ramania leaves extract gel (16.67±1.16 cells), 15% binjai leaves gel extract (16.33±1.53 cells), and placebo gel (10.67±1.53 cells). On day 14<sup>th</sup>, mean number of fibroblast cells have decreased. The lowest number of fibroblast cells in order is placebo gel (7.67±0.58 cells), 15% binjai leaves extract gel (11.33±2.08 cells), and 15% ramania leaves extract gel (12.00±2.00 cell).



**Figure 2.** Histopathology of Fibroblast Cells in Incisional Back Wound Healing of Rat on Day 7<sup>th</sup>: (A) Placebo Gel Group, (B) 15% Binjai Leaves Gel Extract Group, (C) 15% Ramania Leaves Gel Extract Group

Figure 2 shows the histopathology of fibroblast cells number in incisional back wound of rat given placebo gel group with a total of 9-12 cells, binjai leaves extract gel at the concentration of 15% group with a total of 14-18 cells, and lastly ramania leaves extract gel at the concentration of 15% group with a total of 15-18 cells.



**Figure 3.** Histopathology of Fibroblast Cells in Incisional Back Wound Healing of Rat on Day 14<sup>th</sup>: (A) Placebo Gel Group, (B) 15% Binjai Leaves Gel Extract Group, (C) 15% Ramania Leaves Gel Extract Group

Figure 3 shows the histopathology of fibroblast cells number in incisional back wound of rat in placebo gel group with a total of 7-8 cells, binjai leaves extract gel at the concentration of 15% group with a total of 9-13 cells, and lastly ramania leaves extract gel at the concentration of 15% group with a total of 10-14 cells.

Result from statistical analysis shows the data was normally distributed ( $p > 0.05$ ) and the distribution of data was homogen ( $p > 0.05$ ). Two-way anova test was performed and shows that there is significant difference based on treatments ( $p < 0.05$ ) and based on days ( $p < 0.05$ ).

**Table 2.** Two-Way Anova Result Test

Source	Mean Square	Sig.
Treatment	48.722	.000
Day	80.222	.000
Treatment * Day	1.722	.514

Table 2 shows the result of Two-Way Anova Test ( $p < 0.05$ ). There was a significant difference based on treatments and based on days to the number of fibroblast cells. Meanwhile, the significance value in the interaction between treatment and day was greater than 0.05 which means that there was no significant difference between treatment and day to the number of fibroblast cells. Because there was a significant difference, data analysis was followed by Post-Hoc Bonferroni to find significant difference statistically.

**Table 3.** Post-Hoc Bonferroni Result Test Based on Treatment

Concentration (I)	Concentration (J)	Mean Difference (I-J)	Sig.
Placebo	15% Ramania	-0.517	0.000*
	15% Binjai	-0.467	0.001*
15% Ramania	Placebo	0.517	0.000*
	15% Binjai	0.050	1.000
15% Binjai	Placebo	0.467	0.001*
	15% Ramania	0.050	1.000

Table 3 shows the result that there is significant difference between placebo gel, binjai leaves extract gel at 15% concentration, ramania leaves extract gel at 15% concentration ( $p < 0.05$ ). Based on the table, there was no significant difference among binjai leaves extract gel at the concentration of 15% group and ramania leaves extract gel at the concentration of 15% group ( $p = 1.000$ ). Based on mean difference between placebo gel group and binjai leaves extract gel at the concentration of 15% group (0.467) and between the placebo gel group and ramania leaves extract at 15% concentration group (0.517), it is revealed that ramania leaves extract gel at the concentration of 15% has better effect compared to binjai leaves extract gel at the concentration of 15%. The result based on day show that there was significant difference

#### 4. Discussion

The result of this study proves that binjai (*Mangifera indica*) leaves extract gel and ramania (*Bouea macrophylla Griffith*) leaves extract gel was able to increase the number of fibroblast on day 7<sup>th</sup> and decrease the number of fibroblast on day 14<sup>th</sup>. Incisional wound in rat will be followed by wound healing process that consist of 3 phase, that is inflammation, proliferation, and remodeling.<sup>2</sup> Fibroblast cell can be found in connective tissue and play an important role to form extracellular matrix (ECM) for wound closure.<sup>15</sup>

Based on figure 1, it is shown the mean number of fibroblast cell on day 7<sup>th</sup> and day 14<sup>th</sup> displayed significant difference between placebo gel and treatment groups, such as binjai leaves extract gel at the concentration of 15% and ramania leaves gel extract at the concentration of 15%. This significant difference is due to the flavonoid contained in both leaves.

Flavonoid function as secondary antioxidant to balance the amount of oxidant and antioxidant through hydrogen donor for Nrf2 activation in order to increase the activation of endogen antioxidant, such as superoxidase dismutase (SOD), catalase (CAT), and glutathion peroxidase (GPX).<sup>16,17</sup> Flavonoid will protect

Azerbaijan Medical Journal explain the significant difference on how many days compared to how many days

Azerbaijan Medical Journal Writing the Latin name does not need to be repeated because it has been mentioned at the beginning

the body so that wound healing process can be proceed and promote the proliferation of fibroblast and collagen synthesis.<sup>7,8</sup> Moreover, flavonoid can work as immunomodulator. Based on research by Kurpija (2015), which used *Camellia sinensis*, flavonoid will support lymphocytes proliferation and interleukin-1 (IL-1) which will stimulate T-cell proliferation and differentiation into T-helper1 (Th1). Th1 will release interferon- $\gamma$  (IFN-  $\gamma$ ) for macrophage activation and produce growth factors to help fibroblast mitogenesis in proliferation phase. Flavonoid plays a role in forming granulation tissue, where fibroblast presents as the predominant cell. Flavonoid will support the increase insulin-like growth factor-1 (IGF-1) as a mediator of fibroblast proliferation. In addition to growth factors, flavonoid can produce cytokines, such as IL-1, IL-4, IL-8 to support fibroblast chemotaxis and keratinocytes.<sup>18,20</sup>

This study result based on figure 1 shows that there is a difference in the mean of fibroblast cell number on day 7<sup>th</sup>. *Ramania* leaves extract gel at the concentration of 15% group and *binjai* leaves extract gel at the concentration of 15% group shows better result compared to placebo gel group. Based on a research result by Sabirin (2013) that used *Morinda citrifolia* L. leaves extract in incisional wound of rat, it was obtained that the number of fibroblast cell on incisional wound of rat in day 7<sup>th</sup> have better result than to control group.

Seven days after wound formation, fibroblast number will achieve their peak and substitute the macrophage in inflammation phase.<sup>21</sup> Macrophage release growth factors which stimulate proliferation of fibroblast and generate extracellular matrix (ECM) formation.<sup>22</sup> Fibroblast with the help of matrix metalloproteinase (MMP) will seize the fibrin matrix and replace it with glycosaminoglycan (GAG). Extracellular matrix will be replaced by type III collagen which is also produced by fibroblast.<sup>1</sup> Type III collagen is commonly found for tissue repair and achieve its peak on the 5<sup>th</sup>-7<sup>th</sup> day after wound formation.<sup>22</sup>

Figure 1 shows that the mean of fibroblast cell on day 14<sup>th</sup> had decrease. Placebo gel group have number of fibroblast cell that is lower than *binjai* leaves extract gel at the concentration of 15% and *ramania* leaves extract gel at the concentration of 15%. According to a research by Isniardiana et al., (2019), which used *Clausena excavate* extract containing flavonoid in extraction wound of rat, it is contained that the number of fibroblast decreased on day 14<sup>th</sup> compared to day 7<sup>th</sup>. After the peak on day 7<sup>th</sup>, fibroblast will decrease because wound healing process goes well and fibroblast will be more progressive to synthesize the collagen in maturation phase. Another cause of decrease in the number of fibroblast cells is due to phenotype change of fibroblast into myofibroblast. Afterward, deposition of ECM will increase.<sup>12,15,22</sup>

Myofibroblast is derived from fibroblast which has similar characteristics like smooth muscle cells. Myofibroblast contains intracellular actin microfilament and endoplasmic reticulum tissue for matrix protein production. Myofibroblast helps the wound to contract and reconnect.<sup>23</sup>

## 5. Conclusion

Based on statistical result and discussion show that there is effect of *binjai* leaves extract gel at concentration of 15% and *ramania* leaves extract gel at concentration of 15% to the number of fibroblast cell in rat incisional back which will increased on day 7<sup>th</sup> and decrease on day 14<sup>th</sup>. Based on statistical result, *ramania* leaves (*Bouea macrophylla* Griffith.) extract gel at concentration of 15% have better result compared to *binjai* (*Mangifera caesia*) extract gel at concentration of 15% and placebo gel.

Azerbaijan Medical Journal

Can you describe what types of growth factors are involved?

Azerbaijan Medical Journal

add the theory about fibroblasts



## 6. Bibliography

- [1] Primadina N, Basori A, Perdanakusuma DS. 2019. Proses Penyembuhan Luka Ditinjau Dari Aspek Seluler dan Molekuler. *Qanun Medika*. 3 (1): 31-43.
- [2] Koraga JR, Leman MA, Siagian KV. 2015. Efektivitas Perasan Daun Pepaya Terhadap Jumlah Osteoblas Pasca Pencabutan Gigi pada Tikus Wistar Jantan. *PHARMACON*. 4 (4): 40-46.
- [3] Eirdauzi NA, Soemartono, Elidasari M. 2016. Pengaruh Pemberian Ibuprofen Preoperatif Terhadap Kepadatan Serabut Kolagen Pada Proses Penyembuhan Luka Pasca Ekstraksi denta Jurnal Kedokteran Gigi. 10 (1): 160-164.
- [4] Alviyon FM, Hermanto E, Widaningsih. 2016. Pengaruh Pemberian Ibuprofen Preoperatif Terhadap Sebaran Sel Badang Kronis Pada Proses Penyembuhan Luka Pasca Pencabutan Gigi. *denta Jurnal Kedokteran Gigi*. 10 (1): 55-61.
- [5] Ansari AA, Taufiqurrahman I, Dewi N. 2019. Flavonoid Level Test on Ethanol Extract of Binjai Leaf (*Mangifera caesia*). *Dentino*. 4 (1): 50-54.
- [6] Fitri L, Taufiqurrahman I, Irmamanda DH. 2018. Phytochemical And Cytotoxicity Testing of *Banania* Leaves (*Bauca Macrophylla Griffith*) Ethanol Extract Toward Vero Cells Using *Mit* Assay Method. *Dentino*. 3 (1): 51-56.
- [7] Arifin B dan Ibrahim S. 2018. Struktur, Bioktivitas dan Aktivitas Flavonoid. *Jurnal Zarah*. 6 (1): 21-29.
- [8] Simanjuntak K. 2012. Peran Antioksidan Flavonoid Dalam Meningkatkan Kesehatan. *Bina Widya*. 23 (3): 135-140.
- [9] Khairiah K, Taufiqurrahman I, Putri DKT. 2018. Antioxidant Activity Test of Ethyl Acetate Fraction of Binjai (*Mangifera caesia*) Leaf Ethanol Extract. *Majalah Kedokteran Gigi*. 51 (4): 164-168.
- [10] Fitri N. 2015. Penggunaan Krim Ekstrak Batang Dan Daun Suruhan (*Peperomia pellucida* L.H.B.K) Dalam Proses Penyembuhan Luka Bakar Pada Tikus Putih (*Rattus norvegicus*). *Biopendix*. 1 (2): 193-203.
- [11] Suharto IPS. 2016. Efek Pemberian Ekstrak Daging Buah Mahkota Dewa (*Phaleria marcocarpa*) Terhadap Jumlah Sel Fibroblas Luka Insisi Pada Tikus Putih (*Rattus norvegicus*). *Jurnal Keperawatan STIKES Hang Tuah Surabaya*. 10 (1): 973-982.
- [12] Rosanto YB, Handayani J, Susilowati H. 2012. Effect Giving Gum Gel Banana Plant Stem Against Density in Topical Collagen Fibers Wound Healing Process After Tooth Extraction Marmots. *Dentika Dent J*. 17: 34-39.
- [13] Ulfah M, Hendrarti W, Muhran PN. 2016. Formulasi Gel Ekstrak Daun Kelor (*Moringa oleifera* Lam.) Sebagai Anti Inflamasi Topikal Pada Tikus (*Rattus norvegicus*). *Journal of Pharmaceutical and Medicinal Sciences*. 1 (2): 30-35.

- [14] Hasanah U, Yusrjadi, Khumaidi A. 2017. Formulasi Gel Ekstrak Etanol Daun Kelor (*Moringa oleifera* Lam) Sebagai Antioksidan. *Online Journal of Natural Science*. 6 (1): 46-57.
- [15] Sumbayak EM. 2016. Fibroblas: Struktur dan Perannya dalam Penyembuhan Luka. *Jurnal Kedokteran Meditek*. 21 (57): 1-5.
- [16] Sumardika IW, Jawi IM. 2012. Ekstrak Air Daun Ubi Jalar Ungu Memerbaiki Profil Lipid dan Meningkatkan Kadar SOD Darah Tikus Yang diberi Makanan Tinggi Kolesterol. *Jurnal Unmah Kedokteran-MEDICINA*. 43 (2): 67-70.
- [17] Noora WF, Anriantia N, Saputra SR, Afifah B, Anriasari ML, Suhartono E. 2015. Oxidative Stress On Buccal Mucosa Wound In Rats and Role of Topical Application of Ethanolic Extract of Mauli Banana (*Musa acuminata* Stem). *The Journal of Tropical Life Science*. 5(2): 84-87.
- [18] Sabirin IPR, Maskoco AM, Hermowo BS. 2013. Peran Ekstrak Etanol Topikal Daun Mengkudu (*Morinda citrifolia* L.) pada Penyembuhan Luka Ditinjau dari Imunoekspresi CD34 dan Kolagen pada Tikus Galur Wistar. *MKB*. 45 (4): 226-233.
- [19] Kurnia PA, Ardiyanto HB, Subartini. 2015. Potensi Ekstrak Teh Hijau (*Camellia sinensis*) Terhadap Peningkatan Jumlah Sel Fibroblas Soket Pasca Pencabutan Gigi pada Tikus Wistar. *e-Jurnal Pustaka Kesehatan*. 3 (1): 122-127.
- [20] Fuadi MI, Eljab U, Misnawi. 2015. Jumlah Fibroblas pada Luka Bakar Derajat II pada Tikus dengan Pemberian Gel Ekstrak Etanol Biji Kakao dan Silver Sulfadiazine. *e-Jurnal Pustaka Kesehatan*. 3 (2): 244-248.
- [21] Ardiana T, Kusuma ARP, Firdausy MD. 2015. Efektivitas Pemberian Gel Binahong (*Anredera cordifolia*) 5% Terhadap Jumlah Sel Fibroblast pada Soket Pasca Pencabutan Gigi Marmut (*Cavia cobaya*). *Odonto*. 2 (1): 64-70.
- [22] Etika AN, Nurrahayu KI, Subato IPS. 2017. Pengaruh Ekstrak Jahe (*Zingiber Officinale* Roscoe) Terhadap Jumlah Sel Fibroblas pada Tikus (*Rattus norvegicus*). *Journal of Nursing Care & Biomolecular*. 2(1): 10-14.
- [23] Gonzalez ACDO, Andrade ZDA, Costa TF, Medrado ARAP. 2016. Wound Healing – A Literature Review. *An Bras Dermatol*. 91 (5): 614-620.
- [24] Ismardianita E, Widayawati, Ellanora D, Rosalina W, Nofrike L, Khairani VY. 2019. The Effectiveness Methanol Extract *Clausena* Excavate on Number of Fibroblast and Density of Collagen Fibers After Tooth Extraction. *Journal of Dentomaxillofacial Science*. 4 (3): 170-175.
- [25] Martin M. Physiology of Wound Healing. In Flanagan M, editor. 2013. Wound Healing and Skin Integrity Principles and Practice. p. 34, p.46. Wiley-Blackwell. United Kingdom.

Date: 12 May 2023

Title: The Effect Of Binjai Leaves Extract Gel (*Mangifera Caesia*) And Ramanian Leaves Extract Gel (*Bouea Macrophylla* Griffith.) On The Number Of Fibroblast Cells In Incisional Wound Of Male Rats (*Rattus Norvegicus*)

Sub: Manuscript Submission

Paper ID: AMJ-08-05-2023-11469

Dear, Admin Board Azerbaijan Medical Journal

We hereby send you an article that has been revised. Thank you very much for your attention! We are looking forward to hearing from you soon!

Thank you,  
Dr Irham  
Corresponding author



## The Effect Of Binjai Leaves Extract Gel (*Mangifera Caesia*) And Ramanian Leaves Extract Gel (*Bouea Macrophylla* Griffith.) On The Number Of Fibroblast Cells In Incisional Wound Of Male Rats (*Rattus Norvegicus*)

Irham Taufiqurrahman,<sup>1,2</sup> Isyana Erlita,<sup>3</sup> Rifka Amaliah,<sup>4</sup> Renie Kumala Dewi,<sup>5</sup> Andi Zulkifli,<sup>6</sup> Veni Hadju,<sup>6</sup> Eko Suhartono<sup>7</sup>

<sup>1</sup>Doctoral Program, Faculty of Public Health, Hasanuddin University, Makassar, Indonesia,

<sup>2</sup>Departement of Oral and Maxillofacial Surgery, Faculty of Dental Medicine, Lambung Mangkurat University, Banjarmasin – Indonesia

<sup>3</sup>Departement of Conservative Dentistry, Faculty of Dentistry, Lambung Mangkurat University, Banjarmasin - Indonesia

<sup>4</sup>Faculty of Dentistry, Lambung Mangkurat University, Banjarmasin – Indonesia

<sup>5</sup>Departement of Pediatric Dentistry, Faculty of Dentistry, Lambung Mangkurat University, Banjarmasin - Indonesia

<sup>6</sup>Faculty of Public Health, Hasanuddin University, Makassar - Indonesia

<sup>7</sup>Departement of Medical Chemistry/Biochemistry, Faculty of Medicine, Lambung Mangkurat University, Banjarbaru, South Kalimantan - Indonesia

\*Corresponding author : [irham.taufiqurrahman@ulm.ac.id](mailto:irham.taufiqurrahman@ulm.ac.id)

**Abstract**— Wound is the discontinuity of tissue structure at epithelium layer. Wound healing process involves 3 phases, namely inflammation, proliferation, and remodeling. Fibroblast cell on proliferation phase play an important role in wound healing process. Fibroblast will achieve its peak on the 7<sup>th</sup> day and will decrease on the 14<sup>th</sup> days for collagen synthesis. Binjai leaves (*Mangifera caesia*) and ramanian leaves (*Bouea macrophylla* Griffith.) contain secondary metabolites, one of them is flavonoid which can help wound healing process and affect the number of fibroblast cells. Objectives this research study is to prove the effect of 15% binjai leaves extract gel and 15% ramanian leaves extract gel to the number of fibroblast cells on day 7 and 14 in incisional wound of male rats. A true experimental study with posttest-only control design was conducted. The sample using 18 male rats (body weight 200-250 gram and 2-3 months old) which is divided into 3 groups. Control group was given placebo gel, treatment group was given binjai leaves gel extract 15% and ramanian leaves gel extract 15%. The result of two-way Anova showed that there are significant difference based on treatments ( $p < 0.05$ ) and based on days ( $p < 0.05$ ). Furthermore, it showed there was no interaction between treatments and days ( $p > 0.05$ ). Post-hoc Bonferroni test showed that there are significance difference ( $p < 0.05$ ). Binjai leaves gel extract and ramanian leaves gel extract have an effect to the number of fibroblast on day 7<sup>th</sup> and 14<sup>th</sup>.

**Keywords**— Binjai leaves gel extract, Ramanian leaves gel extract, number of fibroblast cell.

## 1. Introduction

The wound is discontinuity of structure at epithelium layer of the skin.<sup>1</sup> The wound will be followed by wound healing process that consist of 3 phases, called inflammation, proliferation, and remodelling.<sup>2</sup>

During wound healing process, medications such as non-steroid anti-inflammatory drugs (NSAID) will be given to relieve pain and as an antiinflammation.<sup>3</sup> Administration of NSAID may have side effect such as gastric ulcer with anemia.<sup>4</sup> Based on that, people start to use traditional herbal medicine to minimize the side effect. Traditional herbal medicines that can be found in South Kalimantan are binjai (*Mangifera caesia*) and ramania (*Bouea macrophylla* Griffith.)

Binjai and ramania contain secondary metabolites like alkaloids, triterpenoid, flavonoid, saponin, and tannin.<sup>5,6</sup> Flavonoid will work as antioxidant to balance the amount of reactive oxygen species (ROS).<sup>7</sup> Flavonoid can protect the body and support the wound healing process to achieve the proliferation of fibroblast for collagen synthesis.<sup>8,9</sup> Fibroblast begin to active 72 hours after wound occur, then it is increased on the 7<sup>th</sup> day to start collagen synthesis, and decrease on the 14<sup>th</sup> day in remodelling stage.<sup>10,11,12</sup>

Binjai extract and ramania extract can be made as topical gel formulation for faster absorption, better deliverance, and afford cool sensation on skin.<sup>13,14</sup>

## 2. Materials & method

The research process was started through the submission of ethical clearance that was later issued by Ethics Committee of Faculty of Dentistry, University of Lambung Mangkurat No. 075/KEPKG-FKGULM/EC/I/2020. The research method involved true experimental with posttest-only control group design. The sample used was 18 male wistar rat (*Rattus norvegicus*) with a body weight of 200-250 gram and 2-3 months old which was divided into 3 groups.

The making process of binjai leaves extract used maceration method. A total of 5 kilograms leaves were collected and washed in water. The leaves were dried in the open air then mashed up to obtain simplicia powder. It was macerated for 3 days in 70% ethanol. The result was filtered and concentrated using rotary evaporator at 50°C then it was evaporated using waterbath until it formed a thick ethanol extract. The extract was added with propylene glycol, tween 20, nipagin and nipasol, HPMC, and aquadest.

The method process of ramania leaves extract started with the leaves washed in water, dried using oven at 50°C for 4 hours then mashed up to obtain simplicia powder. The simplicia powder was maceration in 95% ethanol. After 3 days, it was filtered and concentrated using rotary evaporator at 50°C then it was evaporated using waterbath until it formed a thick ethanol extract. The extract added with propylene glycol, tween 20, nipagin and nipasol, HPMC, and aquadest.

The rats were adapted for a week while given regular feed and drink. The rats were anesthetized using a combination injection of ketamine (80 mg/kg)-xylazine (15 mg/kg) peritoneally. The back of rat was cleaned with 70% alcohol and shaved with a size of 3 cm. The wound was made using scalpel no. 15 until the depth of subcutaneous layer.

The topical application of extract gel was performed using cotton bud once daily for 14 days and was later wrapped with gauze. The rats on each group were sacrificed on the 7<sup>th</sup> day and the 14<sup>th</sup> day using the combination injection of ketamine (100 mg/kg)-xylazine (20 mg/kg). Afterward, excision for tissue extraction was conducted using scalpel and tissue scissors around 3 cm long and 3 cm width in a depth of subcutaneous layer. The corpse were put in a container and buried within 50 cm depth.

The tissue was fixed in 10% formalin solution, cut to the size of 1 cm length and packed in tissue cassette. Dehydration process was performed using tissue processing for ±18 hours and the tissue was later

taken out. The tissue was transferred into base mold filled by paraffin liquid, then put in embedding cassette until it freeze. Paraffin block were cut off with a thickness of 5 microns. After that, the block was put on waterbath and later fixated on the object glass. Then the specimen was stained using Haematoxylin Eosin (HE). The preparations were observed using microscope with 40x10 magnifications in 5 observing fields.

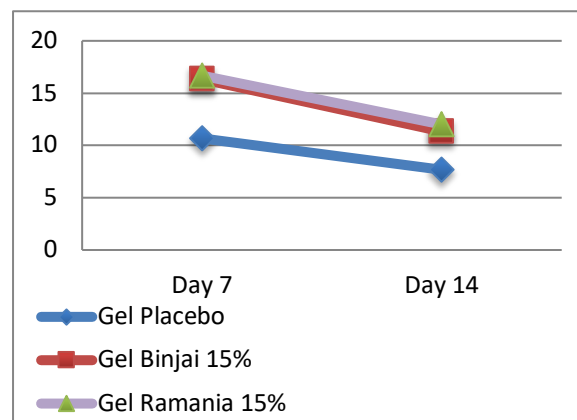
Statistical analysis used Shapiro-Wilk’s normality test and Levene’s homogeneity test. Afterward, Two-Way Anova with a confidence level of 95% was followed by Post-Hoc Bonferroni analysis to determine the value of significance.

### 3. Results

The mean value of fibroblast cells number in incisional wound healing on the back wound of rat in day 7<sup>th</sup> and day 14<sup>th</sup> is illustrated in Table 1 and Figure 1.

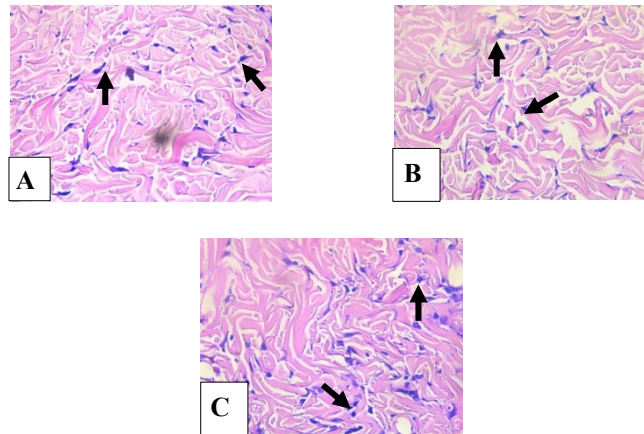
**Table 1.** Descriptive Result of Fibroblast Cells Number in Incisional Wound Healing of Rat

Treatment	Day Group	Mean	Standard Deviation
Placebo Gel	Day 7 <sup>th</sup>	10.67 (9-12 cells)	1.53
	Day 14 <sup>th</sup>	7.67 (7-8 cells)	0.58
15% Ramania Gel	Day 7 <sup>th</sup>	16.67 (15-18 cells)	1.16
	Day 14 <sup>th</sup>	12.00 (10-14 cells)	2.00
15% Binjai Gel	Day 7 <sup>th</sup>	16.33 (14-18 cells)	1.53
	Day 14 <sup>th</sup>	11.33 (9-13 cells)	2.08



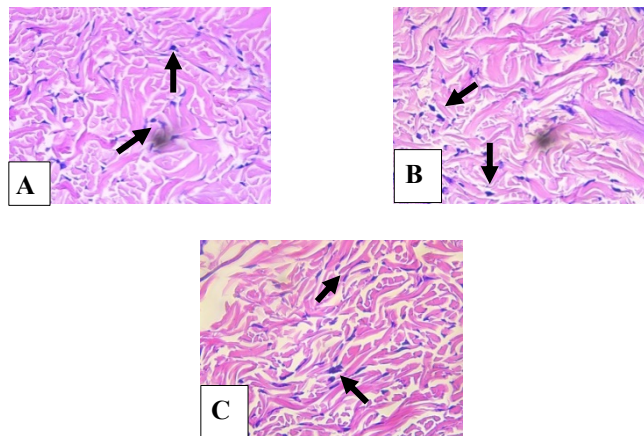
**Figure 1.** Mean of Fibroblast Cells in Incisional Wound Healing of Rat on Day 7<sup>th</sup> and Day 14<sup>th</sup>.

Figure 1 shows the mean of fibroblast cells in incisional back wound of rat in each group on day 7<sup>th</sup> and day 14<sup>th</sup>. The highest number of fibroblast cells on day 7<sup>th</sup> in order is 15% ramania leaves extract gel (16.67±1.16 cells), 15% binjai leaves gel extract (16.33±1.53 cells), and placebo gel (10.67±1.53 cells). On day 14<sup>th</sup>, mean number of fibroblast cells have decreased. The lowest number of fibroblast cells in order is placebo gel (7.67±0.58 cells), 15% binjai leaves extract gel (11.33±2.08 cells), and 15% ramania leaves extract gel (12.00±2.00 cell).



**Figure 2.** Histopathology of Fibroblast Cells in Incisional Back Wound Healing of Rat on Day 7<sup>th</sup>: (A) Placebo Gel Group, (B) 15% Binjai Leaves Gel Extract Group, (C) 15% Ramania Leaves Gel Extract Group

Figure 2 shows the histopathology of fibroblast cells number in incisional back wound of rat given placebo gel group with a total of 9-12 cells, binjai leaves extract gel at the concentration of 15% group with a total of 14-18 cells, and lastly ramania leaves extract gel at the concentration of 15% group with a total of 15-18 cells.



**Figure 3.** Histopathology of Fibroblast Cells in Incisional Back Wound Healing of Rat on Day 14<sup>th</sup>: (A) Placebo Gel Group, (B) 15% Binjai Leaves Gel Extract Group, (C) 15% Ramania Leaves Gel Extract Group

Figure 3 shows the histopathology of fibroblast cells number in incisional back wound of rat in placebo gel group with a total of 7-8 cells, binjai leaves extract gel at the concentration of 15% group with a total of 9-13 cells, and lastly ramania leaves extract gel at the concentration of 15% group with a total of 10-14 cells.

Result from statistical analysis shows the data was normally distributed ( $p > 0.05$ ) and the distribution of data was homogen ( $p > 0.05$ ). Two-way anova test was performed and shows that there is significant difference based on treatments ( $p < 0.05$ ) and based on days ( $p < 0.05$ ).

**Table 2.** Two-Way Anova Result Test

<i>Source</i>	<i>Mean Square</i>	<i>Sig.</i>
Treatment	48.722	.000
Day	80.222	.000
Treatment *	1.722	.514
Day		

Table 2 shows the result of Two-Way Anova Test ( $p < 0.05$ ). There was a significant difference based on treatments and based on days to the number of fibroblast cells. Meanwhile, the significance value in the interaction between treatment and day was greater than 0.05 which means that there was no significant difference between treatment and day to the number of fibroblast cells. Because there was a significant difference, data analysis was followed by Post-Hoc Bonferroni to find significant difference statistically.

**Table 3.** Post-Hoc Bonferroni Result Test Based on Treatment

<i>Concentration (I)</i>	<i>Concentration (J)</i>	<i>Mean Difference (I-J)</i>	<i>Sig.</i>
Placebo	15% Ramania	-0.517	0.000*
	15% Binjai	-0.467	0.001*
15% Ramania	Placebo	0.517	0.000*
	15% Binjai	0.050	1.000
15% Binjai	Placebo	0.467	0.001*
	15% Ramania	0.050	1.000

Table 3 shows the result that there is significant difference between placebo gel, binjai leaves extract gel at 15% concentration, ramania leaves extract gel at 15% concentration ( $p < 0.05$ ). Based on the table, there was no significant difference among binjai leaves extract gel at the concentration of 15% group and ramania leaves extract gel at the concentration of 15% group ( $p = 1.000$ ). Based on mean difference between placebo gel group and binjai leaves extract gel at the concentration of 15% group (0.467) and between the placebo gel group and ramania leaves extract at 15% concentration group (0.517), it is revealed that ramania leaves extract gel at the concentration of 15% has better effect compared to binjai leaves extract gel at the concentration of 15%. The result based on day show that there was significant difference between day 7<sup>th</sup> and day 14<sup>th</sup>.

#### 4. Discussion

The result of this study proves that binjai leaves extract gel and ramania leaves extract gel was able to increase the number of fibroblast on day 7<sup>th</sup> and decrease the number of fibroblast on day 14<sup>th</sup>. Incisional wound in rat will be followed by wound healing process that consist of 3 phase, that is inflammation, proliferation, and remodeling.<sup>2</sup> Fibroblast cell can be found in connective tissue and play an important role to form extracellular matrix (ECM) for wound closure.<sup>15</sup>

Based on figure 1, it is shown the mean number of fibroblast cell on day 7<sup>th</sup> and day 14<sup>th</sup> displayed significant difference between placebo gel and treatment groups, such as binjai leaves extract gel at the concentration of 15% and ramania leaves gel extract at the concentration of 15%. This significant difference is due to the flavonoid contained in both leaves.

Flavonoid function as secondary antioxidant to balance the amount of oxidant and antioxidant through hydrogen donor for Nrf2 activation in order to increase the activation of endogen antioxidant, such as superoxidase dismutase (SOD), catalase (CAT), and glutathion peroxidase (GPX).<sup>16,17</sup> Flavonoid will protect

the body so that wound healing process can be proceed and promote the proliferation of fibroblast and collagen synthesis.<sup>7,8</sup> Moreover, flavonoid can work as immunomodulator. Based on research by Kurnia (2015), which used *Camellia sinensis*, flavonoid will support lymphocytes proliferation and interleukin-1 (IL-1) which will stimulate T-cell proliferation and differentiation into T-helper1 (Th1). Th1 will release interferon- $\gamma$  (IFN-  $\gamma$ ) for macrophage activation and produce growth factors to help fibroblast mitogenesis in proliferation phase. Flavonoid plays a role in forming granulation tissue, where fibroblast presents as the predominant cell. Flavonoid will support the increase insulin-like growth factor-1 (IGF-1) as a mediator of fibroblast proliferation. In addition to growth factors, flavonoid can produce cytokines, such as IL-1, IL-4, IL-8 to support fibroblast chemotaxis and keratinocytes.<sup>18,20</sup>

This study result based on figure 1 shows that there is a difference in the mean of fibroblast cell number on day 7<sup>th</sup>. Ramania leaves extract gel at the concentration of 15% group and binjai leaves extract gel at the concentration of 15% group shows better result compared to placebo gel group. Based on a reseach result by Sabirin (2013) that used *Morinda citrifolia* L. leaves extract in incisional wound of rat, it was obtained that the number of fibroblast cell on incisional wound of rat in day 7<sup>th</sup> have better result than to control group.

Seven days after wound formation, fibroblast number will achieve their peak and substitute the macrophage in inflammation phase.<sup>21</sup> Macrophage release *growth factors*, such as platelet derived growth factor (PDGF), fibroblast growth factor (FGF), endothelial growth factor (EGF), transforming growth factor- $\alpha$  (TGF- $\alpha$ ), and TGF- $\beta$ , which stimulate proliferation of fibroblast and generate extracellular matrix (ECM) formation.<sup>22</sup> Fibroblast with the help of matrix metalloproteinase (MMP) will seize the fibrin matrix and replace it with glycosaminoglycan (GAG). Extracellular matrix will be replaced by type III collagen which is also produced by fibroblast.<sup>1</sup> Type III collagen is commonly found for tissue repair and achieve its peak on the 5<sup>th</sup>-7<sup>th</sup> day after wound formation.<sup>22</sup>

Figure 1 shows that the mean of fibroblast cell on day 14<sup>th</sup> had decrease. Placebo gel group have number of fibroblast cell that is lower than binjai leaves extract gel at the concentration of 15% and ramania leaves extract gel at the concentration of 15%. According to a research by Ismiardianita et al., (2019), which used *Clausena excavate* extract containing flavonoid in extraction wound of rat, it is contained that the number of fibroblast decreased on day 14<sup>th</sup> compared to day 7<sup>th</sup>. After the peak on day 7<sup>th</sup>, fibroblast will decrease because wound healing process goes well and fibroblast will be more progressive to synthesize the collagen in maturation phase. Another cause of decrease in the number of fibroblast cells is due to phenotype change of fibroblast into myofibroblast. Afterward, deposition of ECM will increase.<sup>12,15,22</sup>

Myofibroblast is derived from fibroblast which has similar characteristics like smooth muscle cells. Myofibroblast contains intracellular actin microfilament and endoplasmic reticulum tissue for matrix protein production. Myofibroblast helps the wound to contract and reconnect.<sup>23</sup> Myofibroblasts are connected by cell-to-cell and cell-to-matrix and express  $\alpha$ -Smooth Muscle Action ( $\alpha$ -SMA) through repetitive contraction in order to produce collagen fibers in the injury area. <sup>1,22,25</sup> At this stage, type III collagen will be replaced by type I collagen which have band shape and have stronger tensile strength and density in new tissue.<sup>24</sup> Only around 80% tensile strength will be recovered due to collagen fibers ability that can only retrieve 80% of its normal strength before injury.<sup>1</sup>

## 5. Conclusion

Based on statistical result and discussion show that there is effect of binjai leaves extract gel at concentration of 15% and ramania leaves extract gel at concentration of 15% to the number of fibroblast cell in rat incisional back which will increased on day 7<sup>th</sup> and decrease on day 14<sup>th</sup>. Based on statistical result, ramania leaves (*Bouea microphylla* Griffith.) extract gel at concentration of 15% have better result compared to binjai (*Mangifera caesia*) extract gel at concentration of 15% and placebo gel.



## 6. References

- [1] Primadina N, Basori A, Perdanakusuma DS. 2019. Proses Penyembuhan Luka Ditinjau Dari Aspek Seluler dan Molekuler. *Qanum Medika*. 3 (1): 31-43.
- [2] Koraag JR, Leman MA, Siagian KV. 2015. Efektivitas Perasan Daun Papaya Terhadap Jumlah Osteoblas Pasca Pencabutan Gigi pada Tikus Wistar Jantan. *PHARMACON*. 4 (4): 40-46.
- [3] Firdauzi NA, Soemartono, Elidasari M. 2016. Pengaruh Pemberian Ibuprofen Preoperatif Terhadap Kepadatan Serabut Kolagen Pada Proses Penyembuhan Luka Pasca Ekstraksi. *denta Jurnal Kedokteran Gigi*. 10 (1): 160-164.
- [4] Alviony FM, Hermanto E, Widaningsih. 2016. Pengaruh Pemberian Ibuprofen Preoperatif Terhadap Sebaran Sel Radang Kronis Pada Proses Penyembuhan Luka Pasca Pencabutan Gigi. *denta Jurnal Kedokteran Gigi*. 10 (1): 55-61.
- [5] Ansari AA, Taufiqurrahman I, Dewi N. 2019. Flavonoid Level Test on Ethanol Extract of Binjai Leaf (*Mangifera caesia*). *Dentino*. 4 (1): 50-54.
- [6] Fitri L, Taufiqurrahman I, Imamanda DH. 2018. Phytochemical And Cytotoxicity Testing of Ramania Leaves (*Bouea Macrophylla Griffith*) Ethanol Extract Toward Vero Cells Using Mtt Assay Method. *Dentino*. 3 (1): 51-56.
- [7] Arifin B dan Ibrahim S. 2018. Struktur, Bioktivitas dan Aktivitas Flavonoid. *Jurnal Zarah*. 6 (1): 21-29.
- [8] Simanjuntak K. 2012. Peran Antioksidan Flavonoid Dalam Meningkatkan Kesehatan. *Bina Widya*. 23 (3): 135-140.
- [9] Khairiah K, Taufiqurrahman I, Putri DKT. 2018. Antioxidant Activity Test of Ethyl Acetate Fraction of Binjai (*Mangifera caesia*) Leaf Ethanol Extract. *Majalah Kedokteran Gigi*. 51 (4): 164-168.
- [10] Fitri N. 2015. Penggunaan Krim Ekstrak Batang Dan Daun Suruhan (*Peperomia pellucida L.H.B.K*) Dalam Proses Penyembuhan Luka Bakar Pada Tikus Putih (*Rattus norvegicus*). *Biopendix*. 1 (2): 193-203.
- [11] Suharto IPS. 2016. Efek Pemberian Ekstrak Daging Buah Mahkota Dewa (*Phaleria marcocarpa*) Terhadap Jumlah Sel Fibroblas Luka Insisi Pada Tikus Putih (*Rattus norvegicus*). *Jurnal Keperawatan STIKES Hang Tuah Surabaya*. 10 (1): 973-982.
- [12] Rosanto YB, Handajani J, Susilowati H. 2012. Effect Giving Gum Gel Banana Plant Stem Against Density in Topical Collagen Fibers Wound Healing Process After Tooth Extraction Marmots. *Dentika Dent J*. 17: 34-39.
- [13] Ulfa M, Hendrarti W, Muhram PN. 2016. Formulasi Gel Ekstrak Daun Kelor (*Moringa oleifera Lam.*) Sebagai Anti Inflamasi Topikal Pada Tikus (*Rattus novergicus*). *Journal of Pharmaceutical and Medicinal Sciences*. 1 (2): 30-35.

- [14] Hasanah U, Yusriadi, Khumaidi A. 2017. Formulasi Gel Ekstrak Etanol Daun Kelor (*Moringa oleifera* Lam) Sebagai Antioksidan. *Online Journal of Natural Science*. 6 (1): 46-57.
- [15] Sumbayak EM. 2016. Fibroblas: Struktur dan Peranannya dalam Penyembuhan Luka. *Jurnal Kedokteran Meditek*. 21 (57): 1-5.
- [16] Sumardika IW, Jawi IM. 2012. Ekstrak Air Daun Ubi Jalar Ungu Memperbaiki Profil Lipid dan Meningkatkan Kadar SOD Darah Tikus Yang diberi Makanan Tinggi Kolesterol. *Jurnal Ilmiah Kedokteran MEDICINA*. 43 (2): 67-70.
- [17] Noora WF, Apriantia N, Saputra SR, Afifah B, Apriasari ML, Suhartono E. 2015. Oxidative Stress On Buccal Mucosa Wound In Rats and Rule of Topical Application of Ethanolic Extract of Mauli Banana (*Musa acuminata*) Stem. *The Journal of Tropical Life Science*. 5(2): 84-87.
- [18] Sabirin IPR, Maskoen AM, Hernowo BS. 2013. Peran Ekstrak Etanol Topikal Daun Mengkudu (*Morinda citrifolia* L.) pada Penyembuhan Luka Ditinjau dari Imunoekspresi CD34 dan Kolagen pada Tikus Galur Wistar. *MKB*. 45 (4): 226-233.
- [19] Kurnia PA, Ardhiyanto HB, Suhartini. 2015. Potensi Ekstrak Teh Hijau (*Camellia sinensis*) Terhadap Peningkatan Jumlah Sel Fibroblas Soket Pasca Pencabutan Gigi pada Tikus Wistar. *e-Jurnal Pustaka Kesehatan*. 3 (1): 122-127.
- [20] Fuadi MI, Elfiah U, Misnawi. 2015. Jumlah Fibroblas pada Luka Bakar Derajat II pada Tikus dengan Pemberian Gel Ekstrak Etanol Biji Kakao dan Silver Sulfadiazine. *e-Jurnal Pustaka Kesehatan*. 3 (2): 244-248.
- [21] Ardiana T, Kusuma ARP, Firdausy MD. 2015. Efektivitas Pemberian Gel Binahong (*Anredera cordifolia*) 5% Terhadap Jumlah Sel Fibroblast pada Soket Pasca Pencabutan Gigi Marmut (*Cavia cobaya*). *Odonto*. 2 (1): 64-70.
- [22] Etika AN, Nurrahayu KI, Suhato IPS. 2017. Pengaruh Ekstrak Jahe (*Zingiber Officinale* Roscoe) Terhadap Jumlah Sel Fibroblas pada Tikus (*Rattus norvegicus*). *Journal of Nursing Care & Biomolecular*. 2(1): 10-14.
- [23] Gonzalez ACDO, Andrade ZDA, Costa TF, Medrado ARAP. 2016. Wound Healing – A Literature Review. *An Bras Dermatol*. 91 (5): 614-620.
- [24] Ismardianita E, Widyawati, Ellanora D, Rosalina W, Nofrike L, Khairani VY. 2019. The Effectiveness Methanol Extract Clausena Excavate on Number of Fibroblast and Density of Collagen Fibers After Tooth Extraction. *Journal of Dentomaxillofacial Science*. 4 (3): 170-175.
- [25] Martin M. *Physiology of Wound Healing*. In Flanagan M, editor. 2013. *Wound Healing and Skin Integrity Principles and Practice*. p. 34, p.46. Wiley-Blackwell. United Kingdom.



**Azerbaijan Medical Journal**

Your paper has been accepted

To: Irham Taufiqurrahman

Inbox - ULM 15 May 2023 20.32

## Azerbaijan Medical Journal

Date: 15 May 2023  
Sub: Paper Accepted  
Paper ID: **AMJ-08-05-2023-11469**

Dear Dr. **Irham**,

Thank you for Submitting your manuscript into **Azerbaijan Medical Journal**. We are Pleased and honored to inform you that your paper "**The Effect Of Binjal Leaves Extract Gel (Mangifera Caesia) And Ramania Leaves Extract Gel (Bouea Macrophylla Griffith.) On The Number Of Fibroblast Cells In Incisional Wound Of Male Rats (Rattus Norvegicus)**" has been accepted by our Editorial board for the next issue of Azerbaijan Medical Journal.

The current condition of the paper is fully ok and need no further edit for the publications. The editor is really pleased to see this kind of paper and the research applications. In order to proceed for publication, kindly send the Application process charge of the publication within 7 days and submit the completed copyright Agreement paper into your Author Dashboard or through the mail. you can submit it as soon as your payment is done.

If you have any query, Please do not hesitate to mail us. Please fill your paper ID in to the subject of the mail for further inquiry. We eagerly await your response.

Thank you,  
Admin Board  
Azerbaijan Medical Journal

**N.B:** For Any Queries, Please mail to

[support@azerbaijanmedicaljournal.com](mailto:support@azerbaijanmedicaljournal.com) and related documents mail to

[admin@azerbaijanmedicaljournal.com](mailto:admin@azerbaijanmedicaljournal.com)

Azerbaijan Medical Journal, Azerbaijan © 2021 All rights reserved.



**Azerbaijan Medical Journal**

Your payment has been successful!

To: Irham Taufiqurrahman

Inbox - ULM 15 May 2023 23.02

## Azerbaijan Medical Journal

Date: 15 May 2023  
Sub: Your payment has been successful!  
Paper ID: **AMJ-08-05-2023-11469**

Dear Dr. **Dear Irham**,  
Your payment has been successfully done!

**Paper ID: AMJ-08-05-2023-11469**

Thank you,  
Admin Board  
Azerbaijan Medical Journal

**N.B:** For Any Queries, Please mail to

[support@azerbaijanmedicaljournal.com](mailto:support@azerbaijanmedicaljournal.com) and related documents mail to

[admin@azerbaijanmedicaljournal.com](mailto:admin@azerbaijanmedicaljournal.com)

Azerbaijan Medical Journal, Azerbaijan © 2021 All rights reserved.  
Don't like these emails? [Unsubscribe](#).

# Azerbaijan Medical Journal

## Copyright Transfer Agreement

Paper id: AMJ-08-05-2023-11469

**Title of the manuscript:** The Effect Of Binjai Leaves Extract Gel (Mangifera Caesia) And Ramania Leaves Extract Gel (Bouea Macrophylla Griffith.) On The Number Of Fibroblast Cells In Incisional Wound Of Male Rats (Rattus Norvegicus)

**Journal Name**  
Azerbaijan Medical Journal

**Type of Manuscript: (Research/Review):** Research

**Author(s) name(s) :** Irham Taufiqurrahman, Isyana Erlita, Rifka Amaliah, Renie Kumala Dewi, Andi Zulkifli, Veni Hadju, Eko Suhartono

**Corresponding Author's name, address, affiliation and e-mail:** Irham Taufiqurrahman, Faculty of Dentistry Lambung Mangkurat University, [irham.taufiqurrahman@ulm.ac.id](mailto:irham.taufiqurrahman@ulm.ac.id)

The transfer of copyright gives **Azerbaijan Medical Journal** the right to develop, promote, distribute, sell, and archive a body of scientific works throughout the world. The Author hereby grants and assigns to **AMJ** all rights in and to Author's work in and contributions to the Work. In connection with this assignment, the Author acknowledges that **AMJ** will have the right to print, publish, create derivative works, and sell the Work throughout the world, all rights in and to all revisions or versions or subsequent editions of the Work in all languages and media throughout the world. The author(s), reserve the following rights:

All proprietary rights other than copyrights, such as patent rights,  
The right to use all or part of this article, including tables and figures in the future works of their own, provided that the proper acknowledgment is made to the Publisher as copyright holder, and

The right to make copies of this article for his/her own use, but not for sale

I warrant and represent that the work does not violate any proprietary or personal rights of others (including, without limitation, any copyrights or privacy rights); that the Work is factually accurate and contains no matter libelous or otherwise unlawful; that I have substantially participated in the creation of the Work and that it represents my original work sufficient for me to claim authorship. I further warrant and represent that I have no financial interest in the subject matter of the Work or any affiliation with an organization or entity with a financial interest in the subject matter of the Work, other than as previously disclosed to the Association.

I have the consent of each author to transfer and assign any and all right, title, and interest, including copyright of the article referenced above. I hereby assign and transfer to the **AMJ copyright** and all rights under it. I further confirm that this article has not been published elsewhere, nor is it under consideration by any other publisher.

Signature:



Date: 16 May 2023



## Azerbaijan Medical Journal

Date: 31 May 2023  
 Sub: Congratulations! Your Paper has been Published  
 Paper ID: **AMJ-08-05-2023-11469**

**Note:** Your paper will be automatically updated in scopus by 30 September,2023. authors don't need to do anything as we ourselves will upload papers manually.

Dear Dr. **Irham**,

We are very pleased to inform you that your paper "**The Effect Of Binjai Leaves Extract Gel (Mangifera Caesia) And Ramania Leaves Extract Gel (Bouea Macrophylla Griffith.) On The Number Of Fibroblast Cells In Incisional Wound Of Male Rats (Rattus Norvegicus)**" has been successfully gone through for all procedure to the publication in "**Azerbaijan Medical Journal**". Your paper has been published and now you can see it and refer it for your further research.

For preventing data breach from aimbot and third party we have secured your data. You will need an access key to see and download your paper. you can see your access key in your Author dashboard. Please share this with your co-authors so that they can also download.

We hope you to publish with your near future.

Thank you,  
 Admin Board  
 Azerbaijan Medical Journal

**N.B:** For Any Queries, Please mail to

[support@azerbaijanmedicaljournal.com](mailto:support@azerbaijanmedicaljournal.com) and related documents mail to [admin@azerbaijanmedicaljournal.com](mailto:admin@azerbaijanmedicaljournal.com)

**DASHBOARD**

**SUBMISSION**

- Submissions
- New Submit

[Submission Guideline](#)

[Home Page](#)

Irham

Show 10 entries

Search:

#Sl#	Paper ID	OTP Code	Paper Title	Date	Status	Payment	Action
1	AMJ-08-05-2023-11469	AMJ14971711469	The Effect Of Binjai Leaves Extract Gel (Mangifera Caesia) And Ramania Leaves Extract Gel (Bouea Macrophylla Griffith.) On The Number Of Fibroblast Cells In Incisional Wound Of Male Rats (Rattus Norvegicus)	08 May 2023	Published	<span>Paid</span>	

# The Effect Of Binjai Leaves Extract Gel (*Mangifera Caesia*) And Ramania Leaves Extract Gel (*Bouea Macrophylla Griffith.*) On The Number Of Fibroblast Cells In Incisional Wound Of Male Rats (*Rattus Norvegicus*)

Irham Taufiqurrahman<sup>1,2\*</sup>, Isyana Erlita<sup>3</sup>, Rifka Amaliah<sup>4</sup>, Renie Kumala Dewi<sup>5</sup>, Andi Zulkifli<sup>6</sup>, Veni Hadju<sup>6</sup>, Eko Suhartono<sup>7</sup>

Doctoral Program, Faculty of Public Health, Hasanuddin University, Makassar, Indonesia<sup>1</sup>  
Departement of Oral and Maxillofacial Surgery, Faculty of Dental Medicine, Lambung Mangkurat University, Banjarmasin – Indonesia<sup>2</sup>  
Department of Conservative Dentistry, Faculty of Dentistry, Lambung Mangkurat University, Banjarmasin – Indonesia<sup>3</sup>  
Faculty of Dentistry, Lambung Mangkurat University, Banjarmasin – Indonesia<sup>4</sup>  
Departement of Pediatric Dentistry, Faculty of Dentistry, Lambung Mangkurat University, Banjarmasin – Indonesia<sup>5</sup>  
Faculty of Public Health, Hasanuddin University, Makassar – Indonesia<sup>6</sup>  
Departement of Medical Chemistry/Biochemistry, Faculty of Medicine, Lambung Mangkurat University, Banjarbaru, South Kalimantan – Indonesia<sup>7</sup>

Corresponding Author: 1,2\*



---

## Keywords:

Binjai leaves gel extract, Ramania leaves gel extract, number of fibroblast cell.

---

## ABSTRACT

Wound is the discontinuity of tissue structure at epithelium layer. Wound healing process involves 3 phases, namely inflammation, proliferation, and remodeling. Fibroblast cell on proliferation phase play an important role in wound healing process. Fibroblast will achieve its peak on the 7<sup>th</sup> day and will decrease on the 14<sup>th</sup> days for collagen synthesis. Binjai leaves (*Mangifera caesia*) and ramania leaves (*Bouea macrophylla Griffith.*) contain secondary metabolites, one of them is flavonoid which can help wound healing process and affect the number of fibroblast cells. Objectives this research study is to prove the effect of 15% binjai leaves extract gel and 15% ramania leaves extract gel to the number of fibroblast cells on day 7 and 14 in incisional wound of male rats. A true experimental study with posttest-only control design was conducted. The sample using 18 male rats (body weight 200-250 gram and 2-3 months old) which is divided into 3 groups. Control group was given placebo gel, treatment group was given binjai leaves gel extract 15% and ramania leaves gel extract 15%. The result of two-way Anova showed that there are significant difference based on treatments ( $p < 0.05$ ) and based on days ( $p < 0.05$ ). Furthermore, it showed there was no interaction between treatments and days ( $p > 0.05$ ). Post-hoc Bonferroni test showed that there are significance difference ( $p < 0.05$ ). Binjai leaves

gel extract and ramania leaves gel extract have an effect to the number of fibroblast on day 7<sup>th</sup> and 14<sup>th</sup>.



This work is licensed under a Creative Commons Attribution Non-Commercial 4.0 International License.

## 1. Introduction

The wound is discontinuity of structure at epithelium layer of the skin [1]. The wound will be followed by wound healing process that consist of 3 phases, called inflammation, proliferation, and remodelling [2].

During wound healing process, medications such as non-steroid anti-inflammatory drugs (NSAID) will be given to relieve pain and as an antiinflammation [3]. Administration of NSAID may have side effect such as gastric ulcer with anemia [4]. Based on that, people start to use traditional herbal medicine to minimize the side effect. Traditional herbal medicines that can be found in South Kalimantan are binjai (*Mangifera caesia*) and ramania (*Bouea macrophylla* Griffith.)

Binjai and ramania contain secondary metabolites like alkaloids, triterpenoid, flavonoid, saponin, and tannin [5], [6]. Flavonoid will work as antioxidant to balance the amount of reactive oxygen species (ROS) [7]. Flavonoid can protect the body and support the wound healing process to achieve the proliferation of fibroblast for collagen synthesis [8], [9]. Fibroblast begin to active 72 hours after wound occur, then it is increased on the 7<sup>th</sup> day to start collagen synthesis, and decrease on the 14<sup>th</sup> day in remodelling stage [10-12].

Binjai extract and ramania extract can be made as topical gel formulation for faster absorption, better deliverance, and afford cool sensation on skin [13], [14].

## 2. Materials & method

The research process was started through the submission of ethical clearance that was later issued by Ethics Committee of Faculty of Dentistry, University of Lambung Mangkurat No. 075/KEPKG-FKGULM/EC/I/2020. The research method involved true experimental with posttest-only control group design. The sample used was 18 male wistar rat (*Rattus norvegicus*) with a body weight of 200-250 gram and 2-3 months old which was divided into 3 groups.

The making process of binjai leaves extract used maceration method. A total of 5 kilograms leaves were collected and washed in water. The leaves were dried in the open air then mashed up to obtain simplicia powder. It was macerated for 3 days in 70% ethanol. The result was filtered and concentrated using rotary evaporator at 50°C then it was evaporated using waterbath until it formed a thick ethanol extract. The extract was added with propylene glycol, tween 20, nipagin and nipasol, HPMC, and aquadest.

The method process of ramania leaves extract started with the leaves washed in water, dried using oven at 50°C for 4 hours then mashed up to obtain simplicia powder. The simplicia powder was maceration in 95% ethanol. After 3 days, it was filtered and concentrated using rotary evaporator at 50°C then it was evaporated using waterbath until it formed a thick ethanol extract. The extract added with propylene glycol, tween 20, nipagin and nipasol, HPMC, and aquadest.

The rats were adapted for a week while given regular feed and drink. The rats were anesthetized using a combination injection of ketamine (80 mg/kg)-xylazine (15 mg/kg) peritoneally. The back of rat was cleaned with 70% alcohol and shaved with a size of 3 cm. The wound was made using scalpel no. 15 until the depth of subcutaneous layer.

The topical application of extract gel was performed using cotton bud once daily for 14 days and was later wrapped with gauze. The rats on each group were sacrificed on the 7<sup>th</sup> day and the 14<sup>th</sup> day using the combination injection of ketamine (100 mg/kg)-xylazine (20 mg/kg). Afterward, excision for tissue extraction was conducted using scalpel and tissue scissors around 3 cm long and 3 cm width in a depth of subcutaneous layer. The corpse were put in a container and buried within 50 cm depth.

The tissue was fixed in 10% formalin solution, cut to the size of 1 cm length and packed in tissue cassette. Dehydration process was performed using tissue processing for ±18 hours and the tissue was later taken out. The tissue was transferred into base mold filled by paraffin liquid, then put in embedding cassette until it freeze. Paraffin block were cut off with a thickness of 5 microns. After that, the block was put on waterbath and later fixated on the object glass. Then the specimen was stained using Haematoxylin Eosin (HE). The preparations were observed using microscope with 40x10 magnifications in 5 observing fields.

Statistical analysis used Shapiro-Wilk's normality test and Levene's homogeneity test. Afterward, Two-Way Anova with a confidence level of 95% was followed by Post-Hoc Bonferroni analysis to determine the value of significance.

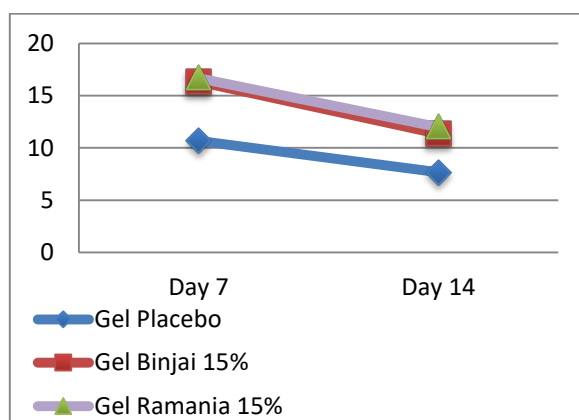
### 3. Results

The mean value of fibroblast cells number in incisional wound healing on the back wound of rat in day 7<sup>th</sup> and day 14<sup>th</sup> is illustrated in Table 1 and Figure 1.

**Table 1.** Descriptive Result of Fibroblast Cells Number in Incisional Wound Healing of Rat

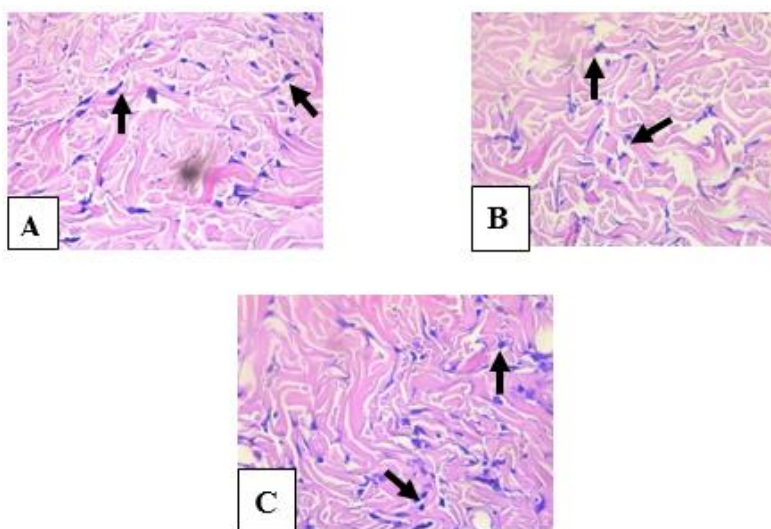
Treatment	Day Group	Mean	Standard Deviation
Placebo Gel	Day 7 <sup>th</sup>	10.67 (9-12 cells)	1.53
	Day 14 <sup>th</sup>	7.67 (7-8 cells)	0.58
15% Ramania Gel	Day 7 <sup>th</sup>	16.67 (15-18 cells)	1.16
	Day 14 <sup>th</sup>	12.00 (10-14 cells)	2.00
15% Binjai Gel	Day 7 <sup>th</sup>	16.33 (14-18 cells)	1.53
	Day 14 <sup>th</sup>	11.33 (9-13 cells)	2.08





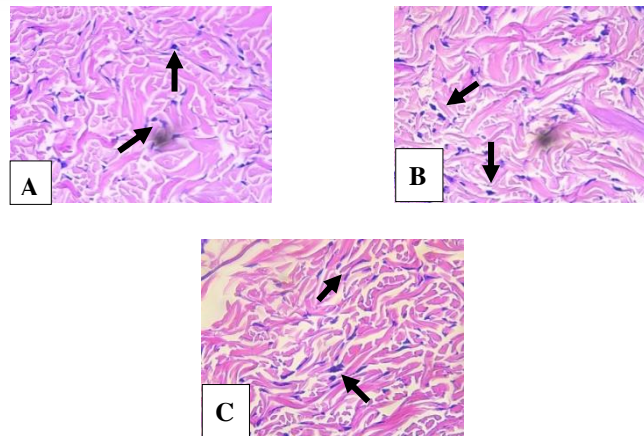
**Figure 1.** Mean of Fibroblast Cells in Incisional Wound Healing of Rat on Day 7<sup>th</sup> and Day 14<sup>th</sup>.

Figure 1 shows the mean of fibroblast cells in incisional back wound of rat in each group on day 7<sup>th</sup> and day 14<sup>th</sup>. The highest number of fibroblast cells on day 7<sup>th</sup> in order is 15% rmania leaves extract gel (16.67±1.16 cells), 15% binjai leaves gel extract (16.33±1.53 cells), and placebo gel (10.67±1.53 cells). On day 14<sup>th</sup>, mean number of fibroblast cells have decreased. The lowest number of fibroblast cells in order is placebo gel (7.67±0.58 cells), 15% binjai leaves extract gel (11.33±2.08 cells), and 15% rmania leaves extract gel (12.00±2.00 cell).



**Figure 2.** Histopathology of Fibroblast Cells in Incisional Back Wound Healing of Rat on Day 7<sup>th</sup>: (A) Placebo Gel Group, (B) 15% Binjai Leaves Gel Extract Group, (C) 15% Rmania Leaves Gel Extract Group

Figure 2 shows the histopathology of fibroblast cells number in incisional back wound of rat given placebo gel group with a total of 9-12 cells, binjai leaves extract gel at the concentration of 15% group with a total of 14-18 cells, and lastly rmania leaves extract gel at the concentration of 15% group with a total of 15-18 cells.



**Figure 3.** Histopathology of Fibroblast Cells in Incisional Back Wound Healing of Rat on Day 14<sup>th</sup>: (A) Placebo Gel Group, (B) 15% Binjai Leaves Gel Extract Group, (C) 15% Ramania Leaves Gel Extract Group

Figure 3 shows the histopathology of fibroblast cells number in incisional back wound of rat in placebo gel group with a total of 7-8 cells, binjai leaves extract gel at the concentration of 15% group with a total of 9-13 cells, and lastly ramania leaves extract gel at the concentration of 15% group with a total of 10-14 cells.

Result from statistical analysis shows the data was normally distributed ( $p > 0.05$ ) and the distribution of data was homogen ( $p > 0.05$ ). Two-way anova test was performed and shows that there is significant difference based on treatments ( $p < 0.05$ ) and based on days ( $p < 0.05$ ).

**Table 2.** Two-Way Anova Result Test

<i>Source</i>	<i>Mean Square</i>	<i>Sig.</i>
Treatment	48.722	.000
Day	80.222	.000
Treatment * Day	1.722	.514

Table 2 shows the result of Two-Way Anova Test ( $p < 0.05$ ). There was a significant difference based on treatments and based on days to the number of fibroblast cells. Meanwhile, the significance value in the interaction between treatment and day was greater than 0.05 which means that there was no significant difference between treatment and day to the number of fibroblast cells. Because there was a significant difference, data analysis was followed by Post-Hoc Bonferroni to find significant difference statistically.

**Table 3.** Post-Hoc Bonferroni Result Test Based on Treatment

<i>Concentration (I)</i>	<i>Concentration (J)</i>	<i>Mean Difference (I-J)</i>	<i>Sig.</i>
Placebo	15% Ramania	-0.517	0.000*
	15% Binjai	-0.467	0.001*
15% Ramania	Placebo	0.517	0.000*
	15% Binjai	0.050	1.000
15% Binjai	Placebo	0.467	0.001*
	15% Ramania	0.050	1.000

Table 3 shows the result that there is significant difference between placebo gel, binjai leaves extract gel at 15% concentration, ramania leaves extract gel at 15% concentration ( $p < 0.05$ ). Based on the table, there was no significant difference among binjai leaves extract gel at the concentration of 15% group and ramania leaves extract gel at the concentration of 15% group ( $p = 1.000$ ). Based on mean difference between placebo gel group and binjai leaves extract gel at the concentration of 15% group (0.467) and between the placebo gel group and ramania leaves extract at 15% concentration group (0.517), it is revealed that ramania leaves extract gel at the concentration of 15% has better effect compared to binjai leaves extract gel at the concentration of 15%. The result based on day show that there was significant difference between day 7<sup>th</sup> and day 14<sup>th</sup>.

#### 4. Discussion

The result of this study proves that binjai leaves extract gel and ramania leaves extract gel was able to increase the number of fibroblast on day 7<sup>th</sup> and decrease the number of fibroblast on day 14<sup>th</sup>. Incisional wound in rat will be followed by wound healing process that consist of 3 phase, that is inflammation, proliferation, and remodeling [2] Fibroblast cell can be found in connective tissue and play an important role to form extracellular matrix (ECM) for wound closure [15].

Based on figure 1, it is shown the mean number of fibroblast cell on day 7<sup>th</sup> and day 14<sup>th</sup> displayed significant difference between placebo gel and treatment groups, such as binjai leaves extract gel at the concentration of 15% and ramania leaves gel extract at the concentration of 15%. This significant difference is due to the flavonoid contained in both leaves.

Flavonoid function as secondary antioxidant to balance the amount of oxidant and antioxidant through hydrogen donor for Nrf2 activation in order to increase the activation of endogen antioxidant, such as superoxidase dismutase (SOD), catalase (CAT), and glutathion peroxidase (GPX) [16], [17]. Flavonoid will protect the body so that wound healing process can be proceed and promote the proliferation of fibroblast and collagen synthesis [7], [8]. Moreover, flavonoid can work as immunomodulator. Based on research by [19], which used *Camellia sinensis*, flavonoid will support lymphocytes proliferation and interleukin-1 (IL-1) which will stimulate T-cell proliferation and differentiation into T-helper1 (Th1). Th1 will release interferon- $\gamma$  (IFN- $\gamma$ ) for macrophage activation and produce growth factors to help fibroblast mitogenesis in proliferation phase. Flavonoid plays a role in forming granulation tissue, where fibroblast presents as the predominant cell. Flavonoid will support the increase insulin-like growth factor-1 (IGF-1) as a mediator of fibroblast proliferation. In addition to growth factors, flavonoid can produce cytokines, such as IL-1, IL-4, IL-8 to support fibroblast chemotaxis and keratinocytes [18], [20].

This study result based on figure 1 shows that there is a difference in the mean of fibroblast cell number on day 7<sup>th</sup>. Ramania leaves extract gel at the concentration of 15% group and binjai leaves extract gel at the concentration of 15% group shows better result compared to placebo gel group. Based on a reseach result by [18] that used *Morinda citrifolia* L. leaves extract in incisional wound of rat, it was obtained that the number of fibroblast cell on incisional wound of rat in day 7<sup>th</sup> have better result than to control group.

Seven days after wound formation, fibroblast number will achieve their peak and substitute the macrophage in inflammation phase [21]. Macrophage release *growth factors*, such as platelet derived growth factor (PDGF), fibroblast growth factor (FGF), endothelial growth factor (EGF), transforming growth factor- $\alpha$  (TGF- $\alpha$ ), and TGF- $\beta$ , which stimulate proliferation of fibroblast and generate extracellular matrix (ECM) formation [22]. Fibroblast with the help of matrix metalloproteinase (MMP) will seize the fibrin matrix and replace it with glycosaminoglycan (GAG). Extracellular matrix will be replaced by type III collagen which

is also produced by fibroblast [1]. Type III collagen is commonly found for tissue repair and achieve its peak on the 5<sup>th</sup>-7<sup>th</sup> day after wound formation [22].

Figure 1 shows that the mean of fibroblast cell on day 14<sup>th</sup> had decrease. Placebo gel group have number of fibroblast cell that is lower than binjai leaves extract gel at the concentration of 15% and ramania leaves extract gel at the concentration of 15%. According to a research by [24], which used *Clausena excavate* extract containing flavonoid in extraction wound of rat, it is contained that the number of fibroblast decreased on day 14<sup>th</sup> compared to day 7<sup>th</sup>. After the peak on day 7<sup>th</sup>, fibroblast will decrease because wound healing process goes well and fibroblast will be more progressive to synthesize the collagen in maturation phase. Another cause of decrease in the number of fibroblast cells is due to phenotype change of fibroblast into myofibroblast. Afterward, deposition of ECM will increase [12], [15], [22].

Myofibroblast is derived from fibroblast which has similar characteristics like smooth muscle cells. Myofibroblast contains intracellular actin microfilament and endoplasmic reticulum tissue for matrix protein production. Myofibroblast helps the wound to contract and reconnect [23]. Myofibroblasts are connected by cell-to-cell and cell-to-matrix and express  $\alpha$ -Smooth Muscle Action ( $\alpha$ -SMA) through repetitive contraction in order to produce collagen fibers in the injury area [1], [22], [25]. At this stage, type III collagen will be replaced by type I collagen which have band shape and have stronger tensile strength and density in new tissue [24]. Only around 80% tensile strength will be recovered due to collagen fibers ability that can only retrieve 80% of its normal strength before injury [1].

## 5. Conclusion

Based on statistical result and discussion show that there is effect of binjai leaves extract gel at concentration of 15% and ramania leaves extract gel at concentration of 15% to the number of fibroblast cell in rat incisional back which will increased on day 7<sup>th</sup> and decrease on day 14<sup>th</sup>. Based on statistical result, ramania leaves (*Bouea microphylla* Griffith.) extract gel at concentration of 15% have better result compared to binjai (*Mangifera caesia*) extract gel at concentration of 15% and placebo gel.

## 6. References

- [1] Primadina N, Basori A, Perdanakusuma DS. 2019. Proses Penyembuhan Luka Ditinjau Dari Aspek Seluler dan Molekuler. *Qanum Medika*. 3 (1): 31-43.
- [2] Koraag JR, Leman MA, Siagian KV. 2015. Efektivitas Perasan Daun Papaya Terhadap Jumlah Osteoblas Pasca Pencabutan Gigi pada Tikus Wistar Jantan. *PHARMACON*. 4 (4): 40-46.
- [3] Firdauzi NA, Soemartono, Elidasari M. 2016. Pengaruh Pemberian Ibuprofen Preoperatif Terhadap Kepadatan Serabut Kolagen Pada Proses Penyembuhan Luka Pasca Ekstraksi. *denta Jurnal Kedokteran Gigi*. 10 (1): 160-164.
- [4] Alviony FM, Hermanto E, Widaningsih. 2016. Pengaruh Pemberian Ibuprofen Preoperatif Terhadap Sebaran Sel Radang Kronis Pada Proses Penyembuhan Luka Pasca Pencabutan Gigi. *denta Jurnal Kedokteran Gigi*. 10 (1): 55-61.
- [5] Ansari AA, Taufiqurrahman I, Dewi N. 2019. Flavonoid Level Test on Ethanol Extract of Binjai Leaf (*Mangifera caesia*). *Dentino*. 4 (1): 50-54.
- [6] Fitri L, Taufiqurrahman I, Irnamanda DH. 2018. Phytochemical And Cytotoxicity Testing of

Ramania Leaves (*Bouea Macrophylla* Griffith) Ethanol Extract Toward Vero Cells Using Mtt Assay Method. *Dentino*. 3 (1): 51-56.

[7] Arifin B dan Ibrahim S. 2018. Struktur, Bioktivitas dan Aktivitas Flavonoid. *Jurnal Zarah*. 6 (1): 21-29.

[8] Simanjuntak K. 2012. Peran Antioksidan Flavonoid Dalam Meningkatkan Kesehatan. *Bina Widya*. 23 (3): 135-140.

[9] Khairiah K, Taufiqurrahman I, Putri DKT. 2018. Antioxidant Activity Test of Ethyl Acetate Fraction of Binjai (*Mangifera caesia*) Leaf Ethanol Extract. *Majalah Kedokteran Gigi*. 51 (4): 164-168.

[10] Fitri N. 2015. Penggunaan Krim Ekstrak Batang Dan Daun Suruhan (*Peperomia pellucida* L.H.B.K) Dalam Proses Penyembuhan Luka Bakar Pada Tikus Putih (*Rattus norvegicus*). *Biopendix*. 1 (2): 193-203.

[11] Suharto IPS. 2016. Efek Pemberian Ekstrak Daging Buah Mahkota Dewa (*Phaleria marcocarpa*) Terhadap Jumlah Sel Fibroblas Luka Insisi Pada Tikus Putih (*Rattus norvegicus*). *Jurnal Keperawatan STIKES Hang Tuah Surabaya*. 10 (1): 973-982.

[12] Rosanto YB, Handajani J, Susilowati H. 2012. Effect Giving Gum Gel Banana Plant Stem Against Density in Topical Collagen Fibers Wound Healing Process After Tooth Extraction Marmots. *Dentika Dent J*. 17: 34-39.

[13] Ulfa M, Hendrarti W, Muhram PN. 2016. Formulasi Gel Ekstrak Daun Kelor (*Moringa oleifera* Lam.) Sebagai Anti Inflamasi Topikal Pada Tikus (*Rattus novergicus*). *Journal of Pharmaceutical and Medicinal Sciences*. 1 (2): 30-35.

[14] Hasanah U, Yusriadi, Khumaidi A. 2017. Formulasi Gel Ekstrak Etanol Daun Kelor (*Moringa oleifera* Lam) Sebagai Antioksidan. *Online Journal of Natural Science*. 6 (1): 46-57.

[15] Sumbayak EM. 2016. Fibroblas: Struktur dan Peranannya dalam Penyembuhan Luka. *Jurnal Kedokteran Meditek*. 21 (57): 1-5.

[16] Sumardika IW, Jawi IM. 2012. Ekstrak Air Daun Ubi Jalar Ungu Memperbaiki Profil Lipid dan Meningkatkan Kadar SOD Darah Tikus Yang diberi Makanan Tinggi Kolesterol. *Jurnal Ilmiah Kedokteran MEDICINA*. 43 (2): 67-70.

[17] Noora WF, Apriantia N, Saputra SR, Afifah B, Apriasari ML, Suhartono E. 2015. Oxidative Stress On Buccal Mucosa Wound In Rats and Rule of Topical Application of Ethanolic Extract of Mauli Banana (*Musa acuminata*) Stem. *The Journal of Tropical Life Science*. 5(2): 84-87.

[18] Sabirin IPR, Maskoen AM, Hernowo BS. 2013. Peran Ekstrak Etanol Topikal Daun Mengkudu (*Morinda citrifolia* L.) pada Penyembuhan Luka Ditinjau dari Imunoekspresi CD34 dan Kolagen pada Tikus Galur Wistar. *MKB*. 45 (4): 226-233.

[19] Kurnia PA, Ardhiyanto HB, Suhartini. 2015. Potensi Ekstrak Teh Hijau (*Camellia sinensis*) Terhadap Peningkatan Jumlah Sel Fibroblas Soket Pasca Pencabutan Gigi pada Tikus Wistar. *e-Jurnal*

Pustaka Kesehatan. 3 (1): 122-127.

[20] Fuadi MI, Elfiah U, Misnawi. 2015. Jumlah Fibroblas pada Luka Bakar Derajat II pada Tikus dengan Pemberian Gel Ekstrak Etanol Biji Kakao dan Silver Sulfadiazine. e-Jurnal Pustaka Kesehatan. 3 (2): 244-248.

[21] Ardiana T, Kusuma ARP, Firdausy MD. 2015. Efektivitas Pemberian Gel Binahong (*Anredera cordifolia*) 5% Terhadap Jumlah Sel Fibroblast pada Soket Pasca Pencabutan Gigi Marmut (*Cavia cobaya*). Odonto. 2 (1): 64-70.

[22] Etika AN, Nurrahayu KI, Suhato IPS. 2017. Pengaruh Ekstrak Jahe (*Zingiber Officinale Roscoe*) Terhadap Jumlah Sel Fibroblas pada Tikus (*Rattus norvegicus*). Journal of Nursing Care & Biomolecular. 2(1): 10-14.

[23] Gonzalez ACDO, Andrade ZDA, Costa TF, Medrado ARAP. 2016. Wound Healing – A Literature Review. An Bras Dermatol. 91 (5): 614-620.

[24] Ismardianita E, Widyawati, Ellanora D, Rosalina W, Nofrike L, Khairani VY. 2019. The Effectiveness Methanol Extract *Clausena Excavate* on Number of Fibroblast and Density of Collagen Fibers After Tooth Extraction. Journal of Dentomaxillofacial Science. 4 (3): 170-175.

[25] Martin M. Physiology of Wound Healing. In Flanagan M, editor. 2013. Wound Healing and Skin Integrity Principles and Practice. p. 34, p.46. Wiley-Blackwell. United Kingdom.