

THE EFFECT OF MAULI BANANA STEM EXTRACT GEL (*Musa acuminata*) APPLICATION IN CONCENTRATION OF 37.5% ON EPITHELIAL THICKNESS

by Irham Taufiqurrahman

Submission date: 13-Jun-2023 02:12PM (UTC+0700)

Submission ID: 2115083955

File name: 16._Jurnal_Nasional_6166-13617-1-SM.pdf (552.49K)

Word count: 3337

Character count: 17214

**THE EFFECT OF MAULI BANANA STEM EXTRACT GEL (*Musa acuminata*)
APPLICATION IN CONCENTRATION OF 37.5% ON EPITHELIAL THICKNESS
(Research report)**

Monica Thiodora Limay¹, Maharani Laillyza Apriasari², Irham Taufiqurrahman³

INTRODUCTION

Injury is a state of tissue damage or loss that can be caused by physical action. The body is physiologically able to repair its own tissue damage which is known as wound healing.^{1,2} The injury is considered to be healed when the signs of inflammation have disappeared and the surface of

the damaged tissue can be re-closed normally.^{3,4} One of the most common treatments used to enhance mucosal injury healing in the field of dentistry is by the use of patent drugs containing aloe vera extract.

There are some traditional plants which can be used in wound healing, for example the use of

mauli banana extract gel.^{2,5} According to Apriasari et al (2016) study, mauli banana extract gel at 37.5% concentration is able to accelerate the healing of rat traumatic ulcers with the increase of neovascular number. There has been no study that discusses the effect of mauli banana extract at 37.5% concentration on epithelial thickness in oral mucosa incision wounds.^{6,7} In the study performed by Kalangi et al (2013), the application of patent drug containing Aloe vera topically on wistar rat oral mucosa affect reepithelization rate on the 7th day of wound healing process.

The increase of reepithelization rate is influenced by an active compound contained in Aloe vera patent drug (Acemannan and saponin).² Acemannan can stimulate growth factor expenditure on wound closure produced by fibroblast.⁷ Saponin contained in Aloe vera patent drug has antibacterial and immunomodulatory properties which can stimulates macrophages, lymphocytes, cytokines, interleukins and TNF (Tumor Necrosis Factor) that improve the process of reepithelization. Aloe vera patent drug effective for application in wound healing but it is difficult to obtain and quite expensive.⁸ This is different from traditional medicine which is more safe and affordable for the people.

Traditional plants can be another alternative as a therapeutic drug used to accelerate wound healing. One of the treatments that can be used on wound in the oral cavity is mauli banana stem extract gel.^{9,10} Maui banana (*Musa acuminata*) is a typical plant in South Kalimantan. Empirically, natural ingredients such as mauli banana stem do not cause toxic effects on the people as well as easily obtained and affordable in price.^{5,11} This plant has major bioactive contents of flavonoids and tannins which often used as a wound healing accelerator. In the study performed by Apriasari et al (2015), mauli banana stem extract gel concentration of 25% application on the wound healing of wistar rats oral mucosa can increase epithelial thickness at day 7.¹² This is because mauli banana stem extract gel has potency as imunomodulator which increase the macrophages and neovascular number. Saponin contents have an antiseptic effect and stimulate collagen formation. Tannin as an antioxidant can decrease inflammatory cells and accelerate the process of reepithelization, so that wound healing can be proceeded rapidly.^{13,14} Wound healing is divided into 3 phases, begin with the inflammatory phase (from 0 to 3 days or 5 days).¹¹ The next phase is proliferation (from day 3 or day 4) characterized by proliferation of fibroblasts, angiogenesis, and reepithelization.¹⁵ According to Apriasari et al (2015), the process of

reepithelization peaked from day 7 to day 14 and ended with a remodeling phase.¹⁶

Based on Apriasari et al, (2016) mauli banana stem extract gel at 37.5% concentration is able to accelerate the healing of traumatic ulcers by increasing the number of neovascular through expression of NF κ B, HIF-1 α , Isp90 and VEGF. There has been no study on the effect of mauli banana stem extract gel concentration of 37.5% on epithelial thickness in oral mucosa incision lesions seen at day 7. Based on the description, it is necessary to study the effect of mauli banana (*Musa acuminata*) stem extract gel concentration of 37.5% on epithelial thickness in oral mucosa incision wound of male wistar rat (*Rattus novergicus*)

MATERIALS AND METHODS

This study was pure experimental (true experimental) with posttest-only control group design. The population of this study was wistar rat by 21 samples. The inclusion criteria for this study were male sex, age of 2-3 months, healthy or normal rat, characterized by rat movements such as eating, drinking and no injuries or body disabilities. Exclusion criteria of this study sample were dead rat, apparently sick rat (inactive movement, did not want to eat and dull hair). The number of samples was obtained by unpaired numerical formula.¹⁵ Minimum number of each group consisted of 7 samples. Thus, the total number of samples was 21 which divided into 3 treatment groups. Group I treated with mauli banana stem extract gel concentration of 3.75%, group II with hydroxypropyl methylcellulose gel (HPMC), group III with patent drug containing Aloe vera extract gel.

The making of mauli banana stem extract gel at 37,5% concentration was done by cleaning and drying the samples, then blending the stem until it smooth. The next step is the extraction making which was done by maceration method. Dried mauli banana stem was soaked in 70% ethanol and stirred, then the result was evaporated by rotary evaporator 40°C-50°C, then reevaporated in the waterbath until the extract become thick blackish brown. The next step was doing ethanol-free test to ensure ethanol-free test to ensure the ethanol has evaporated completely. The ethanol test was performed by addition of potassium dichromate (K₂Cr₂O₇) in case of any color change when added reagent react to contained alcohol, if there was no color change then it was alcohol free.

The prepared ethanol-free extracts were made into a 37.5% concentration gel. The mauli banana stem extract gel was made with HPMC. The process was started by diluting the extract with

distilled water. HPMC was mixed with propylene glycol and tween 80, with rapid stirring. Mauli banana stem extract was added and stirred rapidly, then candy oil and distilled water were added to the mixture. Mauli banana stem extract gel of 37.5% concentration has a blackish brown color with bitter taste.

The study included acclimatization and animal treatment steps. Before the study, a proposal had been submitted to the commission of ethics (Animal Care and Use Committee) no. 008/KEPKG/FKGULM/EC/VIII/2017 at the Faculty of Dentistry University of Lambung Mangkurat. Before the testing of animal subject, it should be clinically evaluated by conditioning the animal in a 14 x 24 hours to ensure no rats was sick or had infectious disease according to the population. Characteristics of 21 rats adapted for 1 week in a cage away from the noise, each cage contained 5 rats. Tested animal was fed with Hi-Pro-Vite pokphan chicken feed given every morning, noon, and night in the feeding container. Drinks were given in 300 ml bottles which were equipped with small pipes and filled with boiled water.

Wistar rats were divided into 3 treatment groups with total sample of 21 rats and numbered according to each group. Treatment begins with ether anesthesia inhalation, then the middle buccal mucosa was injured with a sterile or disposable blade scalpel with a 10 mm in-length and a depth of 1 mm mucosal incision. The bleed was cleaned with aquadest. Ether inhalation was done by placing ether anesthesia on cotton in a place made from glass tube. The rats were put into the glass tube and the response was observed. Each group was given different treatment, Group 1 (treatment control) applied with mauli banana stem extract gel at 37,5% concentration on wound 3x1 day weighing 0.05 gram for 7 days. Group 2 (negative control) was given an application of hydroxypropyl methylcellulose gel (HPMC) on wound 3x1 day weighing 0.05 gram for 7 days. Group 3 (positive control) was applied with the patent drug containing Aloe vera extract gel on the wound 3x1 day weighing 0.05 gram for 7 days.

Decapitation phase was done on the 7th day where rat in each group were decapitated to see epithelium thickness on the wound healing process with anesthesia by using diethyl ether inhalation. After that, a biopsy was performed on the wound healing site.

The steps of preparat making were done by taking the tissue of wistar rats mucosal wound from each group into fixed solvent using formalin buffer to make the histopathology preparat. The tissue was loaded into embedding cassette then rotated with tissue processor. After that, it was continued with the making of tissue block, Haematoxylin-Eosin staining, and the mounting of the biopsied tissue. Specimen was observed using Olympus light microscope under 100 times magnification. The measurement and calculation of epithelial thickness was done by using micrometer. The epithelial thickness was observed in the predetermined region of the wound edge region on the 7th day in comparison between positive control, negative control, and treatment group. Then it was measured or analyzed. The thickness of the epithelium that indicates the wound healing process was measured by one field site. The location was determined on the right, middle and left side of the injury. One field of epithelial area divided into 5 areas separated using a measuring line. The line was made perpendicular to the epithelium surface. The measurement of epithelial thickness on each measuring line was then summed and obtained the mean value which was the result of measurement for one research subject.

The study was based on the data that has been obtained from epithelial thickness of wound healing process. The obtained data was in the form of units of micrometer from the measurement of epithelial thickness, The data was presented in the form of graphs and tables and continued by performing the SPSS test upon it.

RESULTS

The study of EBPM concentration of 37,5% effect on epithelial thickness extract gel (EBPM) concentration of 37,5% on epithelial thickness was done by measuring the epithelial thickness using micrometer on day 7 histopathologically. The treatment control group, positive control group, negative control group had different increase in epithelial thickness. The increase of epithelial thickness in Mauli Banana group was higher than negative control group and positive control group on the 7th day. The results of epithelial thickness measurement in each group obtained an average value as in figure 1.

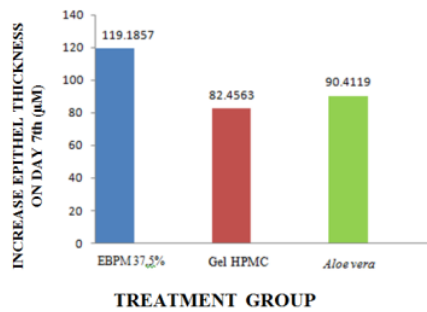


Figure 1. Diagram of epithelial thickness increase on oral mucous membrane of wistar rats wound healing in treatment group of mauli banana stem extract gel (EBPM) 37,5%, negative control of HPMC, positive control of the patent drug containing Aloe vera extract gel on the 7th day with a Micrometer.

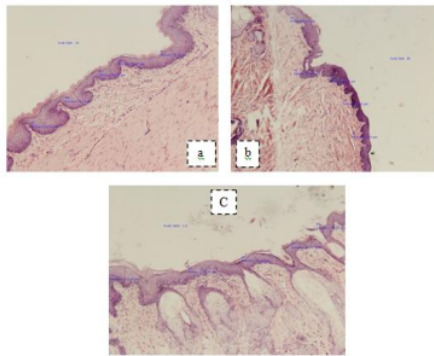


Figure 2. Histopathological Overview of Epithelial Thickness Increase on the Wound Healing of Wistar rats Oral Mucosa with Mauli Banana Extract Gel Concentration of 37.5% in Treatment Group (a), Negative Control Group Gel HPMC (b), Positive Control Group Containing Aloe vera Extract Gel (c) On Day 7th Observed by Olympus Light Microscope 100 Times Magnification.

Based on figure 2, the epithelial thickness was higher in mauli banana stem extract gel concentration of 37,5% group than the negative control group and positive control group on the 7th day. The data were processed and the normality test showed normal result and homogeneity test showed homogeneous result, it was continued with parametric one-way Anova test on the 7th day with 95% confidence level which can be seen in table 1.

Table 1. One-way Anova test results, mean and deviation standard on epithelial thickness

No.	Group	Sig.	Mean ± SD
1.	EBPM 37,5%	.014	119.1857 µm ± 28.26626 µm
2.	HPMC		82.4563 µm ± 21.25048 µm
3.	Aloe vera		90.4119 µm ± 26.17725 µm

The table above shows significance value of ($p < 0.05$). The next test was the LSD Post Hoc test to know which of each treatment group has significant differences in epithelial thickness as depict in Table 2.

Table 2. LSD post hoc test results

Group	Mauli Banana Stem Extract Gel Concentration of 37,5%	hydroxypropyl methylcellulose gel (HPMC)	patent drug containing Aloe vera extract
Mauli Banana Stem Extract Gel Concentration of 37,5%	-	.005*	.024*
hydroxypropyl methylcellulose gel (HPMC)	.005*	-	.492*
Patent Drug Containing Aloe Vera Extract	.024*	.492*	-

*=There is significant difference (p<0.05)

Based on the post hoc LSD test results, the table shows that there is a significant difference between epithelial thickness found in the mauli banana stem extract gel concentration of 37.5% with hydroxypropyl methylcellulose gel (HPMC) group and a patent drug containing Aloe vera extract gel group (p<0.05). There is no significant difference in epithelial thickness in HPMC gel group and patent drug containing Aloe vera extract gel group (p>0.05). This means that there is a difference in the epithelial thickness increase on the day 7th between mauli banana stem extract gel concentration of 37.5%, HPMC and patent drug

containing Aloe vera extract gel with the highest value found in mauli banana stem extract gel concentration of 37.5%.

DISCUSSION

The result of the study has shown an increase of epithelial thickness after the application of mauli banana stem extract gel (EBPM) concentration of 37.5% on the wound healing of wistar rat oral mucosa. This occurs because mauli banana stem extract gel concentration of 37.5% have immunomodulatory properties that can increase the number of macrophages and neovascular.¹⁷

The increase of macrophages and neovascular number which increase the epithelial thickness in treatment control was due to the contents effect in mauli banana stem extract gel concentration of 37.5%. The study of Apriasari et al (2016) states that mauli banana stem extract gel concentration of 37.5% has the highest tannin content at 67.59% and saponin at 14.49%.^{17,18} Tannin as an antioxidant has activity that can affect inflammatory cells in inflammation to minimize the infections of microorganisms that can inhibit the re-epithelization process. Saponin as an anti-inflammatory has an immunostimulant effect that can increase phagocytosis of macrophage cells. The content of tannins and saponins in mauli banana stem extract gel can increase the epithelium thickness in which the re-epithelization of wound healing process become quicker.¹⁹

A wound can automatically cause the body to lose its epithelial tissue. The damaged epithelial tissue will undergo re-epithelization, a process whereby the cells will be repaired so the wound can be closed normally.²⁰ In this case, several growth factors that can support the process of re-epithelization are included such as PDGF (platelet derived growth factor), FGF (Fibroblast growth factor), TGF-β (Transforming Growth Factor Beta), VEGF (Vascular Endothelial Growth Factor).²¹ In the process of re-epithelization, mobilization, migration, mitosis and epithelial cell differentiation are occurred which will help to restore the integrity of the missing mucosa.²²

In this case, wound healing is naturally stimulated by PDGF and FGF. According to the study by Okabe et al (2013), it is stated that FGF reduces scars by inhibiting scar formation in granulation tissue. This occurs through the mitosis of epithelial cells in the wound area. At the edges of the wound, there is a basal cell that will divide

rapidly and migrate and then loosen its bond and enlarge. The cell will move towards the surface of the wound and fuse in the center of it. The migration of cells in the injured area is stimulated by TGF- β , a growth factor generated from granulation tissues during the inflammatory process. If the migration of the cells has been united then the wound will be closed and free of bacterial contamination so that the tissue underneath will gradually recover.^{21,23,24}

The presence of tannin and saponin on the wound can accelerate the healing process. Saponins and tannins can trigger vascular endothelial growth factor (VEGF) and increase the macrophages number that will migrate to the wound area. Macrophage migration is stimulated by TGF- β which increase the number of macrophages and the production of fibroblast in wound tissue. This will affect the production of cytokines and growth factors. The increase of growth factor cause the increase of new cells formation process, so that the epithelium thickness will increase.^{23,25} On the 7th day, the epithelial thickness reach its highest width because of the inflammation process has stopped which is marked by the fibroblast existence that migrate more around the wound, then collagen and fibroblast become attached so the epithelium can thicken on the 7th day. The epithelium thickness has appeared on the 1st day, and then it will continue to increase on the 7th day until 14th day. This is because of the epithelial formation begins since the start of wound healing process in a closed wound. Epithelial enhancement indicates that wound healing progressed rapidly with a brief inflammatory process.²⁶

The study result showed that the average value of epithelial thickness on the day 7th in mauli banana stem extract gel concentration of 37.5% (control treatment) had the highest value compared to the patent drug containing Aloe vera extract gel (positive control) group and hydroxypropyl methylcellulose gel (HPMC) (negative control) group. This is in accordance with previous study which states that mauli banana stem extract gel concentration of 37.5% accelerate the traumatic ulcers healing by increasing the number of neovascular through the expression of NF κ B, HIF-1 α , Hsp90 and VEGF.¹⁷

The mauli banana stem extract gel concentration of 37.5% has the highest elevation of epithelial thickness, which means mauli banana stem extract gel concentration 37.5% could accelerate wound healing better than positive control group and negative control group. This is because mauli banana stem extract gel concentration of 37.5% has tannin and saponin content. Tannin and saponin in mauli banana stem extract gel concentration of

37.5% have potency as immunomodulators which can increase the number of macrophages and neovascular. By the increase of macrophage, the migration of epithelial cell in wound healing will become quicker. Thus leads to acceleration of wound healing process.^{17,27}

The active ingredient on the wound by giving patent drugs containing aloe vera extract gel include accemanan and saponin. Accemanan helps to

stimulate growth factor expenditure on wound closure while saponin as an immunomodulator can stimulate macrophages, lymphocytes, cytokines and interleukins.⁷ According to Aldi et al (2014), immunomodulators are compounds which can improve the body's immune system (immune). Immunomodulatory provision is necessary in wound healing process because when a body is injured, it suffers immune system imbalance. Provision of these compounds can increase the activity of the immune system which is very helpful to overcome wound healing.

The immunomodulatory compounds are widely obtained from plants. Maui banana stem extract gel concentration of 37.5% has a better immunomodulatory compound than the patent drug containing Aloe vera extract gel because it has more content of tannin and saponin while the patent drug containing Aloe vera extract gel only has saponin.^{17,28,29} This means that mauli banana stem extract gel concentration of 37.5% has the potential that can accelerate wound healing better on the oral mucosa. The study of Puspitasari et al (2017) states that Aloe vera is equal to mauli banana extract gel concentration of 25% because it has the same content of tannin, saponin, and flavonoids and has the equivalent healing rate.¹³

The epithelial thickness in negative control had a lower mean than the mauli banana stem extract gel concentration of 37.5% and the positive control. This is because the negative control is only a HPMC in the form of gel. The HPMC gel is a gelling agent commonly used as the basis of topical preparations and has no active ingredients.³⁰ This causes many microorganisms to be phagocytosed that the wound healing process become slow. It can be concluded that mauli banana stem extract gel concentration of 37.5% increase the epithelium thickness better than the patent drugs containing Aloe vera gel and HPMC gel.

THE EFFECT OF MAULI BANANA STEM EXTRACT GEL (*Musa acuminata*) APPLICATION IN CONCENTRATION OF 37.5% ON EPITHELIAL THICKNESS

ORIGINALITY REPORT

3%

SIMILARITY INDEX

2%

INTERNET SOURCES

1%

PUBLICATIONS

0%

STUDENT PAPERS

MATCH ALL SOURCES (ONLY SELECTED SOURCE PRINTED)

1%

★ Mathew, Nimisha Sarah, and Pradeep Singh Negi. "Traditional uses, phytochemistry and pharmacology of wild banana (*Musa acuminata* Colla): A review", *Journal of Ethnopharmacology*, 2017.

Publication

Exclude quotes On

Exclude matches Off

Exclude bibliography On