

Vol. 6 No. 1. Maret 2021

# DENTINO

Jurnal Kedokteran Gigi

Terbit Setiap Maret dan September

TERAKREDITASI : No. 85/M/KPT/2020  
DIREKTUR JENDERAL PENGUATAN RISET DAN PENGEMBANGAN  
KEMENTERIAN RISET, TEKNOLOGI, DAN PENDIDIKAN TINGGI



Dentino. Vol. 6 No. 1. Maret 2021. P-ISSN 2337-5310. E-ISSN 2527-4937  
Indexed Directory of Open Access Journals (DOAJ),  
Sosialisasi Science and Technologi Index (SINTA)

# **DENTINO**

## **JURNAL KEDOKTERAN GIGI**

---

Terbit setiap Maret dan September

Terakreditasi : No. 85/M/KPT/2020

### **PENGELOLA JURNAL DENTINO**

#### **Editor :**

Dr. Maharani Laillyza Apriasari, drg., Sp.PM  
(Fakultas Kedokteran Gigi ULM)

#### **Sekretaris :**

Juliyatin Putri Utami, S.Si., M.Biomed.  
(Fakultas Kedokteran Gigi ULM)

#### **Design Grafis:**

Amalia Husna, Am.Kg  
(Fakultas Kedokteran Gigi ULM)

#### **Foto Grafi:**

Rifky Ananda, SE  
(Fakultas Kedokteran Gigi ULM)

#### **Reviewer Internal :**

drg. Dewi Puspitasari, M.Si; drg. Amy Nindia Carabelly, M.Si; drg. Beta Widya Oktiani, Sp.Perio

#### **Reviewer Ekternal :**

Dr. Iin Eliana Triwahyuni, drg., M.Kes (Fakultas Kedokteran Gigi Universitas Jember); Tania Saskianti, drg, Sp.KGA (K).Phd (Fakultas Kedokteran Gigi Universitas Airlangga); drg. Indah Suasani Wahyuni, Sp.PM (Fakultas Kedokteran Gigi Universitas Padjadjaran)

#### **Reviewer Bahasa :**

drg. Selviana Rizky Pramitha; drg. Aninditya Pimas Trianuanty

# DENTINO

## JURNAL KEDOKTERAN GIGI

---

Terbit setiap Maret dan September

Terakreditasi : 85/M/KPT/2020

### DAFTAR ISI

THE EFFECT OF SALTWATER FISH NANOPARTICLE POWDER CONSUMPTION ON TOOTH ENAMEL DENSITY In Vivo Study of Mice (*Mus musculus*)

**Sandy Christiono, Fera Putri Ardiani, Welly Anggarani, Fourier Dzar Eljabbar** ..... 1-5

THE RELATIONSHIP BETWEEN THE SEVERITY OF MALOCCLUSION AND GINGIVAL STATUS IN STUDENTS OF SMPN 5 MARABAHAN

**Akhmad Aufayed Ma'rifatullah, Diana Wibowo, Aulia Azizah**..... 6-12

THE EFFECT OF IRONWOOD STEM BARK EXTRACT (*Eusideroxylon zwageri*) ON THE GROWTH OF *Streptococcus mutans* ON ACRYLIC RESIN DENTURE PLATE

**Amalia Noviyanti, I Wayan Arya Krishnawan Firdaus, Rahmad Arifin**..... 13-19

EFFECT OF WATER-SETTABLE GIC IMMERSION IN RIVER WATER AND PDAM WATER ON DIAMETRAL TENSILE STRENGTH

**Raden Harry Dharmawan Setyawardhana, Sherli Diana, Muhammad Rezky Gunawan** ..... 20-24

ANTIBACTERIAL EFFECTIVENESS TEST OF RAMANIA LEAVES (*Bouea macrophylla* Griffith) FLAVONOIDS EXTRACT ON *Aggregatibacter actinomycetemcomitans* BACTERIA CAUSING AGGRESSIVE PERIODONTITIS

**Noor Khalishah, Beta Widya Oktiani, Rosihan Adhani**..... 25-30

THE EFFECT OF ULIN (*Eusideroxylon zwageri*) STEM BARK EXTRACT ON THE GROWTH OF *Candida albicans* ON ACRYLIC RESIN DENTURE PLATES

**Annisa Fitri Yuniar, I Wayan Arya Krishnawan Firdaus, Rahmad Arifin**..... 31-36

ANTIBACTERIAL EFFECTIVITY TEST OF ULIN BARK EXTRACT (*Eusideroxylon zwageri*) ON THE GROWTH OF *Porphyromonas gingivalis*

**Della Isnadya Noor, I Wayan Arya Krishnawan Firdaus, Beta Widya Oktiani**..... 37-43

EFFECT OF SALBUTAMOL SULFAT EXPOSURE TO THE SURFACE ROUGHNESS OF BIOACTIVE RESIN

<b>Dewi Puspitasari, Diana Wibowo</b> .....	44-49
PROPOLIS EXTRACT SORPTION AS A PULPCAPPING AGENT	
<b>Isyana Erlita, Rahmatillah Rahmatillah, Sherli Diana</b> .....	50-53
PREVALENCE OF HUMAN PAPILLOMA VIRUS IN CANCEROUS AND PRE-CANCEROUS ORAL LESIONS USING SALIVA, SERUM, AND PLASMA ASSAY	
<b>Nelly Nainggolan, Wahyu Hidayat</b> .....	54-59
AESTHETIC REHABILITATION OF MAXILLARY AND MANDIBULAR HOPELESS TEETH WITH IMMEDIATE REMOVABLE PARTIAL DENTURE	
<b>Afif Surya Adena, Endang Wahyuningtyas, Intan Ruspita</b> .....	60-64
THE EFFECT OF AIR DRYING TIME ON BONDING (SELF ETCH) WITH ETHANOL AS A SOLVENT TO THE SHEAR BOND STRENGTH OF BIOACTIVE COMPOSITE RESIN	
<b>Devi Rosalinda, Dewi Puspitasari, Muhammad Yanuar Ichrom Nahzi</b> .....	65-71
ANTIBACTERIAL EFFECTIVITY OF FLAVONOID FRACTION OF RAMANIA LEAF EXTRACT (Bouea macrophylla Griffith) AGAINST Porphyromonas gingivalis	
<b>Lailatul Qomariyah, Fransiska Uli Arta Panjaitan</b> .....	72-72
ORAL SECONDARY INFECTION IN STEVENS-JOHNSON SYNDROME PATIENT WITH ORAL INVOLVEMENT: A CASE REPORT	
<b>Etis Duhita Rahayuningtyas, Indah Suasani Wahyuni, Irna Sufiawati</b> .....	79-84
THE COMPARISON OF RESIN-BASED COMPOSITES PHYSICAL PROPERTIES BETWEEN BULK-FILL TECHNIQUE AND INCREMENTAL TECHNIQUE	
<b>Rahmi Khairani Aulia</b> .....	85-89
MANAGEMENT OF HSV-1 AND HSV-2 PRIMARY INFECTION IN ADULT PATIENT: A CASE REPORT	
<b>Bima Ewando Kaban, Dahlia Riyanto, Adiausti Parmadiati, Desiana Radithia, Bagus Soebadi</b> .....	90-95
THE EFFECT OF RAMANIA LEAF (Bouea macrophylla Griff) EXTRACT GEL ON COLLAGEN FIBERS DENSITY IN INCISIONAL WOUND OF MALE WISTAR RATS	
<b>Dinda Rizkia, Irham Taufiqurrahman, Renie Kumala Dewi</b> .....	96-99
DESCRIPTION OF PARTIALLY EDENTULOUS PATTERN AMONG PATIENTS AT RSGMP GUSTI HASAN AMAN IN BANJARMASIN	
<b>Huda Ainani, Rahmad Arifin, Ika Kusuma Wardani</b> .....	100-105

PREPARATION FOR PALATOPLASTY SURGERY WITH AN ACRYLIC  
FEEDING OBTURATOR: A CASE REPORT

**Christine Anita Wardaningrum, Endang Wahyuningtyas, Titik Ismiyati, Sri Budi  
Barunawati**..... 106-110

ANTIBACTERIAL EFFECT OF TITANIUM DIOXIDE NANOPARTICLES AND  
CHITOSAN NANOPARTICLES IN ORTHODONTIC ADHESIVE RESIN ON  
STREPTOCOCCUS MUTANS COLONY

**Wulandani Liza Putri, Erwin Siregar, Haru Setyo Anggani** ..... 111-116

**DENTINO**  
**JURNAL KEDOKTERAN GIGI**  
**Vol VI. No 1. Maret 2021**

**THE EFFECT OF RAMANIA LEAF (*Bouea macrophylla Griff*) EXTRACT GEL  
ON COLLAGEN FIBERS DENSITY IN INCISIONAL WOUND OF MALE  
WISTAR RATS**

**Dinda Rizkia<sup>1)</sup>, Irham Taufiqurrahman<sup>2)</sup>, Renie Kumala Dewi<sup>3)</sup>**

<sup>1)</sup> Faculty of Dentistry, Universitas Lambung Mangkurat, Banjarmasin

<sup>2)</sup> Department of Oral and Maxillofacial Surgery, Faculty of Dentistry, Universitas Lambung Mangkurat

<sup>3)</sup> Department of Pediatric Dentistry, Faculty of Dentistry, Universitas Lambung Mangkurat

**ABSTRACT**

**Background:** Ramanian leaf (*Bouea macrophylla Griff*) extract gel has secondary metabolites in the form of flavonoids, steroids, phenols and terpenoids which have a role as antioxidant. They will protect the body from excessive production of reactive oxygen species (ROS) by increasing endogenous antioxidants SOD, CAT and GPX, so that wound healing will not be inhibited and the process of collagen synthesis can run smoothly. **Objective:** To analyze the effect of ramanian leaf extract gel that was applied topically with 5%, 10% and 15% concentration on collagen fibers density in incisional wound of male Wistar rats (*Rattus norvegicus*) on the 7th and the 14th day. **Method:** This research is a pure experimental study with a posttest-only control group design, using 24 rats which were divided into 4 groups: the treatment groups given ramanian leaf extract gel of 5%, 10%, 15%, and the control group given placebo gel. The application of the extract gel was done once within 24 hours. The collagen level was measured with a spectrophotometer on the 7th and the 14th day. **Results:** Two-Way ANOVA test results on the 7th and the 14th day of each group showed a significant difference with  $p=0.000$  ( $p<0.05$ ). The Bonferroni Post-hoc Test showed a significant difference with  $p<0.05$  between the placebo gel group and the groups of ramanian leaf extract gel of 5%, 10%, 15% on the 7th and the 14th day. **Conclusion:** There is an effect of ramanian leaf extract gel on collagen fibers density with the most effective concentration of 15%.

**Keywords:** Antioxidant, , Collagen, Ramanian Leaf Extract Gel .

**Correspondence:** Dinda Rizkia, Faculty of Dentistry, Universitas Lambung Mangkurat, Jl. Veteran Sungai Bilu No. 128, Melayu, Central Banjarmasin, Banjarmasin, South Kalimantan 70122, E-mail: [dindarizkia18@gmail.com](mailto:dindarizkia18@gmail.com)

**INTRODUCTION**

Human is an active being with many activities that can cause injury, both intentionally and unintentionally. The prevalence of wounds is increasing every year. A research by The American Professional Wound Care Association shows that the incidence of wounds caused by surgery and trauma are up to 48% in the world.<sup>1</sup> The incidence of injuries in Indonesia has increased from year to year. According to the 2018 Basic Health Research (Riskesdas) report, wounds due to oral surgery reached 8.46% and 0.013% were due to tooth extraction. The increased incidence of injuries will certainly become a problem as acute wounds will develop into chronic

wounds when there is an extension in the process of healing.<sup>2,3</sup>

Wound healing is a series of events that occur from the moment of an injury happened and continue until the wound closure, the importance of the body in completing this process is to prevent infection and repair damaged areas. The process of wound healing consists of three phases, namely inflammation, proliferation, and remodeling. The component that plays an important role in the remodeling phase is collagen. Collagen is synthesized by fibroblasts and reaches its peak on the 7th day, and starts to stabilize and be organized around the 14th day.<sup>4</sup> Collagen is the main protein that makes up the extracellular matrix component

and is the protein most commonly found in human body.<sup>4</sup>

Wound healing aims to restore the function and shape of tissues to normal condition with minimal complications. Efforts to heal wounds can be done with chemical drugs, but those drugs have side effects and can cause resistance.<sup>5</sup> Another alternative that can be chosen is the use of herbal medicines. Herbal medicine is chosen as a cheaper solution and also has minimal side effects for the body.<sup>6</sup>

There are various types of treatment that can be done to heal wounds, one of them is herbal medicine that is derived from plants and used as adjuvant therapy. One of the said plants that is found in South Kalimantan is ramania (*Bouea macrophylla Griff*), which belongs to the genus *Bouea* and the family Anacardiaceae. Banjarese people have food consumption patterns that tends to be high in fat which can be one of the risk factors for atherosclerosis that can affect the process of wound healing.<sup>7</sup> It is because ramania leaf has secondary metabolites such as flavonoids, steroids, phenols and terpenoids.<sup>6</sup>

One of the highest contents of ramania is flavonoids. Flavonoids have function as antioxidants, antibiotics, antivirals, anti-allergics, anticancer, antimicrobials, and also anti-inflammatory. Flavonoids as antioxidants will protect the body from excessive production of ROS by increasing endogenous antioxidants SOD, CAT and GPX, so that ROS can be suppressed and wound healing will not be inhibited and the process of collagen synthesis can run smoothly.<sup>8,9</sup>

According to research that was conducted by Rahman *et al* (2017), ramania leaf contains 167.06 µg/mg of flavonoid compounds.<sup>10</sup> A further research by Fitri *et al* (2018) found that the IC50 value of ramania leaf extract was 35.808 µg/mg.<sup>6</sup> Based on another research by Risa (2018), mango leaf extract with a concentration of 15% can help the process of wound healing to run faster which makes the researcher want to use ramania leaf extract as an adjuvant therapy for wound healing in the form of gel preparations with a concentration of 5%, 10%, and 15%. The selection of gel preparations aims to make the absorption process occur faster and to help releasing the active substances on the skin.<sup>11</sup>

## MATERIALS AND METHODS

This research has passed the ethics feasibility test published by the Ethics Commission of the Faculty of Dentistry, Universitas Lambung Mangkurat, Banjarmasin through certificate No.071/KEPKG-FKGULM/EC/1/2020.

This research is a pure experimental design with a posttest-only with control group design. Twenty-four Wistar rats (*Rattus novergicus*) were used as samples for this research. The inclusion criteria for the sample were male Wistar rats weighing 200-250 g, aged 2-3 months, moving actively and having a good appetite.

The procedure for the research was started with the making of Ramania leaf extract using maceration method. Ramania leaves were cleaned by washing them using clean running water, then dried in an oven at 50°C for 4 hours. After that, the leaves were made into dried simplicia powder using a blender. The obtained simplicia powder was sifted with a sieve. The dried simplicia powder was weighed as much as 100 g then macerated. The maceration was done for 3 days without any exposure to sunlight. Around 450 mL of the simplicia ramania leaves were then soaked with ethanol 95%. Afterwards, the maceration result was concentrated with a rotary evaporator at 50°C and evaporated again with a water bath to remove the remaining solvent until a 100% thick extract was obtained. The Ramania leaf extract was then mixed with a gel base to make the gel. Five miligrams of ramania leaf extract was mixed with 95gr of gel base, 10mg of ramania leaf extract was mixed with 90gr of gel base, and 15mg ramania leaf extract was mixed with 90gr of gel base, which then resulted in the concentrations of 5%, 10% and 15% of ramania leaf extract gel.

The preparation of animal testing was done for 7 days. The rats were given standard food and drink in a laboratory setting. The rats were anesthetized intraperitoneally with a mixture of ketamine 40-100 mg/Kg BW and a dose of xylazine 5-10 mg/Kg BW. Before that, the fur on the back of the rat was shaved with a length of 5 cm and height of 3 cm, then it was disinfected with alcohol. The incision was made on the back of the rat with a length of 2 cm and the depth up to subcutaneous tissue using scalpel and blade number 15. The blood that came out was then cleaned with cotton swab that was given a solution

of NaCl. The rats were divided into 4 groups, namely the control group that was given placebo gel and the treatment groups that were given the concentrations of 5%, 10%, and 15% of Ramania leaf extract gel. Each group consisted of 3 rats. The extract gel was applied 1 time a day in a one-way motion and the cotton bud applicator position was rotated, the wound was then covered with gauze.

On the 7th and the 14th day, all of the rats in each group were up for euthanasia by intraperitoneal local anaesthetic mixed of ketamine 40-100 mg/Kg BW and xylazine dose 5-10 mg/Kg BW and waited until the rat became unconscious.

The retrieval of tissue in rat was carried out by biopsy, using an excisional biopsy technique with scalpels and fine surgical scissors. The excised area was the back of the rats with a length of 1 cm, 1 cm, and the depth up to subcutaneous tissue. The tissue that had been biopsied per treatment was taken for biochemical analysis to estimate the amount of hydroxyproline by making homogenates. The sample tissue was dried in an oven at 60-70°C for 12-18 hours. Then, the tissue was hydrolyzed with acid for 6 hours, the result of hydrolysis was centrifuged at 3000 rpm for 15 minutes and 1 ml of the collected supernatant was transferred into the test tube. Supernatants were lyophilized using nitrogen gas flow. After that, the determination of the hydroxyproline content from the sample tissue was done with the Stegemann and Stalder method (1967). Hydrolysate was mixed with buffer of chloramine-T at 4°C, 20 minutes later, 1 mL of Ehrlich's reagent was added to obtain chromophore compounds i.e. the color of the solution turned pink and no schlieren (transparent layer) was formed in the solution until the color change was stable for 30 minutes.

The absorbance of the solution was then measured at a wavelength of 550 nm and the level of hydroxyproline in the sample was extrapolated with a standard hydroxyproline curve that was obtained through a UV-VIS spectrophotometer, using the equation  $y=ax + b$ ,  $y$  is the absorbance and  $x$  is the value of the content. The results were then analyzed.

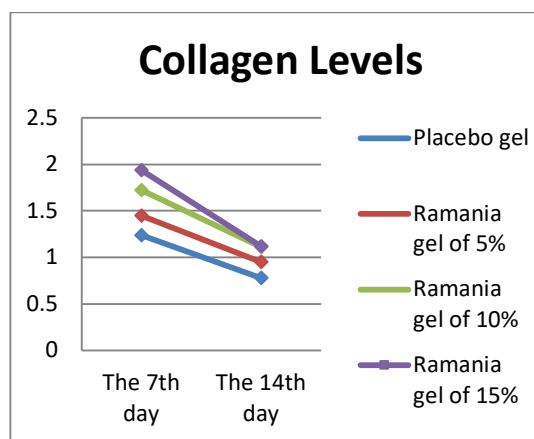
## RESULTS

The statistical results showed the data of all groups were normally distributed and the variance of data was homogeneous. Two-Way Anova test results on the 7th and the 14th day of each group showed that there was a significant difference with  $p=0.000$  ( $p<0.05$ ). The Bonferroni Post-Hoc Test showed that there was a significant difference with  $p<0.05$  between the placebo gel group and the concentrations of 5%, 10% and 15% of ramania leaf extract gel groups.

The results of the average density of collagen fibers in the incision wound of the male wistar rats can be seen in table 1. The graph of the average collagen fibers density of incision in male wistar rats on the 7th and the 14th day can be seen in Figure 1

**Table 1.** The average (Mean±SD) collagen fibers density of incisional wound in wistar rat on the 7th and the 14th day

Day	<i>(Mean ± SD) collagen fibers density</i>			
	Placebo	Ramania 5%	Ramania 10%	Ramania 15%
7	1.238 ± 0.004	1.447 ± 0.033	1.722 ± 0.028	1.934 ± 0.026
14	0.777 ± 0.004	0.949 ± 0.013	1.111 ± 0.001	1.117 ± 0.006



**Figure 1.** Graph of the average density of collagen fibers of incisional wound in wistar rat on the 7th and the 14th day in each group.

In figure 1, it can be concluded that the application of extract gel with higher concentration will be followed by an increase of collagen fibers density in male Wistar rats. High density of collagen fibers shows better antioxidant activity in



Wistar rats. The highest density of collagen fibers in a consecutive order were the concentration of 15%, 10%, 5% of ramania leaf extract, and placebo.

## DISCUSSION

The statistical test results showed that the average density of collagen fibers that was given topically to the incisional wound of the Wistar rats had significant differences between the concentrations of 5%, 10%, 15% of ramania leaf extract gel and placebo gel. This significant difference is due to the presence of flavonoids in ramania leaf. According to the research by Rahman *et al* (2017), ramania leaf contains 167.06 µg/mg of flavonoid compounds.<sup>10</sup>

Flavonoids have function as antioxidants to help the process of wound healing. The function of flavonoids as exogenous antioxidants is by capturing free radicals and activating Nrf2 in the inflammatory phase, so as to maintain a balance between oxidants and antioxidants in the body. The increasing of antioxidant enzymes SOD, CAT, and GPX will prevent the formation of excessive ROS which can disrupt the function of communication between cells so that the process of wound healing can run smoothly.<sup>12</sup> Flavonoids also have immunomodulatory capabilities. Based on the research by Suharto *et al* (2019) who used ginger extract (*Zingiber Officinale Roscoe*), flavonoids can help lymphocyte proliferation and IL-2 production which will stimulate the proliferation phase and the differentiation of T cells. The differentiated T cells will turn into Th1 cells and secrete IFN-γ which has the potential to activate macrophages. Active macrophages will release several growth factors, namely PDGF, FGF, TGF-α, TGF-β and EGF which are responsible in stimulating the proliferation and the migration of fibroblasts, also stimulating the production of extracellular matrix which is important in the process of wound healing.<sup>13</sup> In addition to growth factors, flavonoids will also produce cytokines such as IL-1, IL-4 and IL-8 which play a role in the processes of fibroblasts chemotaxis and keratinocytes, and the activation of fibroblast proliferation and collagen synthesis.<sup>3,14</sup>

The statistical test results of the effect of Ramania leaf extract gel on collagen fibers density

of incisional wound in male Wistar rats on the 7th day showed an increase in collagen levels. This research was in accordance with the research by Sucita *et al* (2019) which proved that rats with incisional wounds given a sappan wood extract (*Caselpinia sappan L.*) at the concentration of 6.5% can topically increase collagen fibers density because of the administration of sappan wood extracts which contain flavonoids as the highest secondary metabolite compound.<sup>15</sup>

At this stage, the wound is still in the proliferation phase which is marked by an increasing number of fibroblasts. The high number of fibroblasts is influenced by the high number of macrophages. This is in line with the research by Suharto *et al* (2019) which states that flavonoids are also the compound that plays a role to activate macrophages. When macrophages increase, TGF-β secretion will also increase. TGF-β has a function to trigger the proliferation and migration of fibroblasts. Fibroblasts proliferation indicates that granulation tissue begins to form through a mechanism that will produce three-dimensional extracellular tissue in connective tissue.<sup>16</sup> Fibroblasts with matrix metalloproteinases (MMP) as the main processor components of the extracellular matrix will capture the fibrin matrix and convert it into glycosaminoglycan (GAG), then the extracellular matrix will be replaced by another fibroblast product namely type III collagen.<sup>17</sup> Type III collagen is a type of collagen that is commonly found during the initial process of wound repair and can reach the maximum amount on the 5th to the 7th day after the wound.<sup>18</sup>

The statistical test results on the 14th day showed a decrease in collagen compared to the 7th day. This is in accordance with the research by Yuza F *et al* (2014) about the process of wound healing after tooth extraction in guinea pigs using 90% of Aloe Vera (*Aloe barbadensis Miller*) extract which has the same content as ramania leaf which is flavonoids. The results of the research showed an increase in collagen fibers on the 7th day and a decrease on the 14th day. On the 14th day, the decrease in collagen fibers density in the control and treatment group was because at this stage the process of wound healing was in the remodelling phase.<sup>19</sup> In this phase, there is simultaneous synthesis and degradation of collagen, so that the amount of collagen seen is not

as much as in the previous phase. The final amount of collagen depends not only on collagen synthesis, but also its degradation. The balance between collagen synthesis and tissue degradation forms a normal process of wound healing. This balance occurs between them until 3 weeks after the injury before the stability finally occurs.<sup>17,20</sup> In this phase, type III collagen will be replaced by type I collagen which forms a band and has stronger tensile strength and density in new tissue.<sup>21</sup> When the collagen fibers begin to form, the tensile strength of the wound will also slowly return. At the end of this remodelling phase, skin injuries are only able to withstand stretches of approximately 80% of their ability than normal skin.<sup>22</sup>

The results showed that Ramania leaf extract gel of 15% gave a better effect than Ramania leaf extract gel of 5%, 10%, and placebo gel. The results of this research are supported by the research that was conducted by Dewantari and Sugihartini (2015) which stated that the higher number of extract concentration in the gel preparation would also increase the activity of wound healing more.<sup>23</sup> This showed that collagen fibers density with high concentrations would result in higher antioxidant activity.<sup>24</sup> This antioxidant activity is caused by the components that are contained in Ramania leaf, namely flavonoids, phenols, steroids, and terpenoids in Ramania leaf extract gel to support one another, making it more effective to produce antioxidants.<sup>25</sup>

Based on this research, it can be concluded that there is an effect of ramania leaf extract gel (*Bouea macrophylla Griff*) on collagen fibers density with the most effective concentration of 15%.

## REFERENCES

1. Huda N, Febriyanti E, Laura DD. Edukasi Berbasis Nutrisi dan Budaya Pada Penderita Luka Kronis. *Jurnal Pendidikan Perawatan Indonesia*. 2018; 4(1): 1-12.
2. Febrianti N, Tahir T, Yusuf S. Study Literature Peran Epidermal Growth Factor dalam Proses Penyembuhan Luka. *Jurnal Keperawatan Muhammadiyah*. 2019; 4 (1): 8.
3. Sabirin IPR, Maskoen AM, Hernowo BS. Peran Ekstrak Etanol Topikal Daun Mengkudu (*Morinda citrifolia L.*) pada Penyembuhan Luka Ditinjau dari Imunoekspresi CD34 dan Kolagen pada Tikus Galur Wistar. *MKB*. 2013; 45 (4): 229.
4. Pramono WB, Leksana E, Satoto HH. Pengaruh Pemberian Ropivakain Infiltrasi Terhadap Tampilan Kolagen Di Sekitar Luka Insisi Pada Tikus Wistar. *Jurnal Anestesiologi Indonesia*. 2016; 8 (1): 3
5. Putri RR, Hakim RF, Rezeki S. Pengaruh Ekstrak Daun Tapak Dara (*Catharanthus roseus*) terhadap Jumlah Fibroblas pada Proses Penyembuhan Luka di Mukosa Oral. *Journal Caninus Dentistry*. 2017; 2 (1): 20-30.
6. Fitri L, Taufiqurrahman I, Imamanda DH. Phytochemical And Cytotoxicity Testing Of Ramania Leaves (*Bouea macrophylla Griffith*) Ethanol Extract Toward Vero Cells Using Mtt Assay Method. *Dentino Jurnal Kedokteran Gigi*. 2018; 3 (1): 52-54.
7. Huldani, Kaidah, S., Adiputro, D.L., Harun Achmad, Sukmana, B.I., Deby, D.K.T.P, Wasiaturrehman, Y, Renie Kumala Dewi, Aspriyanto, D., Isnur Hatta, Winias, S., Pratiwi, A.R., Ernita sari1, Putra. A.P., Anastasya Deborah M. C Manik, Ketrin Zailin, Wardani, I.K. Effect of Total Cholesterol Levels and Triglycerides on Blood Pressure Hypertension Patients Overview against Puskesmas Banjar Ethnic Group in Cempaka Banjarmasin. *Sys Rev Pharm* 2020; 11(4): 384 389 A multifaceted review journal in the field of pharmacy.
8. Napanggala A, Susianti, Apriliana E. Pengaruh Pemberian Getah Tanaman Jarak Pagar (*Jatropha curcas L.*) Secara Topikal Terhadap Tingkat Kesembuhan Luka Iris Pada Tikus Putih Jantan Galur Sprague dawley. *Publikasi FK Lampung*. Lampung. 2012; 3(5): 31-34.
9. Noora WF, Apriantia N, Saputra SR, Afifah B, Apriasari ML, Suhartono E. Oxidative Stress on Buccal Mucosa Wound in Rats and Rule of Topical Application of Ethanolic Extracts of Mauli Banana (*Musa Acuminata*) Stem. *The Journal of Tropical Life Science*. 2015; 5(2): 84-87.
10. Rahman A, Taufiqurrahman I, Edyson. Perbedaan Total Flavonoid Antara Metode Maserasi Dengan Sokletasi Pada Ekstrak Daun Ramania (*Bouea macrophylla Griff*). *Dentino*. 2017; 1 (1): 22-7.
11. Hasanah U, Yusriadi, Khumaidi A. Formulasi Gel Ekstrak Etanol Daun Kelor (*Moringa oleifera Lam*) sebagai Antioksidan. *Online Journal of Natural Science*. 2017; 6 (1): 46-57.
12. Arief H, Widodo MA. Peranan Stres Oksidatif pada Proses Penyembuhan Luka. *Jurnal Ilmiah Kedokteran Wijaya Kusuma*. 2018; 5(2): 22-29.
13. Kurnia PA, Ardhiyanto HB, Suhartini. Potensi Ekstrak Teh Hijau (*Camellia sinensis*) Terhadap

- Peningkatan Jumlah Sel Fibroblas Soket Pasca Pencabutan Gigi pada Tikus Wistar. e-Jurnal Pustaka Kesehatan. 2015. 3 (1): 122-127.
14. Fuadi MI, Elfiah U, Misnawi. Jumlah Fibroblas pada Luka Bakar Derajat II pada Tikus dengan Pemberian Gel Ekstrak Etanol Biji Kakao dan Silver Sulfadiazine. e-Jurnal Pustaka Kesehatan. 2015; 3 (2): 244-248.
  15. Sucita RE, Hamid IS, Fikri F, Elziyad MT, Purnama. Ekstrak Etanol Kayu Secang (*Caesalpinia Sappan L.*) Secara Topikal Efektif Pada Kepadatan Kolagen Masa Penyembuhan Luka Insisi Tikus Putih. Jurnal Medik Veteriner. 2019; 2(2): 119-126.
  16. Gonzalez ACO, Costa TF, Andrade ZA, Medrado ARAP. Wound Healing – A Literature Review. An Bras Dermatol. 2016; 91 (5): 614-20.
  17. Primadina N, Basori A, Perdanakusuma DS. Proses Penyembuhan Luka Ditinjau Dari Aspek Mekanisme Seluler Dan Molekuler. Qanun Medika. 2019; 3 (1): 31-42.
  18. Etika AN, Nurrahayu KI, Suhato IPS. Pengaruh Ekstrak Jahe (*Zingiber Officinale Roscoe*) Terhadap Jumlah Sel Fibroblas pada Tikus (*Rattus norvegicus*). Journal of Nursing Care & Biomolecular. 2017. 2(1): 10-14.
  19. Yuza F, Wahyudi IA, Larnani S. Efek Pemberian Ekstrak Lidah Buaya (*Aloe Barbadensis Miller*) pada Soket Gigi terhadap Kepadatan Serabut Kolagen Pasca Ekstraksi Gigi Marmut (*Cavia Porcellus*). Majalah Kedokteran Gigi. 2014; 21(2): 127-135.
  20. Purnama H, Sriwidodo, Ratnawulan S. Review Sistematis: Proses Penyembuhan Dan Perawatan Luka. Farmaka. 2017; 15 (2): 251-256.
  21. Ismardianita E, Widyawati, Ellanora D, Rosalina W, Nofrike L, Khairani VY. The Effectiveness Methanol Extract Clausena excavate on Number of Fibroblast and Density of Collagen Fibers After Tooth Extraction. Journal of Dentomaxillofacial Science. 2019. 4 (3): 170-175.
  22. Apriasari ML, Dachlan YP, Ernawati DS. Potensi Bahan Alam terhadap Penyembuhan Ulser Mukosa Mulut. Jakarta: Salemba Medika; 2017. p.28-31.
  23. Dewantari DR dan Sugihartini N. Formulasi dan Uji Aktivitas Gel Ekstrak Daun Petai Cina (*Leucaena glauca, Benth*) sebagai Sediaan Obat Luka Bakar. Farmasains. 2015; 2 (5): 217-222.
  24. Wahdaningsih S, Setyowati E.P, Wahyuoni S. Aktivitas Penangkap Radikal Bebas Dari Batang Pakis (*Alsophila Glauca J. Sm*) Free Radical Scavenging Activity Of (*Alsophila Glauca J. Sm*). Majalah Obat Tradisional. 2011; 16(3): 156 – 160.
  25. Prasetya RC. Ekspresi dan Peran Siklooksigenase-2 dalam Berbagai Penyakit di Rongga Mulut. Stomatognatic (J. K. G. Unej). 2015; 12(1) : 16-19.