

Vol. 6 No. 2. September 2021

# DENTINO

Jurnal Kedokteran Gigi

Terbit Setiap Maret dan September

TERAKREDITASI : No. 85/M/KPT/2020

DIREKTUR JENDERAL PENGUATAN RISET DAN PENGEMBANGAN  
KEMENTERIAN RISET, TEKNOLOGI, DAN PENDIDIKAN TINGGI



# **DENTINO**

## **JURNAL KEDOKTERAN GIGI**

---

Terbit setiap Maret dan September

Terakreditasi : No. 85/M/KPT/2020

### **PENGELOLA JURNAL DENTINO**

#### **Editor :**

Dr. Maharani Laillyza Apriasari, drg., Sp.PM  
(Fakultas Kedokteran Gigi ULM)

#### **Sekretaris :**

Juliyatin Putri Utami, S.Si., M.Biomed.  
(Fakultas Kedokteran Gigi ULM)

#### **Design Grafis:**

Amalia Husna, Am.Kg  
(Fakultas Kedokteran Gigi ULM)

#### **Foto Grafi:**

Rifky Ananda, SE  
(Fakultas Kedokteran Gigi ULM)

#### **Reviewer Internal :**

drg. Dewi Puspitasari, M.Si; drg. Amy Nindia Carabelly, M.Si; drg. Beta Widya Oktiani, Sp.Perio

#### **Reviewer Ekternal :**

Dr. Iin Eliana Triwahyuni, drg., M.Kes (Fakultas Kedokteran Gigi Universitas Jember); Tania Saskianti, drg, Sp.KGA (K).Phd (Fakultas Kedokteran Gigi Universitas Airlangga); drg. Indah Suasani Wahyuni, Sp.PM (Fakultas Kedokteran Gigi Universitas Padjadjaran)

#### **Reviewer Bahasa :**

drg. Selviana Rizky Pramitha; drg. Aninditya Pimas Trianuanty

# DENTINO

## JURNAL KEDOKTERAN GIGI

---

Terbit setiap Maret dan September

Terakreditasi : 85/M/KPT/2020

### DAFTAR ISI

INHIBITORY ACTIVITY OF ULIN BARK (*Eusideroxylon zwageri*) EXTRACT TO  
Lactobacillus acidophilus

**Ina Rezki Rahmasari, I Wayan Arya Krishnawan Firdaus, Renie Kumala Dewi ..... 117-121**

CORRELATION BETWEEN THE KNOWLEDGE LEVEL OF MOTHER ON  
DENTAL HEALTH AND THE CARIES SEVERITY LEVEL OF CHILDREN IN  
BARITO KUALA

**Galuh Dwinta Sari, Noor Mutiari Amalia, Isnur Hatta ..... 122-125**

THE EFFECT OF PREGNANCY MILK ON THE EXPRESSION OF KALLIKREIN  
RELATED PEPTIDASE-4 (KLK-4) AND COLLAGEN TYPE 1 (Coll-1) IN  
AMELOGENESIS

**Sandy Christiono, Welly Anggarani ..... 126-130**

THE EFFECT OF KARAMUNTING (*Rhodomyrtus Tomentosa*) LEAF EXTRACT ON  
THE NUMBER OF MACROPHAGES IN PULP INFLAMMATION

**Indah Septiani, Muhammad Yanuar Ichrom Nahzi, Nolista Indah Rasyid ..... 131-135**

THE EFFECTS OF PANORAMIC RADIOGRAPHY ON GINGIVAL CREVICULAR  
FLUID VOLUME IN GINGIVITIS

**Rini Rahmiyati, Didit Aspriyanto, Beta Widya Oktiani ..... 136-140**

THE EFFECT OF PANORAMIC RADIOGRAPHY ON THE NUMBER OF  
MICRONUCLUES IN PERIODONTITIS

**Khairunnisa Puspita Sari, Didit Aspriyanto, Beta Widya Oktiani ..... 141-146**

CORRELATION BETWEEN SOCIOECONOMIC STATUS OF PARENTS AND ORTHODONTIC TREATMENT NEEDS IN THE STUDENTS OF SMAN 10 BANJARMASIN	
<b>Restika Hidayati, Diana Wibowo, Riky Hamdani .....</b>	<b>147-153</b>
EFFECTS OF RED DRAGON FRUIT PEEL EXTRACT ADMINISTRATION ON NEUTROPHIL COUNTS FOLLOWING PERIAPICAL RADIOGRAPHY EXPOSURE	
<b>Maydina Izzatul Yazidah, Didit Aspriyanto, Renie Kumala Dewi.....</b>	<b>154-158</b>
THE COMPARISON OF RAMANIA ( <i>Bouea macrophylla</i> Griff) AND BINJAI ( <i>Mangifera caesia</i> ) LEAVES EXTRACT GEL EFFECT ON COLLAGEN DENSITY	
<b>Nabilah Nabilah, Irham Taufiqurrahman, Nolista Indah Rasyid.....</b>	<b>159-165</b>
THE EFFECT OF BINJAI ( <i>Mangifera caesia</i> ) LEAVES EXTRACT GEL TO FIBROBLAST CELL NUMBER ON INCISION WOUND	
<b>Noor Hildayanti, Irham Taufiqurrahman, Renie Kumala Dewi.....</b>	<b>166-170</b>
EFFECT OF CHANNA MICROPELTES IN THE GRANULATION, FIBROSIS AND NECROSIS OF DIABETIC WOUND HEALING	
<b>Amy Nindia Carabelly, Juliyatin Putri Utami, Didit Aspriyanto, Muhammad Hasanu Reksi, Dewi Puspitasari, Priyawan Rachmadi .....</b>	<b>171-176</b>
RISK FACTORS OF ANGULAR CHEILITIS AT GUSTI HASAN AMAN DENTAL HOSPITAL SOUTH KALIMANTAN	
<b>Aulia Azizah, Selviana Rizky Pramitha, Maharani Laillyza Apriasari.....</b>	<b>177-182</b>
REHABILITATION OF MASTICATION AND LACK OF SPACE TREATMENT IN NARROW EDENTULOUS WITH FIXED-FIXED BRIDGE	
<b>Rahmad Arifin, Fitriana Caessar Pertiwi.....</b>	<b>183-189</b>
THE EFFECT OF LACTIC ACID AND ARTIFICIAL SALIVA SOLUTION IMMERSION TO THE RELEASE OF CALCIUM IONS ON BIOACTIVE RESIN	
<b>Dewi Puspitasari, Nurah Tajjalia, Diana Wibowo, Agung Satria Wardhana.....</b>	<b>190-194</b>

ODONTECTOMY MANAGEMENT WITH LOCAL ANESTHESIA IN PATIENT WITH OPEN-ANGLE GLAUCOMA <b>Bramasto Purbo Sejati, Bambang Dwiraharjo, Elizabeth Riyati Titi Astuti</b> .....	195-200
COMPARISON OF APICAL LEAKAGE VALUE BETWEEN EUCALYPTOL AND ORANGE OIL AS GUTTA PERCA SOLVENT <b>Sherli Diana, Rizki Sri Yuliati, Bayu Indra Sukmana</b> .....	201-204
THE EFFECTIVENESS OF COMPOMER AND GIC AGAINST PREVENTION IN ENAMEL DEMINERALIZATION <b>Fadil Abdillah Arifin, Yustisia Puspitasari, Nur Rahmah Hasanuddin, M. Fajrin Wijaya, Sari Aldilawaty</b> .....	205-208
MANAGEMENT OF SEVERE XEROSTOMIA AND ORAL CANDIDIASIS IN PATIENT WITH VALVULAR HEART DISEASE: A CASE REPORT <b>Helen Christine, Tenny Setiani Dewi, Wahyu Hidayat</b> .....	209-215
THE DIFFERENCES OF SALIVARY VOLUME, pH AND ORAL CONDITIONS BETWEEN MENOPAUSAL AND NON-MENOPAUSAL WOMEN <b>Rosita Aisyah, Sri Tjahajawati, Anggun Rafisa</b> .....	216-222
COMPLICATIONS OF RECONSTRUCTION PLATE INSTALLATION IN MANDIBULAR <b>Leni Ruslaini, Asri Arumsari, Abel Tasman, Kiki Akhmad Rizki</b> .....	223-228

**DENTINO**  
**JURNAL KEDOKTERAN GIGI**  
**Vol VI. No 2. September 2021**

**THE COMPARISON OF RAMANIA (*Bouea macrophylla Griff*) AND BINJAI (*Mangifera caesia*) LEAVES EXTRACT GEL EFFECT ON COLLAGEN DENSITY**

**Nabilah<sup>1)</sup>, Irham Taufiqurrahman<sup>2)</sup>, Nolista Indah Rasyid<sup>3)</sup>**

<sup>1)</sup> Faculty of Dentistry, Lambung Mangkurat University, Banjarmasin Indonesia

<sup>2)</sup> Department of Oral and Maxillofacial Surgery, Faculty of Dentistry, Lambung Mangkurat University, Banjarmasin Indonesia

<sup>3)</sup> Department of Orthodontics, RSGMP Gusti Hasan Aman Provinsi Kalimantan Selatan, Banjarmasin Indonesia

**ABSTRACT**

**Background:** The extract of ramania *Bouea macrophylla Griff* and binjai (*Mangifera caesia*) leaf have flavonoid compounds that function as antioxidants to balance the amount of Reactive Oxygen Species (ROS) in tissues and optimize wound healing by helping synthesis of hydroxyproline which is used as a collagen synthesis material. **Objective:** To compare the effect of 15% concentration of ramania leaf extract gel, 15% concentration of binjai leaf extract gel on collagen density in back incision wounds of male Wistar rats on day 7 and day 14. **Methods:** This study used a true experimental design with a posttest-only with control group design. The study sample used male wistar rats that were healthy and active, aged 2-3 months with a body weight of 250-300 grams. The total sample was 18 rats divided into 6 groups. The 15% concentration of ramania and binjai leaves was given topically, then the rats were euthanized on the 7th and 14th day. Collagen index measurement was using hydroxyproline concentration. **Results:** *Two-way Anova* data analysis showed a significant value of 0.00 ( $p < 0.05$ ), which means that there was a difference in effect between the treatment gel and wound day. *Bonferroni Post Hoc* test showed a significant value in all treatment gel groups. **Conclusion:** There is a difference in the effect of 15% concentration of ramania leaf extract gel and 15% concentration of binjai extract gel on collagen density. Binjai leaf extract gel at 15% concentration is more effective for collagen density than Ramania leaf extract at 15% concentration and placebo.

**Keywords :** Binjai Leaf Extract Gel, Collagen, Hydroxyproline, Ramania Leaf Extract Gel.

**Correspondence:** Nabilah, Faculty of Dentistry, University of Lambung Mangkurat, Jl. Veteran Sungai Bilu No. 128, Melayu, Central Banjarmasin District, Banjarmasin City, South Kalimantan 70122, Indonesia; E-mail: [nabilah53111@gmail.com](mailto:nabilah53111@gmail.com).

**INTRODUCTION**

Tooth extraction is the most commonly performed procedure in dentistry. Tooth extraction itself will cause injury to the oral mucosa. The number of injuries due to surgery and due to trauma continues to increase every year. According to Riskesdas in 2018, injuries due to tooth extraction in South Kalimantan reached 8.5% and injuries due to oral surgery reached 0.1%.<sup>1</sup> Normally, the wound healing process consists of three phases, namely the inflammatory phase, the proliferation phase and the remodeling phase.<sup>2</sup> In the remodeling phase, collagen will be formed. Collagen is the most abundant protein in the extracellular matrix of the skin and functions to fill the extracellular matrix.<sup>2</sup> Collagen that is

previously formed will be converted into procollagen. In the procollagen chain, there are residual proline and lysine which are converted into hydroxyproline and hydroxylysine assisted by proline enzymes and lysyl hydroxylase and enzyme cofactors namely vitamin C. Both reactions also require  $Fe^{2+}$ ,  $O_2$  and  $\alpha$ -ketoglutarate. Collagen comes from the bond between hydroxyproline and hydroxylysine in the hydroxylation process.<sup>3</sup> The higher the concentration of hydroxyproline, the higher the escalation of collagen synthesis which can help in the wound healing process.<sup>4</sup>

In the wound healing process, sometimes there are factors that hinder the process. Therefore, companion therapy or adjuvant therapy is needed

in wound care management. On the healing process, adjuvant therapy is given to help delayed wound healing and optimize the wound healing process to produce good results.<sup>5</sup>

One of the plants that can be used as adjuvant therapy is ramania (*Bouea macrophylla Griff*) and binjai (*Mangifera caesia*) leaves. Ramania plants have oval-shaped leaves and are usually used as vegetable.<sup>6</sup> Ramania leaves have secondary metabolite compounds in the form of flavonoids, steroids, phenols, alkaloids and terpenoids.<sup>7</sup> Binjai plants are 30-40 m tall with yellow to brown oval fruit.<sup>8</sup> Binjai leaves contain other secondary metabolite compounds in the form of flavonoids, phenols, tannins, alkaloids, saponins and triterpenoids. Flavonoids can act as antioxidants. Flavonoids will help reduce levels of Reactive Oxygen Species (ROS) so that oxygen levels in the tissue can return and optimize collagen synthesis.<sup>9</sup>

The previous research on binjai leaves given topically in the form of extracts has been shown to have an effect on the number of neutrophil cells in the wound healing process.<sup>10</sup> The application of drugs to the skin and mucosa can be more optimal if the extract is made into gel preparation. Gel preparations are medicinal preparations that are often used for topical administration. The choice of gel preparations was made because gels can provide a high rate of drug release and can be absorbed quickly.<sup>11</sup>

In this study, the researchers wanted to compare the effect of 15% concentration of ramania leaf extract gel and 15% concentration of binjai extract gel on collagen density on day 7 and day 14 in incision wounds of male Wistar rats. This study aims to analyze the effect of 15% concentration of Ramania leaf extract gel, Binjai leaf extract gel concentration of 15% on collagen density in incision wounds of male wistar rat back on the 7th and 14th days.

## RESEARCH METHODS

After passing the ethics feasibility test by the Faculty of Dentistry, Lambung Mangkurat University No. 065/KEPKG-FKGULM/EC/I/2020, the research was conducted in February-April 2020 using a true experimental design with a posttest-only design with control group design. The study sample used male wistar rats that were healthy and active, aged 2-3 months with a body weight of 250-300 grams.

The technique of determining the number of samples based on the numerical comparative formula is not paired more than two groups, the sample size was 18 rats for 6 treatment groups. The treatment group consisted of a group given a placebo gel on day 7, a group given a placebo gel on day 14, a group given ramania leaf extract gel

with a concentration of 15% on the 7th day, a group given a ramania leaf extract gel with a concentration of 15% on 14th day, the group given binjai leaf extract gel with a concentration of 15% on the 7th day and the group given binjai leaf extract gel with a concentration of 15% on the 14th day.

### **The making of ramania leaf extract gel at the concentration of 15%**

Ramania leaves were dried in an oven at 50°C for 4 hours. The leaves were then made in the form simplicia and macerated using 95% ethanol to obtain a thick pure ramania leaf extract. The extract was then dissolved in distilled water for 15 minutes and left for 24 hours. HPMC, Propylene Glycol, Tween 80 and candy oil were added to the extract to produce a 15% concentration of ramania leaf extract gel.

### **The making of binjai leaf extract gel at the concentration of 15%**

Binjai leaves were dried at room temperature 25-30°C for 4 days without exposure to sunlight. Leaves that had been made into simplicia was macerated with 70% ethanol to obtain a pure thick extract of binjai leaves. The extract was then dissolved in distilled water for 15 minutes and left for 24 hours. Ingredients for making gel preparations were added, namely HPMC, Propylene Glycol, Tween 80 and candy oil.

### **Treatment of experimental animals**

The incision wound on the back of the rat was made 2 cm long with subcutis depth. On the 7th day and the 14th day, the rat was euthanized intraperitoneally with ketamine-xylazine. Then the back incision wound was biopsied with 1 cm length, 1 cm width and subcutis depth.

### **Homogenate preparation**

The biopsy results were dried in the oven for 12-18 hours at a temperature of 60-70°C. The results of the biopsy that have been dried will be added with 1 ml of 6M HCL every 10 mg. The homogenate was then incubated in boiled water for 4 hours to be hydrolyzed. The results from the hydrolysis were then centrifuged at 3000 rpm for 15 minutes and 1 ml of the collected supernatant was transferred into the test tube. The supernatant is lyophilized using a nitrogen gas stream. Lyophilized samples were stored at -40°C until analysis. The determination of the hydroxyproline content of the sample tissue was carried out according to the method of Stegemann and Stalder (1967). The hydrolyzate was diluted twice with 2 ml buffer solution. The diluted sample was added to the chloramine T solution at 4°C. 20 minutes later, 1 ml of Ehrlich's reagent was added and mixed until a chromotor compound was obtained, that is, the color of the solution turned pink and no schlieren (transparent layer) was formed in the

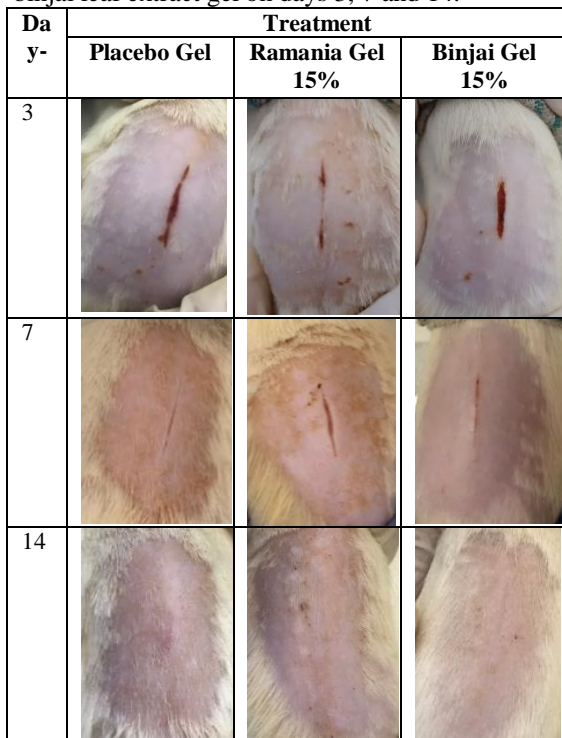
solution until the color change is stable for 30 minutes.

**Measurement of hydroxyproline concentration**

The absorbance of the solution was then measured at 550 nm wavelength and the hydroxyproline level in the sample was extrapolated using the standard hydroxyproline curve that was obtained using a UV-VIS spectrophotometer.

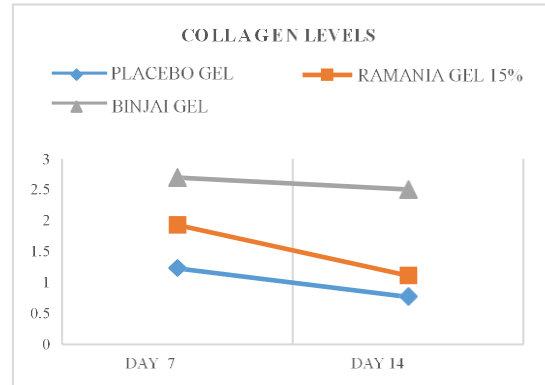
**RESULT**

The results in Figure 1 show the macroscopic appearance of wound healing by administering placebo gel, 15% ramania leaf extract gel and 15% binjai leaf extract gel on days 3, 7 and 14.



**Figure 1.** Macroscopic View of Wistar Rat Incision Wounds

In the picture above, it can be seen that on the 3rd day the wounds treated with placebo, 15% ramania leaf extract gel and 15% binjai leaf extract gel showed reddish wounds but were dry. On the 7th day, the redness on the wound had disappeared and left a scar. By day 14, the wound was closed, scarred, and there was no sign of thickening in the wound and mouse hair began to grow in the area that had been shaved.



**Figure 2.** Diagram of Average Collagen Levels in Wistar Rat Wounds

The graphic image of collagen levels above is obtained from the results of measuring the concentration of hydroxyproline in the incision wound of wistar rats.

**Table 1.** Descriptive Data of Research Results

Treatment	Wound Day	Average	Standard Deviation	No of Sampel
Placebo Gel	Day 7	1,238	0,004	3
	Day 14	0,777	0,004	3
	Total	1,007	0,252	6
Ramania Gel 15%	Day 7	1,935	0,026	3
	Day 14	1,117	0,006	3
	Total	1,525	0,448	6
Binjai Gel 15%	Day 7	2,701	0,020	3
	Day 14	2,509	0,101	3
	Total	2,605	0,124	6
Total	Day 7	1,958	0,634	9
	Day 14	1,468	0,796	9
	Total	1,713	0,742	18

Figure 1 and table 1 show the average levels of collagen in wistar rats in each treatment group on days 7 and 14. The average collagen levels increased on day 7 and decreased on day 14. Based on the figure and table, the highest increase of collagen levels on day 7 consecutively was the binjai leaf extract gel group with a concentration of 15% (2,701 µg/mL), 15% concentration of ramania leaf extract gel (1,934 µg/mL) and placebo gel (1,238 µg/mL). The lowest reduction of collagen levels on the 14th day in a row was the placebo gel group (0,777 µg/mL), extract gel 15% ramania leaf (1,117 µg/mL) and 15% binjai leaf extract gel (2,509 µg/mL).

Data analysis to test the distribution of data was performed using the Shapiro-Wilk normality test. Based on the normality test, it is obtained that the significant value was greater than 0.05 (p>0.05), which means that the data distribution was normally distributed. After the data was normal, data analysis was continued using the homogeneity test. The resulting significant value was less than 0.05 (p>0.05), which means that the research data was stated to be homogeneous. Data analysis was then continued using the *Two-way Anova* parametric analysis with 95% accuracy.



**Table 2.** Two-way Anova Analysis

Source	Mean Square	Significant Value
Treatment	3.987	0.000
Wound Day	1.080	0.000
Treatment*Wound Day	0.148	0.000

In the table above, the significant value of the treatment group is 0.00 ( $p < 0.05$ ), which means that there was a significant difference in collagen levels between the placebo group, 15% ramania and 15% binjai. The significant value of the wound day group was  $0.00 < 0.05$ , which means that there was a significant difference in collagen levels between the 7th and 14th day wound groups. The significant value of the treatment group and wound day was  $0.00 < 0.05$ , which means that there were significant differences in interaction between the treatment group and wound day.

The analysis was then continued with the *Post Hoc Bonferroni* test to determine which gel group had statistically significant differences.

**Table 3.** *Post Hoc Bonferroni* Value of Collagen Density in terms of Treatment Group

(I) Concentration	(J) Concentration	Mean Difference (I-J)	Sig. Value
Placebo	Ramania 15%	-0.519	0.000
	Binjai 15%	-1.598	0.000
Ramania 15%	Placebo	0.519	0.000
	Binjai 15%	-1.080	0.000
Binjai 15%	Placebo	1.598	0.000
	Ramania 15%	1.080	0.000

Table 3 shows all the significant numbers show the number 0.00, therefore the mean difference can infer which extract is better. Comparison of collagen levels between placebo gel and 15% concentration of ramania leaf extract gel resulted in a significant value of 0.00 ( $p < 0.05$ ) so that it can be stated that there is a significant difference in collagen levels between placebo gel and 15% concentration of ramania leaf extract gel. The mean difference which shows a negative value indicates that the collagen content test with a 15% concentration of ramania leaf extract gel is better than the placebo gel.

Comparison of collagen levels between placebo gel and binjai leaf extract gel with a concentration of 15% resulted in a significant value of 0.00 ( $p < 0.05$ ), so it can be stated that there was a significant difference in collagen levels between placebo and binjai leaves with a concentration of 15%. The mean difference, which shows a negative value, indicates that the collagen level test of incision wound with the application of 15% binjai leaf extract gel is better than the placebo gel.

Comparison of collagen levels between 15% ramania leaf extract gel and 15% binjai leaf extract gel resulted in a significant value of 0.00 ( $p < 0.05$ ),

so it can be stated that there is a significant difference in collagen levels between 15% concentration of ramania leaf extract gel and binjai leaf extract gel. The mean difference value which shows a negative value indicates that the result of collagen content test in the group given 15% concentration of binjai leaf extract gel is better than the group given 15% concentration of ramania leaf extract gel.

## DISCUSSION

The results of the comparison of ramania (*Bouea macrophylla Griff*) and binjai (*Mangifera caesia*) leaves extract gel effect on collagen density of wistar rats incision wounds showed that there was a significant difference ( $p < 0.05$ ) between placebo gel, ramania leaf extract gel 15% and binjai leaf extract gel 15% against collagen density on day 7 and day 14. Collagen is the predominant extracellular protein in granulation tissue in the wound healing process. Collagen will increase rapidly in the wound area after injury and provide strength to the tissue matrix. The research method of measuring hydroxyproline is used because hydroxyproline comes from the breakdown of collagen and can be used as a substitute index for collagen measurement. The results of the research on ramania and binjai leaf extract gel showed that the concentration of hydroxyproline was higher than the control group. These results indicate that the ramania and binjai leaf extract gel have a better effect on wound healing because the hydroxyproline content indicates a higher collagen in the granulation tissue and an increase in the tensile strength of the treated wound so that wound healing can run optimally.<sup>12</sup>

The results of the study in Figure 2 and table 1 show that the average collagen level on the 7th day was 1,958  $\mu\text{g/mL}$ . Collagen level on the 7th day was increased if contrasted with the average collagen level on the 14th day of 1,468  $\mu\text{g/mL}$ . These results are consistent with a research on wound healing that was given ethanol extract of noni leaves (*Morinda citrifolia L.*) to the incision wound of wistar rats in terms of collagen thickness on days 3, 7 and 14. The results of the study stated that there was an increase of collagen from day 3 towards day 7.<sup>13</sup> This occurs because on day 5, neovascularization reaches its peak when granulation tissue fills the incision space. Granulation tissue that is formed progressively accumulates more fibroblasts which will later form collagen. Collagen fibrils become more numerous and begin to bridge the wound incision. The epidermis restores its normal thickness by differentiating surface cells which produce an epidermal layer by keratinization.<sup>14</sup>

The results of the study in Figure 2 and table 1 show an increase in collagen levels on the 7th day respectively, namely the binjai leaf extract gel group of 15% (2,701 µg/mL), 15% ramania leaf extract gel (1,934 µg/mL) and placebo gel (1,238 µg/mL), which means that the 15% ramania leaf extract gel was more effective in increasing collagen levels than the placebo gel on day 7. This may occur because the Ramania plant contains secondary metabolites in the form of flavonoids, phenols, terpenoids, steroids and alkaloids. The function of flavonoids itself as an antioxidant will help reduce levels of Reactive Oxygen Species (ROS) so that oxygen levels in the tissues can return and optimize the formation of hydroxyproline which requires oxygen. These results are in accordance with a research on wound healing using the flavonoid fraction derived from ethanol extracts of *Butea monosperm (Lam)* bark in incision wounds of albino wistar rats. These studies show that flavonoids can increase wound contraction and hydroxyproline concentration by increasing collagen fiber cross-linking and increased granuloma tissue associated with increased collagen maturation and increased protein levels and angiogenesis.<sup>9</sup> Flavonoids are powerful antioxidants which play a role in protecting the body against ROS and increase the function of endogenous antioxidants by activating nuclear factor erythroid-2 related-factor 2 (Nrf<sup>2</sup>) which will induce the synthesis of endogenous antioxidant enzymes.<sup>15</sup> When there is a balance between ROS and the antioxidant system, this will have a good impact on wound healing because oxygen plays an important role in wound healing such as regulating angiogenesis and promoting cell proliferation. Oxygen is also a prerequisite for the synthesis of hydroxyproline which is used as a synthesis of collagen. Collagen synthesis and hydroxyproline activity will increase in the presence of oxygen.<sup>16</sup> In addition, the alkaloid content in ramania leaf extract is useful so that fibrin in collagen will be formed stronger. The combination with the content of terpenoids will act as an adstringent and antimicrobial to help the reepitalization process in injured fingers.<sup>17</sup> Ramania leaf extract also contains steroids that have antibacterial potential by lysing cell membranes. The lysis occurred as steroids can interact with phospholipid membranes of the bacterial cells which are impermeable to lipophilic compounds.<sup>18</sup>

Based on the results of the research in Figure 2 and table 1, the collagen content of 15% binjai leaf extract gel on the 7th day showed the highest average compared to 15% ramania leaf extract gel on the 7th day and placebo gel on the 7th day. The increasing levels of collagen in the 7th day were

15% binjai leaf extract gel (2,701 µg/mL), 15% ramania leaf extract gel (1,934 µg/mL) and placebo gel (1,238 µg/mL). This is probably because the binjai leaf extract gel contains saponins that ramania leaf extract gel does not. These results are in accordance with a research investigating the effect of wound healing in wistar rats on the thickness of collagen fibers that was given caramunting leaf ointment which contains flavonoids and saponins.<sup>3</sup> Saponins can stimulate fibronectin synthesis by fibroblasts and stimulate TGF-β. Fibronectins are found in the early phase of wound healing and induce fibroblast migration. Fibroblasts will be used in the next phase of wound healing to produce collagen.<sup>6</sup> Binjai plants also have secondary metabolites in the form of triterpenoids. Triterpenoids have the ability as a burn medicine, antinociceptic and anti-inflammatory.<sup>19</sup>

On the results of the study on day 14, there was a decrease in collagen levels compared to the 7th day. Based on Figure 2 and Table 1, the average collagen level on the 7th day was 1,958 µg/mL then decreased on the 14th day, so that the average collagen level on the 14th day was 1,468 µg/mL. This is consistent with the research on wound healing process after tooth extraction in guinea pigs using 45% and 90% aloe vera extract (*Aloe barbadensis Miller*) which contain saponins, vitamin C and *acemannan* on the density of collagen fibers. The results of this study using 90% aloe vera extract demonstrated that there was an increase in collagen fibers on the 7th day and a decrease on the 14th day.<sup>20</sup> This probably occurred because the proliferation of fibroblasts and collagen synthesis lasted for two weeks. The final amount of collagen depends not only on collagen synthesis, but also on its degradation. The balance between collagen synthesis and tissue degradation forms a normal wound healing process. This balance occurs between the two for up to 3 weeks after the injury before finally stabilized<sup>21</sup>

In Figure 2, it can be seen that the decrease in the collagen content of ramania leaf extract gel from the 7th day of 1,934 µg/mL to the 14th day is 1,117 µg/mL. A decrease was also observed in binjai leaf extract gel group which presented collagen content from 2,701 µg/mL on the 7th day to 2,509 µg/mL on the 14th day. In this figure, it can be seen that the decrease in collagen levels in the binjai group from day 7 to day 14 is not as much as ramania leaf extract gel. This is probably due to the saponin content in binjai which stimulates TGF-β. TGF-β will inhibit collagen degradation by inhibiting metalloproteinase secretion. Metalloproteinase activity will be inhibited by increasing the activity of Tissue Inhibitors of Metalloproteinase (TIMP) by TGF-

$\beta$ .<sup>22</sup> Binjai also has tannin content which can serve as an effect of stabilizing collagen and reducing the formation of scar tissue.<sup>23</sup> In table 1 as the final result of this study, the normal scar tissue was formed. The wounds were barely visible and there were no signs of excessive thickening of the wound, even rat hair has begun to grow in the area that had been shaved. The formation of abnormal scar tissue can occur when there is an infection so that the inflammatory process will take longer. The wound will get longer and deeper as well. This can result in excessive collagen synthesis. The end result for the imbalance between collagen secretion and its degradation may be in the form of scar tissue that can be classified into several forms, namely hypertrophic scars, keloids, atrophic scars, widened scars and contractures.<sup>24</sup>

Based on the results of research and statistical data, there are differences in the influence of ramania leaf extract gel (*Bouea macrophylla* Griff) at 15% concentration and binjai (*Mangifera caesia*) at 15% concentration on collagen density in the back incision wounds of male wistar rats that increased on day 7 and decreased on day 14. Based on the statistical results, 15% binjai leaf extract gel (*Mangifera caesia*) has greater effect on collagen density than 15% ramania leaf extract gel (*Bouea macrophylla* Griff) and placebo.

## REFERENCES

1. Kementerian Kesehatan Republik Indonesia. Riset Kesehatan Dasar 2018. Jakarta: Badan Penelitian Pengembangan Kesehatan Departemen Kesehatan Republik Indonesia; 212-215.
2. Kiya, K. and Kubo, T. 2019. Neurovascular Interactions In Skin Wound Healing. *Neurochemistry International*. 125: 144-150.
3. Nugraha, G.A.F. 2016. Efek Pemberian Ekstrak Etanol 70% Daun Karamunting (*Rhodomyrtus tomentosa* (Aiton) Hassk) Topikal terhadap Gambaran Histopatologi Ketebalan Serat Kolagen Penyembuhan Luka Insisi Kulit Tikus Putih Galur Wistar. *Jurnal Mahasiswa PSPD FK Universitas Tanjungpura*. 5(1): 5-13
4. Rismana, E., Rosidah, I. and Bunga, O. 2013. Efektivitas khasiat pengobatan luka bakar sediaan gel mengandung fraksi ekstrak pegagan berdasarkan analisis hidrosiprolin dan histopatologi pada kulit kelinci. *Buletin Penelitian Kesehatan*. 41(1): 45-60.
5. Burotto, M., Wilkerson, J., Stein, W., Bates, S.E. and Fojo, T. 2019. Adjuvant and neoadjuvant cancer therapies: A historical review and a rational approach to understand outcomes. *Seminars in oncology*. 46 (1): 83-99
6. Harsono T. 2017. Tinjauan Ekologi Dan Etnobotani Gandaria. *Jurnal Biosains*. 3 (2): 119-124.
7. Aryzki, S. and Susanto, Y. Skrining Fitokimia Ekstrak Daun Ramania (*Bouea macrophylla* Griffith) Asal Kalimantan Selatan. In Proceeding of Sari Mulia University Pharmacy National Seminars. 2019 December. 1(1): 76-85.
8. Rosyidah, K., Latifah, N. and Astuti, M.D. 2011. Isolasi Dan Karakterisasi Senyawa A-Amirin Dari Kulit Batang Binjai (*Mangifera caesia*). *Jurnal Kimia Valensi*. 2(2): 389-392.
9. Muralidhar, A., Babu, K.S., Sankar, T.R., Reddanna, P. and Latha, J. 2013. Wound healing activity of flavonoid fraction isolated from the stem bark of *Butea monosperma* (Lam) in albino wistar rats. *European Journal of Experimental Biology*. 3(6): 1-6.
10. Dwiyanti, D.A., Taufiqurrahman, I. and Aspriyanto, D., 2020. HE Effect Of Binjai Leaves Extract (*Mangifera caesia*) On Incisional Back Wound Of Mice (*Mus Musculus*) To The Number Of Neutrophil Cells (Preliminary Study of Drug Preparations for Wound Healing). *Dentino*. 5(1): 21-27.
11. Elmitra. 2017. Dasar-dasar Farmasetika dan Sediaan Semi Solid. Deepublish. Yogyakarta. p. 155-158.
12. Latif, M.A., Zaki, M.Z.M., Leng, T.M., Rahman, N.H.A., Arshad, S.A. and Hamid, A. 2015. *Alocasia denudata* Engler treatment enhance open wound healing activities in Wistar rat's skin. *Journal of ethnopharmacology*. 176: 258-267.
13. Maskoen, A.M. and Hernowo, B.S. 2013. Peran Ekstrak Etanol Topikal Daun Mengkudu (*Morinda Citrifolia* L.) Pada Penyembuhan Luka Ditinjau Dari Imunoekspresi Cd34 Dan Kolagen Pada Tikus Galur Wistar. *Majalah Kedokteran Bandung*. 45(4): 226-233.
14. Kumar, V., Cotran, R.S. and Robbin, S.R. Robbins. 2013. Buku Ajar Patologi Edisi 8. Elsevier Saunders. Singapura. p. 70-72.
15. Li, Y.R., Li, G.H., Zhou, M.X., Xiang, L., Ren, D.M., Lou, H.X., Wang, X.N. and Shen, T. 2018. Discovery of natural flavonoids as activators of Nrf<sup>2</sup>-mediated defense system: Structure-activity relationship and inhibition of intracellular oxidative insults. *Bioorganic & medicinal chemistry*. 26(18): 5140-5150.
16. Patil, P.S., Fountas-Davis, N., Huang, H., Evancho-Chapman, M.M., Fulton, J.A., Shriver, L.P. and Leipzig, N.D., 2016. Fluorinated methacrylamide chitosan hydrogels enhance collagen synthesis in

- wound healing through increased oxygen availability. *Acta biomaterialia*. 36: 164-174.
17. Cahyani, Y.D. and Mita, S.R. 2018. Aktivitas Biologis Tanaman Bandotan (*Ageratum conyzoides* Linn.) sebagai Terapi Luka Terbuka. *Farmaka*. 16(2): 125-133.
  18. Firdiyani, F., Agustini, T.W. and Ma'ruf, W.F. 2015. Ekstraksi senyawa bioaktif sebagai antioksidan alami *Spirulina platensis* segar dengan pelarut yang berbeda. *JPHPI*. 18(1): 28-37.
  19. Risma, E., Rosidah, I. and Bunga, O. 2013. Efektivitas khasiat pengobatan luka bakar sediaan gel mengandung fraksi ekstrak pegagan berdasarkan analisis hidrosiprolin dan histopatologi pada kulit kelinci. *Buletin Penelitian Kesehatan*. 41(1): 45-60.
  20. Yuza, F., Wahyudi, I.A. and Larnani, S. 2014. Efek Pemberian Ekstrak Lidah Buaya (*Aloe Barbadensis* Miller) pada Soket Gigi terhadap Kepadatan Serabut Kolagen Pasca Ekstraksi Gigi Marmut (*Cavia Porcellus*). *Majalah Kedokteran Gigi Indonesia*. 21(2): 127-135.
  21. Primadina, N., Basori, A. and Perdanakusuma, D.S. 2019. Proses Penyembuhan Luka Ditinjau Dari Aspek Mekanisme Seluler Dan Molekuler. *Qanun Medika-Medical Journal Faculty Of Medicine Muhammadiyah Surabaya*. 3(1): 31-43.
  22. Dewi, A.K. 2019. Pembentukan Kolagen Dalam Menentukan Kualitas Penyembuhan Luka. *Majalah Biomorfologi*. 25(1): 17-20.
  23. Nikita, S. and Meera, B. 2014. Stabilization Of Collagen By Its Interaction With Tannin Extracted From *Punica Granatum*. *International Journal Of Engineering Research And Technology*. 3(7): 479-81.
  24. Isrofah, I., 2015. Efektifitas Salep Ekstrak Daun Binahong (*Anredera Cordifolia* (Ten) Steenis) Terhadap Proses Penyembuhan Luka Bakar Derajat 2 Termal pada Tikus Putih (*Rattus Novergicus*). *IJNP (Indonesian Journal of Nursing Practices)*. 2(1): 27-39.