

Potential of Karamunting Leaves as Nephroprotective in Diabetic rat Model

Ida Yuliana^{1*}, Asnawati², Maria Ulfah³

^{1*} Department of Biomedics, Histology Division, Faculty of Medicine, Lambung Mangkurat University

² Department of Biomedics, Histology Physiology Faculty of Medicine, Lambung Mangkurat University

³ Departement of Biomedics, Biology Division, Faculty of Medicine, Lambung Mangkurat University

E-mali: Correspondence author:iyuliana@ulm.ac.id

Abstract

Background: Diabetes mellitus can cause cell death in kidney and Karamunting leaves has been using by folk of as a medicine for diabetes mellitus. Objectives: Study aimed to prove ethanolic extract of karamunting leaves as nephroprotective by improved kidney histomorphology in diabetic rat's model. Methods: Method used true experimental design with posttest control group. Study observed histomorphology of 30 kidneys diabetic rats was divided into 4 groups, namely control group (K), and treatment groups (P) are diabetic rats model administration of ethanol extract karamunting leaves with different doses P1 (100 mg/kgBW), P2 (200 mg/kgBW) and P3 (400 mg/kgBW). Observation data used Optilab Image Raster application taken by Optilab Camera. Results: Studies showed results for diameter glomerular, and tubules kidney lumen significant difference between control and treatment groups ($p = 0.013$; $p = 0.000$). Research results for number tubules kidney shown significant difference between control and treatment groups ($p = 0.001$). Administration of ethanol extract of karamunting leaves for 14 days of treatment made improvement in glomerular enlargement, tubular wall thickening and increase number of tubules. Conclusions: ethanol extract karamunting leaves had potential as a nephroprotective in diabetic rat model

Keyword: Diabetec, Karamunting Leaves, Glomerular, Tubules, Kidney

1. Introduction

Diabetes mellitus is a metabolic disease characterized by a systemic disorder of glucose regulation that causes the accumulation of glucose in the blood and tissues as a result of a relative or absolute lack of insulin in the body.¹ The main microvascular complication for patients with type 2 diabetes is diabetic nephropathy (ND). Diabetic nephropathy occurs due to glomerular damage so that a number of blood proteins are excreted into the urine abnormally which causes end-stage kidney disease and chronic kidney disease which is a nephrotic syndrome. Diabetic nephropathy occurs due to glomerular damage so that a number of blood proteins are excreted into the urine abnormally which causes end-stage kidney disease and chronic kidney disease which is a nephrotic syndrome.² Diabetic nephropathy is caused by overproduction of free radicals. In addition, chronic hyperglycemia conditions will increase the number of free radicals in cells and will be toxic, causing oxidative stress that produces Reactive Oxygen Species (ROS). One of the managements of ND is the use of antioxidants to reduce ROS production.^{3,4} One of the uses of herbal ingredients that are widely used by the community to treat diabetes mellitus is the Karamunting plant which is usually used by the people of Kalimantan as a drug to lower blood sugar levels.^{5,6} The results showed that karamunting

leaves contain phenolic compounds, flavonoids, saponins, tannins, steroids and triterpenoids.^{7,8} This study was conducted to prove the potential of karamunting leaves as an antidiabetic in repairing kidney histomorphological damage affected by hyperglycemia.

2. Materials and Method

This study design used a true experimental with post-test control groups: a control group (C) and three treatment groups (P). All the animals were streptozotocin (STZ) induced at a 40 mg/kgBW dose intraperitoneally. Rats were considered diabetic when blood glucose levels were more than 180 mg/dl. Treatment with karamunting leaf extract were given 100 mg/kgBW (P1), 200 mg/kgBW (P2), and 400 mg/kgBW (P3). This study has received ethical approval from The Ethical Committee of Health Medical Study Medical Faculty, University of Lambung Mangkurat No. 576/KEPK-FK ULM/EC/VI/2021. Plant determination and extraction Determination of karamunting plants was conducted in the Laboratory of the Department of Biology, Faculty of Mathematics and Natural Sciences, University of Lambung Mangkurat. Samples of herbarium leaf parts from karamunting plants are collected from the Wetland Martapura area, South Kalimantan. The karamunting leaves ethanolic extract was conducted in the Laboratory of Pharmacology and Treatment, Faculty of Medicine,

University of Lambung Mangkurat. Karamunting leaves cleaned, dried, blended and then macerated with ethanol 96 % until obtained thick extract. The histomorphological changes of the kidney were observed quantitatively. The parameters analysed included glomerular dan tubule. Imaging of each structure was performed at 400x magnification. Histomorphologic kidney were examined under a binocular light microscope in five fields of view (top, middle, right middle, left middle, and bottom). The size and number that compile the kidney were measured using raster image software. The size measurement of kidney was carried out by measuring each glomerular dan tubules kidney shortest and longest diameters. Data analysis the histomorphological measurement of the kidney size was analysed with an ANOVA test.

3. Result

Table 1. Histomorphological measurement of kidney - diameter glomerulus and tubules lumen size

Groups	Diameter Glomerulus and Tubules Lumen Size (nm)			
	Glomerulus	P value	Tubules	P value
Control (C)	77.42±14.30	0.013*	12.33±3.32	0.000*
100 mg (P1)	81.00±4.60		10.57±1.33	
200 mg (P2)	68.94±20.70		77.31±3.11	
400 mg (P3)	78.58±10.25		54.68±2.29	

Note: * p < 0.05, a compared with control group

Table 2. Histomorphological measurement of the kidney - number of glomerulus and tubules

Group	Number			
	Glomerulus	P value	Tubules	P value
Control (C)	3.79±1.43	0.17	46.33±10.55	0.001*
100 mg (P1)	4.75±1.78		88.41±13.71	
200 mg (P2)	4.43±2.63		77.31±29.20	
400 mg (P3)	4.20±1.25		54.68±19.17	

Note: * p < 0.05, as compared with control group

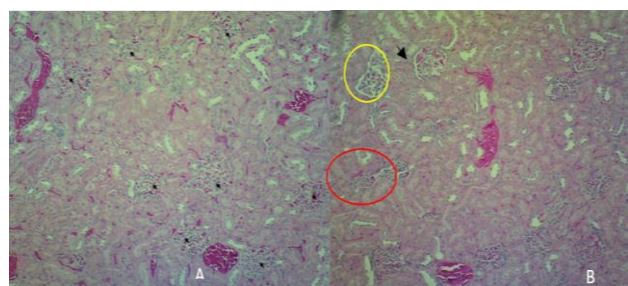


Figure 1. Description of the number of a glomerulus control (A) and treatment (B) groups. The black arrow is a countable glomerulus; the red circle is the glomerulus that cannot be counted because the glomerulus is fragmented, the boundary between the parietal stratum and the stratum visceralis is not visible, and the glomerular structure is not intact; the glomerulus atrophy due to adhesions; HE is staining. Magnification 100x.

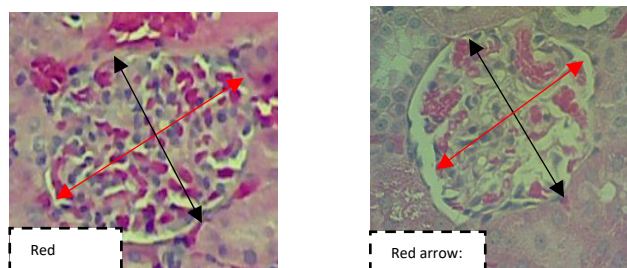


Figure 2. Description of glomerular diameter for (A) control and treatment groups (B). HE staining.

Magnification 400x.

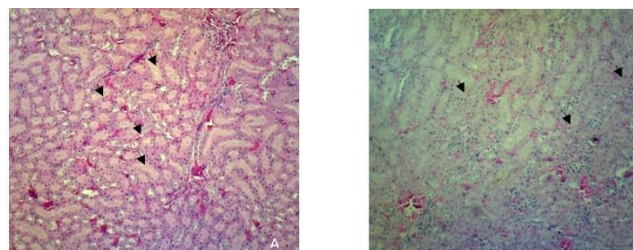


Figure 3. Description of number tubules kidney (A) control and treatment groups (B). The black arrow is countable tubules; HE is staining. Magnification 100x.

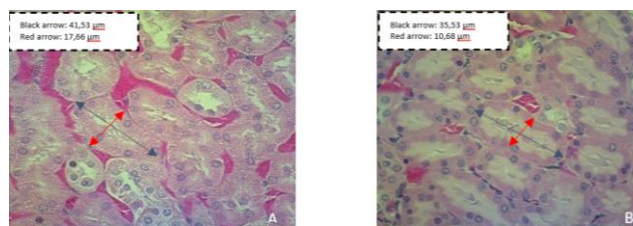


Figure 4. Microscopic analysis of kidney tubules lumen diameter on control (A) and treatment (B) groups.

HE is staining. Magnification 400x.

4. Discussion

Prolonged hyperglycemia can cause tissue damage and lead to various complications such as retinopathy, atherosclerosis, neuropathy, cardiomyopathy, and diabetic nephropathy. Hyperglycemia is one of the signs of diabetes mellitus (DM), which can produce excessive ROS in the body and lead to the production of inflammatory cytokines increasing and accelerating kidney cell damage in diabetes. Diabetic nephropathy is significant cause of renal failure, this is due to genetic susceptibility, glycometabolic disorders, changes in renal hemodynamics, oxidative stress, and inflammatory cytokines. Oxidative stress and inflammation have been shown to interact and have an important role in causing complications of diabetic nephropathy. 9-11 Interaction of oxidative stress and inflammation has a very pivotal role in the pathogenesis and progress of kidney damage in diabetes, which is called nephropathy. In diabetes, excessive ROS production can reduce antioxidant defenses, leading to the oxidation of proteins, DNA, and lipids, resulting in diabetic nephropathy. Hyperglycemia is vulnerable to oxidative stress-induced cell damage due to inhibited antioxidant ability. Oxidative stress is a condition that occurs during an imbalance between the production of

increased reactive oxygen species (ROS) such as superoxide anions (O₂⁻), hydroxyl radicals (OH⁻), hydrogen peroxide (H₂O₂), and antioxidants as defense systems such as SOD, GPx, and catalase decreased. Increased ROS formation can lead to diabetic complications through (a) increased production of AGEs, (b) polyol flux pathway, (c) activation of the hexosamine pathway of (d) increased expression of AGEs receptors, and (e) activation of protein kinase C isoforms. 11, 12 Since oxidative stress and inflammation in the rat model of diabetes caused by streptozotocin have an important role in the progress of diabetic nephropathy, so it is necessary to find antioxidant to prevent the organ damage. Streptozotocin can interfere with the function of the beta cells of the islets of Langerhans resulting in inhibition of insulin release, which in turn leads to hyperglycemia and diabetes complications such as diabetic nephropathy. 11-14 The aim of the research was to evaluate the potency of antioxidative stress and anti-inflammatory effect of karamunting leaves to protect from STZ-induced kidney damage in rats.

Karamunting leaves have properties as anti-inflammatory, anticancer, antibacterial, immunostimulant, antidiabetic, antiatherosclerosis, and antioxidant. 14,15 Based on the results studied, it was founded that karamunting leaves can protect kidney cell damaged in diabetic rats induced by streptozotocin. In this study, the hyperglycaemic condition was shown to change kidney microscopically. The control group showed there was a significant decrease in the size and number of glomerular and tubular compared to the treatment group. This finding indicates that the hyperglycaemia state in DM causes oxidative stress, thus causing damage to kidney. On microscopic observation, hyperglycemia conditions cause a reduction in the size of the glomerulus, thinning of the tubular walls and decrease number of both kidney microstructure. This is due to the process of necrosis of the tubular tissue and glomerular capillaries. 11,12 After being given the ethanol extract of karamunting leaves for 14 days of treatment there was an improvement in the histomorphology kidney structures in the form of glomerular enlargement, tubular wall thickening and increase number of both kidney microstructure. The administration of karamunting leaves significantly decreases streptozotocin-induced kidney cell damage, it's suggesting that karamunting leaves have the ability to inhibit kidney cell damage caused by streptozotocin. 11-12

Karamunting plants (*Rhodomyrtus tomentosa* (Aiton) Hassk) thrive in wetland areas. 5 Many studies reports that the content of karamunting mainly leaves potentially becoming DM treatment, proven in this study. 6,7,8,16 In this study, karamunting plants were taken in the Martapura-Banjar district, and then leaves were processed into ethanol extract preparations. Karamunting leaves ethanol extract with various measurable doses was administered in

the diabetic rat's model for 14 days. Based on the present research, there is antidiabetic potency in karamunting leaves to improve damage of kidney due to previous DM conditions. A possible mechanism is that the antioxidant compounds in karamunting leaves bind to free radicals to reduce oxidative stress, thereby reducing insulin resistance and preventing the development of kidney dysfunction and damage. 6,9,13,17 Several studies demonstrated the hypoglycaemic effects of flavonoids using different experimental models. The results showed that plants containing flavonoids had a beneficial effect on DM, either by decreasing glucose absorption or increasing glucose tolerance. The ability of antioxidants to remove ROS has been demonstrated to be an important role in contributing to nephroprotective efficacy. 3,8,9,14,17 The ethanol extract of karamunting leaves has the highest total phenolic and flavonoid content compared to other fraction samples and when compared to vitamin C. In addition, in testing the antioxidant activity, samples of ethanol extract, water fraction and ethyl acetate fraction of karamunting leaves have activity very strong antioxidant with IC₅₀ value < 50 g/mL. 9 Based on quantitative analysis of antioxidants with UV-vis spectrophotometer, it was shown that the methanol fraction of the methanol extract of karamunting leaves had the highest antioxidant activity with an IC₅₀ value of 51.95 g/mL, which was included in the category of strong antioxidants. 13 Groups of compounds that provide antioxidant activity are phenolic compounds and flavonoids. These compounds are able to dissolve in polar and semipolar solvents. Solvents such as ethanol, ethyl acetate and water have strong abilities as free radical scavengers. 13- 15 Phenolic compounds and flavonoids act as antioxidants because they have a hydroxyl group attached to a carbon that has a conjugated double bond, the hydroxyl group can easily donate hydrogen atoms to free radicals. The more content of flavonoid and phenolic compounds in a plant, the greater the antioxidant activity. 18-21 The results of phytochemical screening showed that the 70% ethanol extract of karamunting leaves contained flavonoids, phenolic compounds, saponins, terpenoids and tannins. One or more of these compounds may act as antioxidants in protecting the kidneys from APAP nephrotoxicity. 19-22 Polyphenols may block oxidative cytotoxicity mechanisms thereby providing a protective effect in the kidney against various oxidative challenges. 23-25

5. Conclusion

Administration of ethanol extract of karamunting leaves for 14 days of treatment made improvement in glomerular enlargement, tubular wall thickening and increase number of tubules.

It's showed that ethanol extract karamunting leaves had potential as a nephroprotective in diabetic rat model. Karamunting leaf ethanol extract has potential as an antidiabetic because it contains

antioxidants that can improve the histomorphological condition of the diabetic rat kidney.

6. Acknowledgments

Financial support for this study was provided by a grant from Lambung Mangkurat University.

Conflict of Interest

None

References

Perkeni, management and prevention of adult type 2 diabetic in Indonesia. 2021.

tapavi majid. Complexity Of Diabetic Nephropathy Pathogenesis and Design of Investigations. *J Renal Inj Prev.* 2013; 2(2): 59-62.

Lukačinová1, j. Mojžiš, r. Beňačka, j. Keller, t. Maguth, p. Kurila, l. Vaško4, o. Rácz, f. Ništár. Preventive Effects of Flavonoids on Alloxan-Induced Diabetes Mellitus in Rats. *ACTA VET. BRNO.* 2008; 77: 175-182; doi:10.2754/avb200877020175

Saleh Irsan Mgs, Rachmat Hidayat, Geri Febriyanto, Nita Parisa. Potential Of Karamunting (*Rhodomyrtus Tomentosa*) Fraction Against Kidney Damage in Diabetic Rats. *Herba Pol.* 2021; 67(2): 9-16. DOI: 10.2478/hepo-2021-0010

Amir, Mochamad Arief Soendjoto. The Plants Utilized as Medicine by Dayak Bakumpai Community Living at the Karau Riverside, Muara Plantau Village, Barito Timur Regency, Kalimantan Tengah, Indonesia. *Prosiding Seminar Nasional Lingkungan Lahan Basah.* 2018; Volume 3 Nomor 1 Halaman 127-132 April 2018

Yulina Ida, Asnawati, Maria Ulfah. Antidiabetic Potential of Karamunting Leaves Ethanolic Extract As A Natural Herb: Blood Glucose Levels And Pancreatic Islets Histomorphology On Diabetic Rats Model. *JKKI.* 2021;12(3):250-256 DOI: 10.20885/JKKI.Vol12.Iss3.art9

Dwicahmi P, Siti Khotimah, Pandu Indra Bangsawan. Antibacterial Activity Test of 70% Ethanol Extract of Karamunting Leaves (*Rhodomyrtus Tomentosa* (Ait.) Hassk) Against *Vibrio Cholerae* Bacterial Growth In Vitro. *Jurnal Pendidikan Dokter Kalbar.* 2015; 3 (1)

Tapas, DM Sakarkar, and RB Kakde. Flavonoids as Nutraceuticals: A Review. *Tropical Journal of Pharmaceutical Research.* 2008; 7 (3): 1089-1099

Dona Rahma, Mustika Furi, Fitri Suryani. Determination of Total Phenolic Content, Total Flavonoid and Antioxidant Activity Test of Extract and Fraction of Karamunting Leaves (*Rhodomyrtus Tomentosa* (Aiton) Hassk). *Jurnal Penelitian Farmasi Indonesia.* 2020; 9(2)

O. O. Oguntibeju. Type 2 Diabetes Mellitus, Oxidative Stress and Inflammation: Examining the Links. *International Journal of Physiology, Pathophysiology and Pharmacology.* 2019; Vol. 11, no. 3, pp. 45–63

J. C. Jha, F. Ho, C. Dan, and K. Jandeleit-Dahm. A Causal Link Between Oxidative Stress and Inflammation in Cardiovascular and Renal

Complications of Diabetes. *Clinical Science.* 2018; vol. 132, no. 16, pp. 1811–1836

Fernandes Sheila Marques, Priscilla Mendes Cordeiro, Mirian Watanabe1, Cassiane Dezoti da Fonseca, Maria de Fatima Fernandes Vattimo. The Role of Oxidative Stress in Streptozotocin-Induced Diabetic Nephropathy in Rats. *Arch Endocrinol Metab.* 2016;60/5

Febriyanto Geri, Mgs. Irsan Saleh, Theodorus. The Antidiabetic Effectiveness of Karamunting Leaf Water Fraction (*Rhodomyrtus Tomentosa* (Ait.) Hassk.) on Blood Glucose Levels and Insulin Secretion in Diabetes Model Rats. *Jurnal Ilmiah Kedokteran Wijaya Kusuma.* 2021; 10(1): 57-70

Suryadinata Wahyu, Endah Rismawati, Eka Sakti, Reza Abdul Kodir. *Fitokimia Studies on Antioxidants from Extract and Karamunting Leaves (Rhodomyrtus tomentosa (Aiton) Hassk.).* *Prosiding Farmasi.* 2019. ISSN: 2460-6472

Ayuningtyas, Heru Fajar Trianto, lit Fitrianingrum. Nephrotoxic Effects of 70% Ethanol Extract. Karamunting Leaves (*Rhodomyrtus tomentosa* (Aiton) Hassk.) on Serum Ureum and Creatinine Levels of Wistar Strain Rats. *Cerebellum Journal.* 2015; Vol 1 No 4.

Yafang Shao, Zhang Gan and Bao Jinsong. Total Phenolic Content and Antioxidant Capacity of Rice Grains with Extremely Small Size. *African Journal of Agricultural Research.* 2011; Vol. 6(10), pp. 2289-2293. Available online at <http://www.academicjournals.org/AJAR>

Mates JM and Sanchez-Jimenez F. Antioxidant Enzymes and Their Implications in Pathophysiologic Processes. *Front Bioscan.* 1999; 4: D339–D345

Trisharyanti Ika, Dian Kusumowati, Rosita Melannisa, Kartikaning Ratri. Correlation Of Phenolic Content and Antioxidant Activity of Cashew Leaves. *Biomedika,* 2011; Volume 3 Nomor 2, Agustus 2011

Pratiwi Putri, Meyni Suzeri, Bambang Cahyono Total Phenolics and Flavonoids from The Central Java Cat Whiskers Leaf Extract and Their Antioxidant Activity. *Sains and Math Journal.* 2011; Vol 18 No 4

Joanne M. Dennis and Paul K. Witting. Protective Role for Antioxidants in Acute Kidney Disease. *Nutrients.* 2017; 718; doi:10.3390/nu9070718

Dahal Achyut and Sirisha Mulukuri. Flavonoids In Kidney Protection. *World Journal of Pharmacy and Pharmaceutical Sciences.* 2015; Vol 4, Issue 03, 2015.

Ratliff BB, Wasan Abdulmahdi, Rahul Pawar, and Michael S. Wolin. Oxidant Mechanisms in Renal Injury and Disease. *ANTIOXIDANTS & REDOX SIGNALING.* 2016; Volume 25, Number 3 Mary Ann Liebert, Inc. DOI: 10.1089/ars.2016.6665

Wardani G et al. Antioxidative Stress and Anti-Inflammatory Activity of Fucoidan Nanoparticles against Nephropathy of Streptozotocin-Induced Diabetes in Rats. *Hindawi Evidence-Based Complementary and Alternative Medicine.* 2022. <https://doi.org/10.1155/2022/3405871>

S. F. Rapa, B. R. Di Iorio, P. Campiglia, A. Heidland, and S. Marzocco. Inflammation And Oxidative Stress in Chronic Kidney Disease-Potential Therapeutic

Role of Minerals, Vitamins And Plant-Derived Metabolites. *International Journal of Molecular Sciences*. 2019; vol. 21, no. 1, pp. 263–285

M. Radenkovic, M. Stojanovi ´ c, and M. Prostran. Experimental Diabetes Induced by Alloxan and Streptozotocin: The Current State of The Art. *Journal of Pharmacological and Toxicological Methods*. 2016; vol. 78, pp. 13–31