

# ITP-METILPREDNISOLON-JSJU- 21012022.pdf

*by*

---

**Submission date:** 12-Jan-2023 09:29AM (UTC+0700)

**Submission ID:** 1991538762

**File name:** ITP-METILPREDNISOLON-JSJU-21012022.pdf (614.65K)

**Word count:** 3981

**Character count:** 17095

ISSN: 0258-2724

DOI : 10.35741/issn.0258-2724.56.6.29

Research article

Social Sciences

## THE ROLE OF METHYLPREDNISOLONE IN CHILDREN WITH IMMUNE THROMBOCYTOPENIC PURPURA: A CASE REPORT

### 甲基泼尼松龙在免疫性血小板减少性紫癜儿童中的作用：病例报告

Harapan Parlindungan Ringoringo

Department of Child Health, Faculty of Medicine, Lambung Mangkurat University - RSD Idaman Banjarbaru, Banjarbaru, Indonesia, [parlinringoringo@ulm.ac.id](mailto:parlinringoringo@ulm.ac.id)

Received: September 6, 2021 ▪ Review: October 8, 2021

▪ Accepted: November 10, 2021 ▪ Published: December 24, 2021

This article is an open-access article distributed under the terms and conditions of the Creative Commons Attribution License (<http://creativecommons.org/licenses/by/4.0>)

#### Abstract

Immune Thrombocytopenia Purpura (ITP) is a bleeding disease often found by doctors, with an incidence of about 1 in 10,000 children, rarely found in infants < 1-year-old. Bleeding often occurs when the platelet is <20,000/uL. This study aims to show that methylprednisolone is effective in severe thrombocytopenia. A girl of 2 months and nine days, weighing 5.6 kg, came to the hospital with complaints of petechiae on the forehead, cheeks, and extremities. The patient is not feverish, pale, weak, cannot drink. No history of trauma. Purpura on the elbows and knees. Laboratory: Hb 8.1 g/dL, leukocytes 12,290/uL, platelets 1000/uL, hematocrit 22.2%, Diff Count: basophils 0%, eosinophils 3%, stems 1%, segments 17%, lymphocytes 70%, monocytes 9%. Peripheral blood features hypochromic, microcytic, lymphocytosis, platelets not found. The diagnosis is newly diagnosed ITP with anemia due to bleeding. The patient was treated at hand-carried ultrasound, given 2U platelet transfusion, 75 mL Packed Red Cells transfusion, 1-2 mg/kg body weight of methylprednisolone every 12 hours for seven days. The patient went home in stable. Methylprednisolone in the acute phase can increase the platelet count. Platelet suspension transfusion is only done if thrombocytopenia is accompanied by bleeding difficult to resolve.

**Keywords:** Immune Thrombocytopenia Purpura, Child, Methylprednisolone

**摘要** 免疫性血小板减少性紫癜（国际贸易协议）是一种经常被医生发现的出血性疾病，发病率约为万分之一，很少见于<1岁的婴儿。当血小板<20,000/升时经常发生出血。本研究旨在证明甲基强的松龙对严重血小板减少症有效。一个2个月零9天的女孩，体重5.6公斤，因额头、脸颊和四肢有瘀斑来院。病人不发烧，面色苍白，虚弱，不能喝酒。无外伤史。手肘和膝盖出现紫癜。实验室：血红蛋白8.1克/分升，白细胞12,290/升，血小板1000/升，血细胞比容22.2%，差异计

数：嗜碱性粒细胞 0%，嗜酸性粒细胞 3%，茎 1%，节段 17%，淋巴细胞 70%，单核细胞 9%。外周血特征为低色素、小细胞、淋巴细胞增多，未发现血小板。诊断是初诊国际贸易协议伴出血性贫血。患者接受手持超声治疗，输注 2 你血小板，输注 75 毫升浓缩红细胞，每 12 小时给予 1-2 毫克/公斤体重的甲基强的松龙，持续 7 天。病人稳定地回家了。急性期甲泼尼龙可增加血小板计数。仅当血小板减少症伴有难以解决的出血时才进行血小板悬浮输血。

**关键词：**免疫性血小板减少性紫癜，儿童，甲泼尼龙

## I. INTRODUCTION

Immune Thrombocytopenia Purpura (ITP) is an acquired acute bleeding disease in the form of petechiae and purpura on the skin and or mucous membranes due to thrombocytopenia (platelet count <100,000/uL). Thrombocytopenia is due to premature destruction of platelets or platelet precursors caused by the humoral response of anti-platelet autoantibodies. Moreover, reduced platelet formation in the bone marrow is no underlying disease. The causes are divided into 2, namely: 1) primary ITP, which has no underlying cause, 2) secondary ITP, there is a necessary cause. According to the course of the disease, ITP in children is divided into three types, namely: 1) 50% of cases remain newly diagnosed (<3 months), 2) 25% of cases become persistent (3-12 months), and 3) 25% become chronic (> 12 months) [1].

## II. CASE PRESENTATION

A girl of 2 months and nine days, weighing 5.6 kg, came to the hospital with complaints of red spots on the forehead, cheeks, and all extremities. The patient had no history of vaccination days or weeks prior. However, two weeks earlier, the patient had a common cold. In the family, no one has this kind of disease. The patient is conscious, not fevered, weak, pale, cannot drink, is inactive, and has no history of trauma. On physical examination, the patient appears conscious, and vital signs are within normal limits. Eye, ENT, mouth, and abdomen, no abnormalities. Heart Lungs within normal limits. On the forehead, cheeks, and all extremities, Petechiae purpura on the elbows and knees. On laboratory examination, Hb 8.1 g/dL, leukocytes 12,290/uL, platelets 1000/uL, hematocrit 22.2%, Diff Count: basophils 0%, eosinophils 3%, stems 1%, segments 17%, lymphocytes 70%, monocytes 9%. RBC 2.8 million/uL, MCV 82.9fL, MCH 28.9pg, MCHC 34.9%, RDW\_CV 16.7%. Peripheral smear features hypochromic, microcytic, lymphocytosis, blast, and platelets not found. The diagnosis is newly diagnosed ITP with anemia due to

bleeding. The patient was treated at hand- carried ultrasound (HCU), given 2U platelet transfusion, 75 mL Packed Red Cells (PRC) transfusion, 1-2 mg/kg body weight of methylprednisolone every 12 hours for seven days. After seven days of treatment, the patient went home in good condition.

## III. DISCUSSION

Immune thrombocytopenia most commonly occurs in children 2-7 years of age [2]. The incidence of pediatric ITP is 4.3 per 100,000 people/year, and in the 2-5 year age group, the incidence is higher in boys than girls [3]. This disease is rarely found in infants <1 year old, probably because of the immature baby's immune system. In general, there is always a history of viral infection of the upper respiratory tract or gastrointestinal system or immunizations 2-4 weeks before [2]. Yong et al. reported a history of infection in 20.2% and immunization of 8.6% of 257 pediatric ITP patients [3], while Hashemi et al. reported a history of the common cold disease in 47% of cases and 25.8% had a history of immunization [4].

Bleeding often occurs when the platelet count is <20,000/uL. Purpuric, mucosal, and intracranial hemorrhages were found in 83.3% of cases, 40.95 cases, and 3%, respectively [4]. Eighty percent of children with ITP who suffer from acute bleeding will recover within days or weeks with or without treatment and recover within six months (acute). The platelet count will return to normal (>150,000/uL) in 50% of cases within 1-3 months and 60-75% within six months of the onset of thrombocytopenia [5, 6].

In this case, the patient presented with petechial bleeding on the scalp and all extremities. Two weeks earlier, the patient had a common cold. The patient is conscious, looks weak, pale, inactive, and does not want to drink. Complete blood count showed a Hb 8.1 g/dL with a platelet count of 1000/uL, and no blast cells and platelets were found on the peripheral blood smear. This situation is an emergency considering that only 1000 platelets/uL are at high risk of intracranial

bleeding. Bleeding intracranial is rare, only 0.5-1% of cases when the platelet count is <10,000/uL [7], but this should be considered. Therefore this patient was given a 2U platelet suspension transfusion, 75 ml PRC transfusion, and 2 mg/kg body weight of methylprednisolone every 12 hours for seven days. As a result, the patient's condition is improving. On the third day of treatment, the platelet count rose to 5,000/uL. On the 5th day, it became 12,000/uL; on the 7th day, the platelet count was 33,000/uL, and the patient went home in stable. Next, the patient

received prednisone therapy for one week at a dose of 2 mg/kg body weight/day followed by tapering off for up to 1 month from the diagnosis of ITP when the platelet count became 259,000/uL. Furthermore, the increment of platelet count from the start of treatment to 6 months of monitoring can be seen in Figure 1. Within one month of treatment, the patient experienced complete remission, as a study stated that 73.5% of ITP patients would experience complete remission within six months of treatment [8].

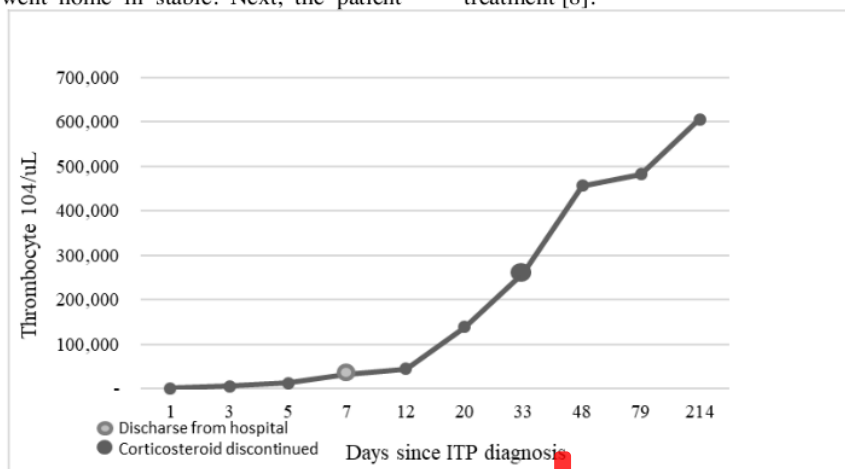


Figure 1. Thrombocyte count since the first day of ITP diagnosis

Treatment of ITP must, of course, be based on the complex pathogenesis of ITP. The first-line drugs are glucocorticoids, IVIG, anti-D immunoglobulin. This patient receives a standard dose of 2 mg/kg body weight of methylprednisolone every 12 hours (4 mg/kg body weight/day). It is combined with a platelet suspension transfusion, which is expected to resolve the emergency immediately. Even though the patient had received the platelet suspension and methylprednisolone for two days, the platelet count only increased to 5000/uL. On the 7th day of treatment, the platelets had become 33,000/uL. Petechiae seemed to disappear that the patient was discharged. The main goal of ITP treatment is not merely to increase the platelet count to an expected value but is to an effective platelet count to stop bleeding. Generally, if the platelet count is above 30,000/uL, the clinical experience will be better. The choice of glucocorticoids in these patients is because IVIG is expensive and difficult to obtain. After six months, monitoring the platelet count was still normal even though the corticosteroid drugs had been discontinued for five months. Patients received DPaT immunization at the age of 8 ½ months and 12

months, and no visible lesions were seen at the injection site. Acero-Garcés et al. reported that for rising platelet count, platelet count with IVIG 2g/kg was lower than methylprednisolone 50mg/kg after a month [9]. Furthermore, Sogut et al. reported that the ITP patients receiving IVIG had been found to progress to chronicity more than those receiving methylprednisolone [10]. Contrarily, Safapour reported a study comparing therapy methods employing corticosteroids and IVIG in affected children and found no significant difference between long-term treatment outcomes for ITP [11].

Suppose first-line treatment fails (clinical manifestations and thrombocytopenia cannot be controlled within 3-6 months of therapy); in that case, it is necessary to think about treatment with second-line drugs. The second-line drugs, namely splenectomy, rituximab, thrombopoietin receptor agonists (TPO-RA), eltrombopag, romiplostim, and avatrombopag). If second-line drugs are ineffective, then third-line drugs can be used, such as Fostamatinib (the Syk inhibitor), oseltamivir (inhibits the deserialization process, thereby reducing platelet clearance the liver). Atorvastatin affects bone marrow endothelial

cells to support hematopoiesis, including megakaryopoiesis [12-14]. Low doses of decitabine (DAC) can increase the expression of tumor necrosis factor-related apoptosis-inducing ligand (TRAIL) by reducing the methylation process in megakaryocytes, thus increasing megakaryocyte maturation and platelet production [15].

At the start of the disease, we cannot differentiate between acute and chronic ITP. ITP in infants, 9% will be chronic ITP; ITP in children aged 25-119 months, 18% will be chronic ITP, and ITP in children  $\geq 120$  months, 47% will become chronic ITP [16]. Jung et al. stated that 85.9% of children with ITP would be in remission, and 14.1% of cases will be chronic ITP; the prognostic factors for chronic ITP are older children and the slow appearance of clinical symptoms [17]. Makis et al. stated that the prognostic factors for developing chronic ITP are age  $> 10$  years, no previous infection history, more protracted clinical manifestations, and initial platelet count  $> 10,000/uL$  [18]. Other investigators reported that the prognostic factors that provided complete remission when ITP was established were a low MPV level  $< 8fL$  and previous infection history [19]. In this case, the patient was two months nine days old when the initial diagnosis of ITP, female, had a history of illness two weeks before, and bleeding appeared suddenly. In addition, the initial platelet count  $< 10,000/uL$ , complete remission within one month, and platelets remain normal within six months of monitoring, so the prognosis of this patient is good, there will be no chronic ITP.

#### IV. CONCLUSION

Methylprednisolone in the acute phase can increase the platelet count. If there is a financial hindrance, it is wise to give a low-cost drug, i.e., methylprednisolone. Platelet suspension transfusion is only done if thrombocytopenia is accompanied by bleeding that is difficult to resolve.

#### REFERENCES

- [1] RODEGHIERO, F., STASI, R., GERNSHEIMER ET AL, T., MICHEL, M., PROVAN, D., ARNOLD, D.M., BUSSEL, J.B., CINES, D.B., CHONG, B.H., COOPER, N., GODEAU, B., LECHNER, K., MAZZUCCONI, M.G., MCMILLAN, R., SANZ, M.A., IMBACH, P., BLANCHETTE, V., KÜHNE, T., RUGGERI, M., and GEORGE, J.N. (2009) Standardization of terminology, definitions and outcome criteria in immune thrombocytopenic purpura of adults and children: report from an international working group. *Blood*, 113 (11), pp. 2386-2393.
- [2] FOGARTY, P.F., and SEGAL, J.B. (2007) The epidemiology of immune thrombocytopenic purpura. *Current Opinion in Hematology*, 14 (5), pp. 515-519.
- [3] YONG, M., SCHOONEN, W.M., LI, L., KANAS, G., COALSON, J., MOWAT, F., FRYZEK, J., and KAYE, J.A. (2010) Epidemiology of paediatric immune thrombocytopenia in the General Practice Research Database. *British Journal of Haematology*, 149, pp. 855-864.
- [4] HASHEMI, A., KARGAR, F., SOUZANI, A., and HAZAR N. (2011) Acute Immune Thrombocytopenic Purpura in infants. *Iranian Journal of Pediatric Hematology & Oncology*, 1 (3), pp.104-108.
- [5] KÜHNE, T., BUCHANAN, G.R., ZIMMERMAN S., MICHAELS, L.A., KOHAN, R., BERCHTOLD, W., and IMBACH, P. (2003) A prospective comparative study of 2540 infants and children with newly diagnosed idiopathic thrombocytopenic purpura (ITP) from the Intercontinental Childhood ITP Study Group. *Journal of Pediatrics*, 143 (5), pp. 605-608.
- [6] ROSTHØJ, S., HEDLUND-TREUTIGER, I., RAJANTIE, J., ZELLER, B., JONSSON, O.G., ELINDER, G., WESENBERG, F., and HENTER, J.-I. (2003) Duration and morbidity of newly diagnosed idiopathic thrombocytopenic purpura in children: A prospective Nordic study of an unselected cohort. *Journal of Pediatrics*, 143 (3), pp. 302-307.
- [7] ARNOLD, DM. (2015) Bleeding complications in immune thrombocytopenia. *International Journal of Hematology*, 2015, pp. 237-242.
- [8] AKBAYRAM, S., DOGAN, M., USTYOL, L., AKGUN, C., PEKER, E., BILICI, S., CAKSEN, H., and ONER A.F. (2011) The Clinical Outcome of 260 Pediatric ITP Patients in One Center. *Clinical and Applied Thrombosis/Hemostasis*, 17 (6), pp. 30-35.

- [9] ACERO-GARCÉS, D.O., and GARCÍA-PERDOMO, H.A. (2020) First-Line Treatments for Newly Diagnosed Primary Immune Thrombocytopenia in Children: A Systematic Review and Network Meta-analysis. *Current Pediatric Reviews*, 16, pp. 61-70. [Online] Available from: <http://www.eurekaselect.com/176074/article>. <https://doi.org/10.2174/1573396315666191023122542>.
- [10] SÖĞÜT, G., LEBLEBISATAN, G., BARUTÇU, A., KILINÇ, Y., and ŞAŞMAZ, H. İ. (2020) Evaluation of Pediatric Patients with Immune Thrombocytopenia Regarding Clinical Course and Treatment Response: A Retrospective Single-Center Experience. *Pediatric Practice and Research*, 8 (2), pp. 38-42.
- [11] SAFAPOUR, A., ALGHASI, A., and ABOLNEZHADIAN, F. (2021) Recurrence rate in patients with acute immune Thrombocytopenic purpura in Ahvaz, southwest of Iran: Corticosteroids versus intravenous immunoglobulin. *Journal of Preventive Epidemiology*, 6 (1), e03. DOI: 10.34172/jpe.2021.03.
- [12] DOU, X., and YANG, R. (2019) Current and emerging treatments for immune thrombocytopenia, *Expert Review of Hematology*, 12 (9), pp. 723-732. DOI: 10.1080/17474086.2019.1636644.
- [13] DESPOTOVIC J.M. (2018) Mini-Review. Emerging Therapies in Immune Thrombocytopenia. *The Hematologist*, 15 (4).
- [14] ZUFFEREY, A., KAPUR, R., and SEMPLE, J.W. (2017) Pathogenesis and Therapeutic Mechanisms in Immune Thrombocytopenia (ITP). *Journal of Clinical Medicine*, 6 (16). DOI: 10.3390/jcm6020016.
- [15] LIUA, S, and SHAN, N. (2020) DNA methylation plays an important role in immune thrombocytopenia. *International Immunopharmacology*, 83, 106390.
- [16] SANDOVAL, C., VISINTAINER P, OZKAYNAK, M.F., TUGAL, O., and JAYABOSE, S. (2004) Clinical Features and Treatment Outcomes of 79 Infants with Immune Thrombocytopenic Purpura. *Pediatric Blood & Cancer*, 42, pp.109-112.
- [17] JUNG, J.Y., RUM, O.A., KIM, J.K., and PARK, M. (2016) Clinical course and prognostic factors of childhood immune thrombocytopenia: single-center experience of 10 years. *Korean Journal of Pediatrics*, 59 (8), pp. 335-340.
- [18] MAKIS, A., GKOUTSIAS, A., PALIANOPOULOS T., PAPPAS, E., PAPAPETROU, E., TSAOUSI, C., HATZIMICHAEL, E., and CHALIASOS, N. (2017) Prognostic Factors for Immune Thrombocytopenia Outcome in Greek Children: A Retrospective Single-Centered Analysis. *Advances in Hematology*, 2017, 7878605.
- [19] AHMED, S., SIDDIQUI, A.K., SHAHID, R.K., KIMPO, M., SISON, C.P., and HOFFMAN, M.A. (2004) Prognostic variables in newly diagnosed childhood immune thrombocytopenia. *American Journal of Hematology*, 77 (4), pp. 358-362. DOI: 10.1002/ajh.20205.

#### 參考文:

- [1] RODEGHIERO, F., STASI, R., GERNESHEIMER ET AL, T., MICHEL, M., PROVAN, D., ARNOLD, D.M., BUSSEL, J.B., CINES, D.B., CHONG, B.H., COOPER, N., GODEAU, B., LECHNER, K., MAZZUCCONI, M.G., MCMILLAN, R., SANZ, M.A., IMBACH, P., BLANCHETTE, V., KUHN, T., RUGGERI, M. 和 GEORGE, J.N. (2009) 成人和兒童免疫性血小板減少性紫癜的術語、定義和結果標準的標準化：來自國際工作組的報告。血液，113 (11)，第 2386-2393 頁。
- [2] FOGARTY, P.F. 和 SEGAL, J.B. (2007) 免疫性血小板減少性紫癜的流行病學。血液學的最新觀點，14 (5)，第 515-519 頁。
- [3] YONG, M., SCHOONEN, W.M., LI, L., KANAS, G., COALSON, J., MOWAT, F., FRYZEK, J. 和 KAYE, J.A. (2010) 全科醫學研究數據庫中小兒免疫性血小板減少症的流行病學。英國血液學雜誌，149，第 855-864 頁。
- [4] HASHEMI, A.、KARGAR, F.、SOUZANI, A. 和 HAZAR N. (2011) 嬰兒急性免疫性血小板減少性紫癜。伊朗兒科血液學與腫瘤學雜誌，1 (3)，第 104-108 頁。

- [5] KÜHNE, T., BUCHANAN, G.R., ZIMMERMAN S., MICHAELS, L.A., KOHAN, R., BERCHTOLD, W., 和 IMBACH, P. (2003) 一項對 2540 名新診斷嬰兒和兒童的前瞻性比較研究洲際兒童免疫性血小板減少性紫癜 研究組的特發性血小板減少性紫癜。兒科雜誌, 143 (5), 第 605-608 頁。
- [6] ROSTHØJ, S.、 HEDLUND-TREUTIGER, I.、 RAJANTIE, J.、 ZELLER, B.、 JONSSON, O.G.、 ELINDER, G.、 WESEBERG, F. 和 HENTER, J.-I. (2003) 兒童新診斷的特發性血小板減少性紫癜的持續時間和發病率：一項未選擇隊列的前瞻性北歐研究。兒科雜誌, 143 (3), 第 302-307 頁。
- [7] ARNOLD, D.M. (2015) 免疫性血小板減少症的出血並發症。國際血液學雜誌, 2015 年, 第 237-242 頁。
- [8] AKBAYRAM, S.、 DOGAN, M.、 USTYOL, L.、 AKGUN, C.、 PEKER, E.、 BILICI, S.、 CAKSEN, H. 和 ONER A.F. (2011) 260 兒科的臨床結果一個中心的免疫性血小板減少性紫癜患者。臨床和應用血栓形成/止血, 17 (6), 第 30-35 頁。
- [9] ACERO-GARCÉS, D.O. 和 GARCÍA-PERDOMO, H.A. (2020) 兒童新診斷原發性免疫性血小板減少症的一線治療：系統評價和網絡元分析。當前兒科評論, 16, 第 61-70 頁。 [ 在 線 的 ] 。 可 從 : <http://www.eurekaselect.com/176074/article獲得>。  
<https://doi.org/10.2174/1573396315666191023122542>。
- [10] SÖĞÜT, G.、 LEBLEBISATAN, G.、 BARUTÇU, A.、 KILINÇ, Y. 和 ŞAŞMAZ, H. İ. (2020) 免疫性血小板減少症兒科患者的臨床病程和治療反應評估：回顧性單中心經驗。兒科實踐與研究, 8 (2), 第 38-42 頁。
- [11] SAFAPOUR, A.、 ALGHASI, A. 和 ABOLNEZHADIAN, F. (2021) 伊朗西南部阿瓦士急性免疫性血小板減少性紫癜患者的複發率：皮質類固醇與靜脈注射免疫球蛋白。預防流行病學雜誌, 6 (1), e03。DOI: 10.34172/jpe.2021.03。
- [12] DOU, X. 和 YANG, R. (2019) 當前和新興的免疫性血小板減少症治療方法, 血液學專家評論, 12 (9), 第 723-732 頁。DOI: 10.1080/17474086.2019.1636644。
- [13] DESPOTOVIC J.M. (2018) 迷你評論。免疫性血小板減少症的新興療法。血液學家, 15 (4)。
- [14] ZUFFEREY, A.、 KAPUR, R. 和 SEMPLE, J.W. (2017) 免疫性血小板減少症的發病機制和治療機制。臨床醫學雜誌, 6 (16)。DOI: 10.3390/jcm6020016。
- [15] LIUA, S 和 SHAN, N. (2020) 脫氧核糖核酸甲基化在免疫血小板減少症中起著重要作用。國際免疫藥理學, 83, 106390。
- [16] SANDOVAL, C., VISINTAINER P, OZKAYNAK, M.F., TUGAL, O., 和 JAYABOSE, S. (2004) 79 名免疫性血小板減少性紫癜嬰兒的臨床特徵和治療結果。兒科血液與癌症, 42, 第 109-112 頁。
- [17] JUNG, J.Y., RUM, O.A., KIM, J.K., 和 PARK, M. (2016) 兒童免疫性血小板減少症的臨床過程和預後因素：10 年的單中心經驗。韓國兒科雜誌, 59 (8), 第 335-340 頁。
- [18] MAKIS, A., GKOUTSIAS, A., PALIANOPOULOS T., PAPPAS, E., PAPAPETROU, E., TSAOUSI, C., HATZIMICHAEL, E. 和 CHALIASOS, N. (2017) 免疫性血小板減少症的預後因素希臘兒童的結果：回顧性單中心分析。血液學進展, 2017, 7878605。
- [19] AHMED, S., SIDDIQUI, A.K., SHAHID, R.K., KIMPO, M., SISON, C.P. 和 HOFFMAN, M.A. (2004) 新診斷的兒童免疫性血小板減少症的預後變量。美國血液學雜誌, 77 (4), 第 358-362 頁。DOI: 10.1002/ajh.20205。

ORIGINALITY REPORT

---

12%

SIMILARITY INDEX

11%

INTERNET SOURCES

15%

PUBLICATIONS

0%

STUDENT PAPERS

---

MATCH ALL SOURCES (ONLY SELECTED SOURCE PRINTED)

---

10%

★ Harapan Parlindungan Ringoringo. "Immune Thrombocytopenia as the Initial Manifestation of Pediatric Systemic Lupus Erythematosus: Case Reports", Open Access Macedonian Journal of Medical Sciences, 2022

Publication

---

Exclude quotes On

Exclude matches < 2%

Exclude bibliography On