

**REVIEWER CERTIFICATE**

**DAN**

**REKAM JEJAK DIGITAL**

**Assisted Vaginal Breech Delivery of undiagnosed  
Parapagus Dicephlus conjoined twins**

**International Journal of Women's Health**

## REVIEWER CERTIFICATE: 9 MARET 2022

### To whom it may concern

Dr Harapan perlindungan Ringoringo has reviewed 1 submission in the journal *International Journal of Women's Health* (journal Impact Factor: 2.773) during 2022.

This contribution is greatly appreciated.

Regards

**Angela Jones**

**General Manager, Dove Medical Press Ltd**

Dove Medical Press (NZ) Ltd, 44 Corinthian Drive, Albany, Auckland, New Zealand

PO Box 300-008, Albany, Auckland, 0752, New Zealand

**p** +649 443 3060 **f** +649 443 3061 **e** [info@dovepress.com](mailto:info@dovepress.com)

**Live Chat** [https://www.dovepress.com/live\\_help.t](https://www.dovepress.com/live_help.t)

**Twitter** <https://twitter.com/DovePress>

[www.dovepress.com](http://www.dovepress.com) - open access to scientific and medical research

# STATUS JURNAL SAAT INI

**Resurchify** Search Conferences, Journals, etc

Conferences Journals

IMPACT SCORE JOURNAL RANKING CONFERENCE RANKING SYMPOSIUMS MEETINGS BLOG LaTeX

Search About Journals, Conferences, and Book Series

Enter Journal Title, ISSN, Category, Book Title or Publisher

**SEARCH**

## 1. International Journal of Women's Health

International Journal of Women's Health is a journal covering the categories related to **Maternity and Midwifery (Q1); Obstetrics and Gynecology (Q2); Oncology (Q3)**. It is published by **Dove Medical Press Ltd.**. The overall rank of International Journal of Women's Health is **7566**. ISSN of this journal is/are **11791411**.

Impact Score: 2.57 h-Index: 52 SJR: 0.646 Overall Ranking: 7566

**More Details**

## UPDATE IMPACT FACTOR JURNAL

Medicine Obstetrics and Gynecology All regions / countries All types 2021

Only Open Access Journals  Only SciELO Journals  Only WoS Journals <sup>?</sup> Display journals with at least 0 Citable Docs. (3years) Apply


[Download data](#)

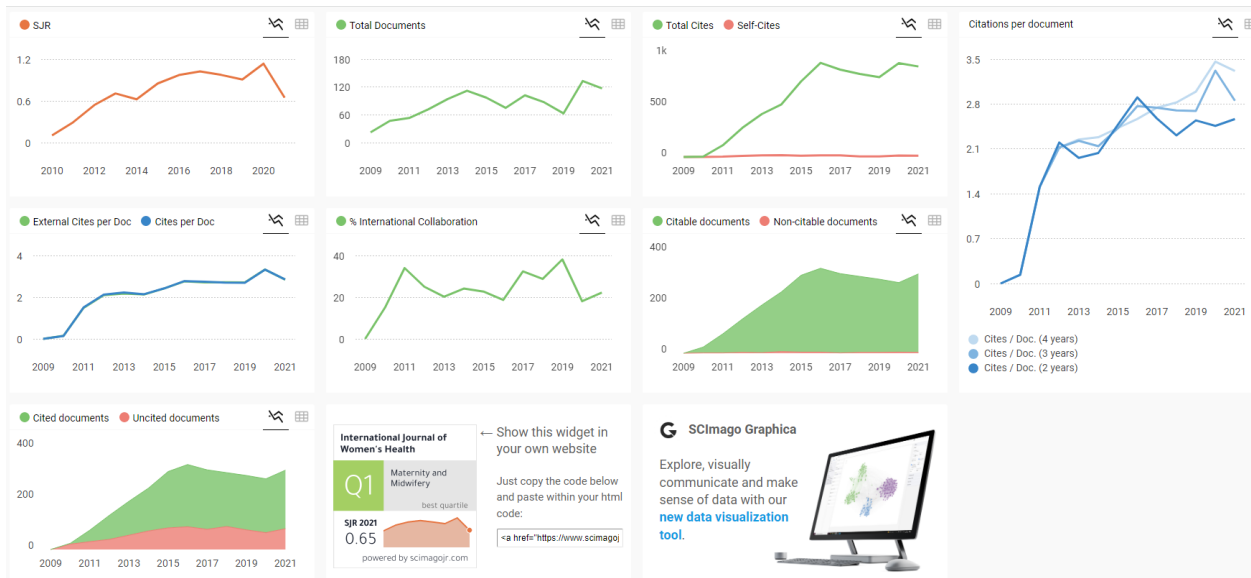
1 - 50 of 60

| Title  | Type    | ↓ SJR       | H index | Total Docs. (2021) | Total Docs. (3years) | Total Refs. (2021) | Total Cites (3years) | Citable Docs. (3years) | Cites / Doc. (2years) | Ref. / Doc. (2021) |  |
|--|---------|-------------|---------|--------------------|----------------------|--------------------|----------------------|------------------------|-----------------------|--------------------|--|
| 13 <a href="#">Advances in Urology</a>                     | journal | 0.656<br>Q2 | 33      | 15                 | 48                   | 371                | 157                  | 47                     | 1.35                  | 24.73              |  |
| 14 <a href="#">International Journal of Women's Health</a> | journal | 0.646<br>Q2 | 52      | 117                | 283                  | 4881               | 807                  | 280                    | 2.57                  | 41.72              |  |
| 15 <a href="#">Journal of Pregnancy</a>                    | journal | 0.615<br>Q2 | 35      | 11                 | 115                  | 604                | 324                  | 115                    | 2.35                  | 54.91              |  |

# SCIMAGO RANK JURNAL

## International Journal of Women's Health

|   |   |  |   |
|---|---|--|---|
| <p><b>COUNTRY</b></p> <p>New Zealand</p> <p> Universities and research institutions in New Zealand</p> | <p><b>SUBJECT AREA AND CATEGORY</b></p> <ul style="list-style-type: none"> <li>Medicine             <ul style="list-style-type: none"> <li>Obstetrics and Gynecology</li> <li>Oncology</li> </ul> </li> <li>Nursing             <ul style="list-style-type: none"> <li>Maternity and Midwifery</li> </ul> </li> </ul> | <p><b>PUBLISHER</b></p> <p>Dove Medical Press Ltd.</p> | <p><b>H-INDEX</b></p> <h1>52</h1>   |
| <p><b>PUBLICATION TYPE</b></p> <p>Journals</p>  | <p><b>ISSN</b></p> <p>11791411</p>  | <p><b>COVERAGE</b></p> <p>2009-2021</p>                | <p><b>INFORMATION</b></p> <p><a href="#">Homepage</a></p> <p><a href="#">How to publish in this journal</a></p> |



# INVITATION AS A REVIEWER: TANGGAL 9 MARET 2022

**Dove Medical Press invites you to review a paper for International Journal of Women's Health Submission ID: 365016** External

Ms Eileen Dixon •eileeng@dovepress.com•  
to me

Mar 9, 2022, 3:59 PM (9 hours ago)

Dear Dr Ringorings

Dove Medical Press invites you to join our peer review community. Our expert reviewers greatly contribute to the high standards of the journal.

The reviewer selection team search and invite peer reviewers in the same area of medicine and science as our authors and we hope that you will be willing to provide your expert assessment on this article.

Manuscript title: Assisted Vaginal Breech Delivery of undiagnosed Parapagus Dicephalus conjoined twins

Article type: Case report

Author: Dr Dereje Tegene

Journal: International Journal of Women's Health (Journal impact factor: 2.773)  
<https://www.dovepress.com/international-journal-of-womens-health-journal>

**Abstract:** Background: Parapagus (anterolaterally joined at the chest, abdomen and pelvis) dicephalus (two-headed) twins are rare types of conjoined twin. Vaginal delivery of undiagnosed conjoined twin is rare occurrence and associated with Dystocia, maternal and fetal trauma.

**Case Presentation:** We reported a 22 years old Gravid -2, Para-1 (alive, vaginal delivery), mother who doesn't recall her first day of last normal menstrual period, but claimed to be amenorrhic for last 9 months. She had no obstetric ultrasound during her follow up. She was referred from a nearby health center with the diagnosis of breech presentation + active first stage of labor + intrauterine fetal death. Up on arrival she was in the second stage of labor and fetus was delivered till the level of the umbilicus, up on pushing the whole trunk delivered till the level of neck. With gentle down traction and suprapubic pressure two fetal head was delivered. A 2900 gram male stillborn had two heads, two necks, two upper and lower extremities, and single trunk. The mother had no significant vaginal bleeding and no genital tract laceration. She was discharged on her 3rd postpartum day.

**Conclusions:** All pregnant women should have at least one obstetric ultrasound during their antenatal care follow up to make the diagnosis of conjoined twins at earlier gestational age, which is very important to guide the subsequent management.

We would appreciate your response to this email by 16 Mar 2022. If you agree to review this manuscript, your comments will be due 10 days from accepting the invitation. Peer-review comments can only be accepted online via our reviewer system. We cannot accept downloaded manuscript files that you have annotated or modified in any way.

This link [https://www.dovepress.com/reviews/ah72-Y8PQ6BK694H-J4H53vUMss1669913&review\\_id=4392413](https://www.dovepress.com/reviews/ah72-Y8PQ6BK694H-J4H53vUMss1669913&review_id=4392413) will take you directly to your peer review interface (a password isn't required). You will be able to:

- Accept or decline the review invitation
- We provide a structured peer review evaluation form which guides the reviewer through the important points for consideration when evaluating a manuscript.
- Information on Peer Review guidelines
- Download all files

**Abstract:** Background: Parapagus (anterolaterally joined at the chest, abdomen and pelvis) dicephalus (two-headed) twins are rare types of conjoined twin. Vaginal delivery of undiagnosed conjoined twin is rare occurrence and associated with Dystocia, maternal and fetal trauma.

**Case Presentation:** We reported a 22 years old Gravid -2, Para-1 (alive, vaginal delivery), mother who doesn't recall her first day of last normal menstrual period, but claimed to be amenorrhic for last 9 months. She had no obstetric ultrasound during her follow up. She was referred from a nearby health center with the diagnosis of breech presentation + active first stage of labor + intrauterine fetal death. Up on arrival she was in the second stage of labor and fetus was delivered till the level of the umbilicus, up on pushing the whole trunk delivered till the level of neck. With gentle down traction and suprapubic pressure two fetal head was delivered. A 2900 gram male stillborn had two heads, two necks, two upper and lower extremities, and single trunk. The mother had no significant vaginal bleeding and no genital tract laceration. She was discharged on her 3rd postpartum day.

**Conclusions:** All pregnant women should have at least one obstetric ultrasound during their antenatal care follow up to make the diagnosis of conjoined twins at earlier gestational age, which is very important to guide the subsequent management.

We would appreciate your response to this email by 16 Mar 2022. If you agree to review this manuscript, your comments will be due 10 days from accepting the invitation. Peer-review comments can only be accepted online via our reviewer system. We cannot accept downloaded manuscript files that you have annotated or modified in any way.

This link [https://www.dovepress.com/reviews/ah72-Y8PQ6BK694H-J4H53vUMss1669913&review\\_id=4392413](https://www.dovepress.com/reviews/ah72-Y8PQ6BK694H-J4H53vUMss1669913&review_id=4392413) will take you directly to your peer review interface (a password isn't required). You will be able to:

- Accept or decline the review invitation
- We provide a structured peer review evaluation form which guides the reviewer through the important points for consideration when evaluating a manuscript.
- Information on Peer Review guidelines
- Download all files

The authors manuscript or existence of a manuscript is provided to you on a confidential basis. An author's manuscript may not be disclosed in whole, or in part, to any third party under any circumstances. In addition, you may not forward this invitation to any third party. It is a personal invitation to you alone.


I thank you for considering our invitation.

If you have any questions do not hesitate to contact me.

Yours sincerely

Ms Eileen Dixon  
On behalf of Professor Elie A-Chaar  
International Journal of Women's Health  
Dove Medical Press  
[www.dovepress.com](http://www.dovepress.com) - open access to scientific and medical research

## SUBMITTED REVIEW: 9 MARET 2022

About | Contact | Sustainability | Awards | Press Center | Testimonials | Blog | Favored Author Program | Permissions | Pre-Submission | Reprints | [Logout](#) | 

**Dovepress**  
open access to scientific and medical research

Search Dove Press  [Search](#)  
Advanced search

**News:** Dovepress wins in two categories at the Toitū Brighter Future Awards for sustainability [Read more](#)

- [Home](#)
- [Journals](#)
- [Why publish with us?](#)
- [Editorial Policies](#)
- [Author Information](#)
- [Peer Review Guidelines](#)
- [Open Outlook](#)
- [COVID-19](#)
- [Podcasts](#)

**My Dovepress**  
Logged in as Dr Ringorngo

- [Dashboard](#)
- [Update My Details](#)
- [Update My Password](#)
- [Manage Email Alerts](#)
- [Favored Author Program](#)
- [Peer Review](#)
  - Invited Reviews (0)**
  - Outstanding Reviews (0)
  - Completed Reviews (2)
  - Peer-reviewer acknowledgements (2)
  - Volunteer Reviewer
  - Peer Reviewer User Manual
  - Peer Review FAQ
  - Reviewer Training Programme

Back to [Peer Review](#) » Invited Reviews

Thank you for your review has been submitted.

### Invited Reviews

**Invited Reviews (0)** Outstanding Reviews (0) Completed Reviews (2)

No paper available.

## THANK YOU FOR THE SUBMITTED REVIEW: 9 MARET 2022

Gmail Search all conversations

Peer Review for International Journal of Women's Health [ID: 365016] [External](#) [Inbox](#)

Ms Dixon <elien@dovepress.com> to me  
Dear Dr Ringorngo

This is to confirm we have received your peer review comments for:  
Title: Assisted Vaginal Breech Delivery of undiagnosed Parapagus Dicephalus conjoined twins

The time and effort that you have put into this review is most appreciated. You will be sent a peer review acknowledgement certificate once the editorial team have processed your review.

If I can be of further assistance, please do not hesitate to contact me.

Kind regards  
Ms Dixon  
[ID: 365016]

**PUBLON: 10 MARET 2022**



Congratulations HARAPAN PARLINDUNGAN RINGORINGO!

Your recent review of "Assisted Vaginal Breech Delivery of undiagnosed Parapagus Dicephlus conjoined twins" for International Journal of Women's Health has automatically been added to your [Publons profile](#) as part of our partnership with Dove Medical Press Ltd..

This review was added automatically because the automatic addition of reviews from partnered journals is enabled on your account. You can change this setting in your [profile settings](#). Please check our [FAQ portal](#) if you have any questions.

The review was added using your default privacy settings, although these may be subject to the official journal review policy. To see the details of your review please view the [status page](#).

*Copyright © 2022 Clarivate, All rights reserved.*

Got a question?

**Check out our [FAQs](#)**

Send review receipts to:

[reviews@publons.com](mailto:reviews@publons.com)