



maharani roxy <maharaniroxy@gmail.com>

Re: Online Paper Submission

2 pesan

Rohan JCF Corp <rohan@jcfcorp.com>
Kepada: maharaniroxy@gmail.com

7 Juli 2022 19.50

Dear Dr. Maharani,

Thank you for submitting your valuable work to our Journal. There is an author fee USD 1000 associated with the accepted articles.

Please confirm and submit your article by using the link below to start the review process.

Link: <http://rds.manuscriptmanager.net>

Kindly get back to us for further queries.

Have a great day!

Regards,
Rohan Reddy
RDS

On Thu, Jul 7, 2022 at 3:53 PM Info SBDR <info@soc-bdr.org> wrote:

-----Ursprüngliche Nachricht-----

Von: maharaniroxy@gmail.com [mailto:maharaniroxy@gmail.com]

Gesendet: Donnerstag, 7. Juli 2022 00:17

An: info@soc-bdr.org

Betreff: Online Paper Submission

First Name : Maharani
Middle Initial : Laillyza
Last Name : Apriasari
Title : Dr
Institution : University of Lambung Mangkurat
Department : Oral Medicine

Address 1 : Veteran street no. 128B
Address 2 :
City : Banjarmasin
State :
ZIP/Postal Code : 70239
Country : Indonesia

Date of Birth (MM/DD/YYYY):

Phone Number :

E-mail : maharaniroxy@gmail.com

Cover Letter:

Filename : COVER LETTER-Review of Diabetic Studies.docx

Manuscript File(s):

File No. 1 : Manuscript- Anti inflammatory DM Neovascular.docx File No. 2 :
Figure legend.docx File No. 3 : Table 1.docx

--

This email has been checked for viruses by AVG.

<https://www.avg.com>

Rohan JCF Corp <rohan@jcfcorp.com>
Kepada: maharaniroxy@gmail.com

8 Juli 2022 10.45

Dear Dr. Maharani,

Thank you for submitting your valuable work to our Journal. There is an author fee USD 1000 associated with the accepted articles.

Please confirm and submit your article by using the link below to start the review process.

Link: <http://rds.manuscriptmanager.net>

Kindly get back to us for further queries.

Have a great day!

Regards,
Rohan Reddy
RDS

[Kutipan teks disembunyikan]



maharani roxy <maharaniroxy@gmail.com>

Follow-Up: Online Paper Submission

1 pesan

Rohan JCF Corp <rohan@jcfcorp.com>
Kepada: maharaniroxy@gmail.com

8 Juli 2022 20.39

On Fri, Jul 8, 2022 at 8:15 AM Rohan JCF Corp <rohan@jcfcorp.com> wrote:

Dear Dr. Maharani,

Thank you for submitting your valuable work to our Journal. There is an author fee USD 1000 associated with the accepted articles.

Please confirm and submit your article by using the link below to start the review process.

Link: <http://rds.manuscriptmanager.net>

Kindly get back to us for further queries.

Have a great day!

Regards,
Rohan Reddy
RDS

On Thu, Jul 7, 2022 at 5:20 PM Rohan JCF Corp <rohan@jcfcorp.com> wrote:

Dear Dr. Maharani,

Thank you for submitting your valuable work to our Journal. There is an author fee USD 1000 associated with the accepted articles.

Please confirm and submit your article by using the link below to start the review process.

Link: <http://rds.manuscriptmanager.net>

Kindly get back to us for further queries.

Have a great day!

Regards,
Rohan Reddy
RDS

On Thu, Jul 7, 2022 at 3:53 PM Info SBDR <info@soc-bdr.org> wrote:

-----Ursprüngliche Nachricht-----

Von: maharaniroxy@gmail.com [mailto:maharaniroxy@gmail.com]

Gesendet: Donnerstag, 7. Juli 2022 00:17

An: info@soc-bdr.org

Betreff: Online Paper Submission

First Name : Maharani
Middle Initial : Laillyza
Last Name : Apriasari
Title : Dr
Institution : University of Lambung Mangkurat
Department : Oral Medicine

Address 1 : Veteran street no. 128B

Address 2 :

City : Banjarmasin
State :
ZIP/Postal Code : 70239
Country : Indonesia

Date of Birth (MM/DD/YYYY):

Phone Number :

E-mail : maharaniroxy@gmail.com

Cover Letter:

Filename : COVER LETTER-Review of Diabetic Studies.docx

Manuscript File(s):

File No. 1 : Manuscript- Anti inflammatory DM Neovascular.docx File No. 2 :
Figure legend.docx File No. 3 : Table 1.docx

--

This email has been checked for viruses by AVG.

<https://www.avg.com>



maharani roxy <maharaniroxy@gmail.com>

RDS-2022-7-2 Manuscript submission confirmation

1 pesan

Review of Diabetic Studies <rds@manuscriptmanager.net>

9 Juli 2022 05.57

Balas Ke: Rohan Reddy <rohan@jfcfcorp.com>

Kepada: maharaniroxy@gmail.com

Manuscript: RDS-2022-7-2 - Anti Inflammatory Effect of Channa micropeltes Extract
in Angiogenesis of Diabetes Wound Healing

Authors: Maharani Laillyza Apriasari (Corresponding Author), Dewi Puspitasari (Co-author), Juliyatin Putri Utami
(Co-author)

Date submitted: 2022-07-08

Dear Dr. Apriasari

Thank you very much for submitting the above manuscript. Please refer to the manuscript number in all
correspondence concerning the manuscript as listed above.

The manuscript will now be forwarded to our Editors and reviewers and we shall inform you as soon as a decision
has been made by the editorial board.

The progress of your manuscript can be followed in the progress report that can be accessed from your account
overview.

Sincerely,
The Editorial Office

YOUR SIGN IN INFORMATIONWebsite: <https://www.manuscriptmanager.net/rds>Email: maharaniroxy@gmail.com

Forgot password or not signed in before?

Click the URL below to create/reset your password.

[https://www.manuscriptmanager.net/sLib/v4/retrieve_pw.php?paramScreen=
EbCodUIbZQ1eMrxls4WJboyjOPBDdQrMAIq9/SXGTc=](https://www.manuscriptmanager.net/sLib/v4/retrieve_pw.php?paramScreen=EbCodUIbZQ1eMrxls4WJboyjOPBDdQrMAIq9/SXGTc=)



maharani roxy <maharaniroxy@gmail.com>

Manuscript Received and Peer-review Acceptance - RDS-2022-7-2

3 pesan

Rohan JCF Corp <rohan@jcfcorp.com>

9 Juli 2022 10.29

Kepada: maharaniroxy@gmail.com, dewident@ulm.ac.id, juliyatin.utami@ulm.ac.id

Dear Dr. Maharani Laillyza Apriasari,

Thank you for submitting your valuable work to our Journal.

Kindly confirm the publication charges 1000 USD upon the article acceptance. So that we can initiate the review process.

Awaiting your reply.

Regards,
Rohan Reddy
RDS

On Sat, Jul 9, 2022 at 3:27 AM Review of Diabetic Studies <rds@manuscriptmanager.net> wrote:

Manuscript: RDS-2022-7-2 - Anti Inflammatory Effect of Channa micropeltes Extract in Angiogenesis of Diabetes Wound Healing

Authors: Maharani Laillyza Apriasari (Corresponding Author), Dewi Puspitasari (Co-author), Juliyatin Putri Utami (Co-author)

Date submitted: 2022-07-08

Automatic notification:

Dear Rohan Reddy

The above manuscript has been submitted to the Editorial Office. Please login and process it at your earliest convenience.

YOUR SIGN IN INFORMATION

Website: <https://www.manuscriptmanager.net/rds>

Email: rohan@jcfcorp.com

Forgot password or not signed in before?

Click the URL below to create/reset your password.

https://www.manuscriptmanager.net/sLib/v4/retrieve_pw.php?paramScreen=Mj31IVrpFhRlnbWMkdsC7tyz1QhMZg+yD917nU/76kc=

maharani roxy <maharaniroxy@gmail.com>
Kepada: Rohan JCF Corp <rohan@jcfcorp.com>
Cc: dewident@ulm.ac.id, juliyatin.utami@ulm.ac.id

9 Juli 2022 13.01

Dear Rohan,

Thank you for the information. Yes, i agree to pay it.

Best regards,

Maharani L. Apriasari

[Kutipan teks disembunyikan]

Rohan JCF Corp <rohan@jcfcorp.com>
Kepada: maharani roxy <maharaniroxy@gmail.com>
Cc: dewident@ulm.ac.id, juliyatin.utami@ulm.ac.id

9 Juli 2022 13.06

Dear Dr. Maharani,

Thank you for confirming the publication charges.

Soon, we will get back to you with the review comments.

Regards,
Rohan Reddy
RDS

[Kutipan teks disembunyikan]



maharani roxy <maharaniroxy@gmail.com>

**Manuscript Accepted for Publication with Minor Revision -
RDS-2022-7-2**

1 pesan

Rohan JCF Corp <rohan@jcfcorp.com>
Kepada: maharani roxy <maharaniroxy@gmail.com>
Cc: dewident@ulm.ac.id, juliyatin.utami@ulm.ac.id

12 Juli 2022 10.53

Dear Dr. Maharani,

Greetings,

We have received comments for your article entitled "Anti Inflammatory Effect of Channa micropeltes Extract in Angiogenesis of Diabetes Wound Healing" Our decision is to accept the article with minor revision.

Review comments:

I went through the manuscript and found it to have a very good concept with basic laboratory experimental research, however it needs to be revised based on the comments and suggestions I put as Review points on the corresponding points in the manuscript.

Please find the attached file. We request you to kindly follow the review suggestions and send us the revised manuscript by 20 July 2022. So, we will forward the article to our English editing team.

Meanwhile, we request you to confirm your mode of payment 1) Credit Card or 2) Bank Transfer. An invoice can be raised accordingly.

Feel free to contact us for further queries.

Regards,
Rohan Reddy
RDS

On Sat, Jul 9, 2022 at 10:36 AM Rohan JCF Corp <rohan@jcfcorp.com> wrote:

Dear Dr. Maharani,

Thank you for confirming the publication charges.

Soon, we will get back to you with the review comments.

Regards,
Rohan Reddy
RDS

On Sat, Jul 9, 2022 at 10:31 AM maharani roxy <maharaniroxy@gmail.com> wrote:

Dear Rohan,

Thank you for the information. Yes, i agree to pay it.

Best regards,

Maharani L. Apriasari

Pada tanggal Sab, 9 Jul 2022 10.29, Rohan JCF Corp <rohan@jcfcorp.com> menulis:
Dear Dr. Maharani Laillyza Apriasari,

Thank you for submitting your valuable work to our Journal.

Kindly confirm the publication charges 1000 USD upon the article acceptance. So that we can initiate the review process.

Awaiting your reply.

Regards,
Rohan Reddy
RDS

On Sat, Jul 9, 2022 at 3:27 AM Review of Diabetic Studies

<rds@manuscriptmanager.net> wrote:

Manuscript: RDS-2022-7-2 - Anti Inflammatory Effect of Channa micropeltes Extract in Angiogenesis of Diabetes Wound Healing

Authors: Maharani Laillyza Apriasari (Corresponding Author), Dewi Puspitasari (Co-author), Juliyatin Putri Utami (Co-author)

Date submitted: 2022-07-08

Automatic notification:

Dear Rohan Reddy

The above manuscript has been submitted to the Editorial Office. Please login and process it at your earliest convenience.

YOUR SIGN IN INFORMATION

Website: <https://www.manuscriptmanager.net/rds>

Email: rohan@jcfcorp.com

Forgot password or not signed in before?

Click the URL below to create/reset your password.

https://www.manuscriptmanager.net/sLib/v4/retrieve_pw.php?paramScreen=Mj31IVrpFhRlnbWMkdsC7tyz1QhMZg+yD917nU/76kc=



Manuscript 7-2 (3).docx

35K

1. Introduction

Indonesia ranks sixth among countries with a high prevalence of diabetes mellitus (DM). In an uncontrolled state, DM will result in various oral problems such as xerostomia, candidiasis, stomatitis, gingivitis and periodontitis. The healing of such conditions is often complicated due to hyperglycemia that initiates chronic inflammation [1-3]. Previous study revealed that *Channa micropeltes* ointment at 20% concentration or *Channa striata* ointment at 10% concentration applied topically can accelerate wound healing in a DM rat model. Both species are categorized in the same genus and contain albumin as well as omega-6 that acts as an antioxidant and anti-inflammatory [3,4]. As an antioxidant, *Channa micropeltes* extract elevates superoxide dismutase (SOD) activity and lowers malondialdehyd (MDA) level on Day 7 [2]. As an anti-inflammatory, the topical application of *Channa micropeltes* at 20% concentration on the back skin of a diabetic rat model can increase the number of macrophage and lymphocyte cells on Day 8 and gradually reduce it on Day 14 [1].

Macrophage is the key inflammatory process in wound healing. Reduction in macrophage number at the end of inflammatory stage demonstrates tissue recovery by producing growth factors and cytokines and inducing as well as terminating angiogenesis [5,6]. Macrophage is also produced Nuclear Factor kappa B (NF- κ B) that regulates the inflammatory response of metabolic disease such as DM. A state of hyperglycemia in DM will increase reactive oxygen species (ROS) and advanced glycation end products (AGEs) that elevate chronic inflammation through the activation of NF- κ B . This will change vascular endothelial growth factor (VEGF) expression that will generate the damage to blood vessels in the angiogenesis process [7,8].

The extract of *Channa micropeltes* has shown to promote wound healing on the skin of diabetic rat model by reducing macrophage number at the end of inflammatory stage [3]. There has been no study that explores the effect of *Channa micropeltes* application on NF- κ B , VEGF, and neovascular cells that are pivotal components in the DM wound healing process. Based on that, a study to analyze the expression of NF- κ B , VEGF and neovascular cells number at the inflammatory stage of the DM wound healing process was warranted.

2. Methods

This study was an experimental laboratory research study incorporating a post-test only control group design. It was approved by Ethical Clearance Committee, Faculty of Dentistry, Universitas

Lambung Mangkurat, Banjarmasin, South Kalimantan, Indonesia, with number 111/KEPKG-FKGULM/EC/III/2020.

2.1 Manufacturing Channa micropeltes and Channa striata extract

Preparing both *Channa micropeltes* and *Channa striata* extract used fresh fish weighing 600-1000 grams. Each extract was later steamed in a pan for 25-35 minutes at a temperature of 60° Celsius. The flesh was enclosed with flannelette and pressed in a hydraulic device. Furthermore, *Channa micropeltes* and *Channa striata* were centrifuged for 15 minutes at a speed of 6000 rpm. Each extract was kept inside a dark glass bottle and then covered with aluminum foil and clean pack.

2.2 Formulation of Channa micropeltes and Channa striata ointment

Adeps lanae (Asian chemicals, Semarang) in a weight of 16.875 grams and vaselin flavum (PT. Brataco, 1295578) in a weight of 23.125 grams were used in the formulation of the *Channa micropeltes* ointment. Meanwhile, a combination of 16.875 grams adeps lanae and 28.125 grams vaselin flavum were combined in the formulation of *Channa striata* ointment. Adeps lanae was initially poured into different tubes for each extract and later added gradually with either *Channa micropeltes* at 20% concentration or *Channa striata* at 10% concentration. After the extract was fully absorbed by adeps lanae, the mixture was then mashed to obtain a homogenous consistency. Subsequently, the composition was further mixed with vaselin flavum and mashed again until homogenous.

2.3 In vivo study

This study included 2-3 months old male Wistar (*Rattus norvegicus*) rats (weight, 250-300 grams) obtained from an animal laboratory at the Faculty of Medicine, University of Lambung Mangkurat. The 24 rat specimens were kept in cages, and the temperature and humidity were set within ± 25 °C and 60%, respectively. They were fed standard BR-II, and they had access to boiled water *ad libitum*. Rats with hyperglycemia were obtained by injecting streptozotocin (STZ) at 35 mg/kg dosage until the blood glucose level was over 126 mg/dL-1; non-diabetic rats were ones without intervention. All animals were divided into 3 treatment groups consisting of 20% *Channa micropeltes* extract ointment, 10% *Channa striata* extract ointment, and placebo

ointment as control. Each substance was applied topically 3 times daily (every 6-8 hours). An incisional wound was made on the back of the rats with 1 cm length and 1 mm depth using sterile scalpel under inhaled anesthesia of 5 ml diethyl ether.

After the 4th and 8th day of application, rats were euthanized by inhaling a lethal dosage of diethyl ether. The back skin was then biopsied for histopathology examination using hematoxylin eosin (HE) to evaluate macrophages and neovascular cells, and immunohistochemistry (IHC) to evaluate NF- κ B and VEGF. The number of macrophages and neovascular cells were calculated in 3 different field locations using a light microscope (Olympus, WA) at 400 magnifications and subsequently calculated for its average. IHC staining was performed using anti-mouse NF- κ B monoclonal antibody (Santa Cruz Biotechnology Inc, Santa Cruz, CA, NF- κ B p65 (F-6): sc 8008) and anti-mouse VEGF monoclonal antibody (Santa Cruz Biotechnology Inc, Santa Cruz, CA, VEGF (C1): sc 7269). Positivity NF- κ B expression was defined as only distinct nuclear immunostaining, which is considered as activated NF- κ B in the studied field at 100 magnifications.

2.4 Data analysis

The results were analyzed using a 2-way analysis of variance parametric test based on the Shapiro-Wilk normality test and Levene's variance homogeneity test. The results showed normal data distribution and homogenous data variances. Consequently, further analysis by means of a *post hoc* Bonferroni test was conducted with a statistical significance of $p < 0.05$.

3. Results

Table 1 shows the results of NF- κ B analysis. The highest expression of NF- κ B was observed in the control group (Group III) on Day 4 (15.5 ± 2.38), and the lowest was in the treatment of 20% *Channa micropeltes* extract ointment (Group I) (4.75 ± 0.96) and 10% *Channa striata* extract ointment (Group II) (5.75 ± 1.71) on Day 8. The expression of NF- κ B between Group I and 10% *Channa striata* extract ointment (Group II) treatment groups did not show any difference ($p > .05$; Table 1). The statistical significance value between treatment group and day was $p > 0.05$, demonstrating no interaction between treatment groups and days on NF- κ B expression.

The highest expression of VEGF was observed in Group I (14.75 ± 0.96) on Day 8, whereas the lowest was in Group III (7.00 ± 1.41) on Day 4. The expression of VEGF showed statistically

significant differences in all groups ($p < 0.05$; Table 1). The significance value between treatment groups and days was $p > 0.05$, demonstrating no interaction between treatment group and day on VEGF expression.

The highest count of neovascular cells was observed in Group I (11.00 ± 2.16) on Day 8, while the lowest was in Group III (5.50 ± 0.58) on Day 4. The count of neovascular cells showed statistically significant differences in all groups ($p < 0.05$; Table 1). The statistical significance value between treatment groups and days was $p > 0.05$, demonstrating no interaction between treatment groups and days on the number of neovascular cells.

4. Discussion

DM is characterized with an increase in blood glucose level that induces glycation reaction. This process will result in amadori production to formulate toxic proteins (AGEs). Interaction between AGEs and a receptor advanced glycation end product (RAGE) will increase the signal for nicotinamide adenine dinucleotide phosphate (NADPH) oxidase which produces superoxide anion. This process elevates the production of reactive oxygen species (ROS) which are the key for molecular signaling as well as the development of inflammatory disorders such as DM. Excessive production of ROS will complicate the healing process of wounds in DM [2,9].

Channa micropeltes contains albumin and omega-6 fatty acid. Albumin can decrease ROS by cutting chained oxidative reaction in the ROS formation's process. Albumin can bind metal ions and also catch oxygen that processing hydrogen peroxide into non radical compound. Omega-6 fatty acid, especially arachnoidic acid are the keys to anti-inflammatory processes. It plays the role in stimulating macrophages to release growth factors, such as VEGF. Arachidonic acid will be metabolized through an enzymatic mechanism such as the 5-lipoxygenase and cyclo-oxygenase pathways that produce leukotrienes, prostaglandins, and thromboxane A₂. These can stimulate cell migration and new local vascularization in the wound healing process of DM [4,10].

In previous studies, *Channa micropeltes* extract ointment at 20% concentration and *Channa striata* extract ointment at 10% concentration were shown to promote the wound healing process in DM. *Channa micropeltes* and *Channa striata* are categorized in the same genus. Both species contain albumin, the secondary antioxidant that can bind metal ion in ROS formation [1,2]. ROS induces an inflammatory response through the activation of Nuclear Factor kappa B (NF- κ B).

NF-κB signal is the main key of chronic inflammation in DM [7,8]. This is demonstrated by the study result on Day 4 that reveals the highest expression of **NF-κB** in control group, while the result for 20% *Channa micropeltes* extract application was comparable to 10% *Channa striata* extract application.

Our study result on Day 8 demonstrates the reduction of NF-κB expression in both *Channa micropeltes* extract ointment at 20% concentration and *Channa striata* extract ointment at 10% concentration when compared to the control. Topical application of *Channa micropeltes* extract at 20% concentration or *Channa striata* extract at 10% concentration may reduce excessive ROS, thereby suppressing **NF-κB** expression. Both extracts possess potential as natural substances that may inhibit the expression of NF-κB. Previous studies reveal that the impediment of pro-inflammatory **NF-κB** from therapeutical application of several natural and synthetic ingredients will be a good target to manage vascular complication in DM [7]. A prolonged inflammatory response can be resolved by the inhibition of **NF-κB**. As an anti-inflammatory substance, *Channa micropeltes* will reduce inducible nitric oxide synthase (iNOS) and cyclooxygenase 2 (COX2) that suppress the NF-κB gene regulator. This will prevent prolonged inflammation in the wound healing process of DM [11,12].

Excessive activation of NF-κB will cause abnormal DNA transcription which includes various gene expression of vascular complications occurring in VEGF, Platelet Derived Growth Factor (PDGF), Endothelin-1 (ET-1) and Transforming Growth Factor beta (TGF-β) that cause vascular cell damage [7]. VEGF as pro-angiogenic modulators encounter down regulation in DM, disturbing the angiogenesis process [13,14]. Prior studies demonstrate Vascular Endothelial Growth Factor A (VEGF-A) protein and messenger ribonucleic acid (mRNA) level in the wound of a diabetic rat model which shows reduction when compared to the group with a normal wound. DM leads to the decrease of angiogenesis in wound healing, so that it lessens vascular and capillary density [13].

The angiogenic effect is initiated by VEGF-A binding to Vascular Endothelial Growth Factor Receptor-2 (VEGFR-2). Angiogenesis stimulation through PI3K-Akt-eNOS will cause endothelial cell to migrate, proliferate, and differentiate. Molecular signals will be commenced by phosphatidylinositol 3 kinase from serine/threonine kinase Akt/protein kinase B. Akt/PKB through the phosphorylation of endothelial nitric oxide synthesis on Ser 1177, and will stimulate NO production, vasodilatation, and endothelial cell migration [15,16]. This result presents that

Channa micropeltes extract ointment at 20% concentration increases the highest expression of VEGF when compared to *Channa striata* extract ointment at 10% concentration or the control on Day 8. This exhibits the potential of *Channa micropeltes* extract ointment at 20% concentration to promote angiogenesis on the DM wound healing process.

Previous study by Carabelly et al. [1] reveals that the application of *Channa micropeltes* extract ointment at 20% concentration may elevate macrophage number on Day 8 and reduce them on Day 14. Macrophage regulates angiogenesis signals in neovascular along the formation of granulation tissue process [17]. This concept is in accordance with this study as the number of macrophages was observed the highest on Day 8 and followed by the increase of neovascular cell number by the application of *Channa micropeltes* extract ointment at 20% concentration on Day 8. The highest number of neovascular cells also was observed in the application of *Channa micropeltes* extract ointment at 20% concentration when compared to *Channa striata* extract ointment at 10% concentration or the control in Day 8. This study did not continue to further days to limit the parameters.

We can conclude that the application of *Channa micropeltes* extract ointment at 20% concentration on the wound of a diabetic rat model can reduce the expression of NF- κ B. The anti-inflammatory effect of *Channa micropeltes* can elevate the expression of VEGF and the number of neovascular cells in angiogenesis process of diabetic wound healing. Our findings require further research using different parameters, adding time of evaluation, and using larger experimental animals.

Acknowledgements: This study was financed by the Faculty of Dentistry, University of Lambung Mangkurat. The authors express their gratitude.

Conflicts of interest statement: The authors have no conflicts of interest to report.

Ethical approval: Approval for this study was provided by the Ethical Clearance Committee, Faculty of Dentistry, Universitas Lambung Mangkurat, Banjarmasin, South Kalimantan, Indonesia (#111/KEPKG-FKGULM/EC/III/2020).



maharani roxy <maharaniroxy@gmail.com>

Re: Follow-Up: Manuscript Accepted for Publication with Minor Revision - RDS-2022-7-2

3 pesan

Rohan JCF Corp <rohan@jcfcorp.com>
Kepada: maharani roxy <maharaniroxy@gmail.com>
Cc: dewident@ulm.ac.id, juliyatn.utami@ulm.ac.id

12 Juli 2022 21.20

On Tue, Jul 12, 2022 at 8:23 AM Rohan JCF Corp <rohan@jcfcorp.com> wrote:

Dear Dr. Maharani,

Greetings,

We have received comments for your article entitled "Anti Inflammatory Effect of Channa micropeltes Extract in Angiogenesis of Diabetes Wound Healing" Our decision is to accept the article with minor revision.

Review comments:

I went through the manuscript and found it to have a very good concept with basic laboratory experimental research, however it needs to be revised based on the comments and suggestions I put as Review points on the corresponding points in the manuscript.

Please find the attached file. We request you to kindly follow the review suggestions and send us the revised manuscript by 20 July 2022. So, we will forward the article to our English editing team.

Meanwhile, we request you to confirm your mode of payment 1) Credit Card or 2) Bank Transfer. An invoice can be raised accordingly.

Feel free to contact us for further queries.

Regards,
Rohan Reddy
RDS

On Sat, Jul 9, 2022 at 10:36 AM Rohan JCF Corp <rohan@jcfcorp.com> wrote:

Dear Dr. Maharani,

Thank you for confirming the publication charges.

Soon, we will get back to you with the review comments.

Regards,
Rohan Reddy
RDS

On Sat, Jul 9, 2022 at 10:31 AM maharani roxy <maharaniroxy@gmail.com> wrote:

Dear Rohan,

Thank you for the information. Yes, i agree to pay it.

Best regards,

Maharani L. Apriasari

Pada tanggal Sab, 9 Jul 2022 10.29, Rohan JCF Corp <rohan@jcfcorp.com> menulis:

Dear Dr. Maharani Laillyza Apriasari,

Thank you for submitting your valuable work to our Journal.

Kindly confirm the publication charges 1000 USD upon the article acceptance. So that we can initiate the review process.

Awaiting your reply.

Regards,
Rohan Reddy
RDS

On Sat, Jul 9, 2022 at 3:27 AM Review of Diabetic Studies <rds@manuscriptmanager.net> wrote:
Manuscript: RDS-2022-7-2 - Anti Inflammatory Effect of Channa micropeltes Extract
in Angiogenesis of Diabetes Wound Healing

Authors: Maharani Laillyza Apriasari (Corresponding Author), Dewi Puspitasari (Co-author), Juliyatin Putri Utami (Co-author)
Date submitted: 2022-07-08
Automatic notification:

Dear Rohan Reddy

The above manuscript has been submitted to the Editorial Office. Please login and process it at your earliest convenience.

YOUR SIGN IN INFORMATION

Website: <https://www.manuscriptmanager.net/rds>
Email: rohan@jfcfcorp.com

Forgot password or not signed in before?

Click the URL below to create/reset your password.

https://www.manuscriptmanager.net/sLib/v4/retrieve_pw.php?paramScreen=Mj31IVrpFhRInbWWMkdsC7tyz1QhMZg+yD917nU/76kc=

maharani roxy <maharaniroxy@gmail.com>
Kepada: Rohan JCF Corp <rohan@jfcfcorp.com>


13 Juli 2022 08.05

Dear Rohan Reddy,

Thank you for the fast reponse. I have revised the manuscript, and i hope it is in accordance to the reviewer. i will pay by Bank Transfer.

Best Regards,
Maharani Laillyza Apriasari

[Kutipan teks disembunyikan]

 **Manuscript 7-2 (3)-Revised.docx**
41K

Rohan JCF Corp <rohan@jfcfcorp.com>
Kepada: maharani roxy <maharaniroxy@gmail.com>

13 Juli 2022 11.34

Dear Dr. Maharani,

Greetings,

Thank you for sending us the revised manuscript.

Please find the attached wire transfer invoice. We request you to kindly process the payment by 18 July 2022, and send us the payment receipt for our reference. So, we can proceed further.

Awaiting your reply.

Regards,
Rohan Reddy
RDS

[Kutipan teks disembunyikan]

 **RDS-7-2 Wire Invoice.pdf**
71K

ABSTRACT

Background: *Channa micropeltes* extract contains albumin and Omega-6 which possess anti-oxidant and anti-inflammatory agent that can promote macrophages in wound healing process of diabetes mellitus (DM). **Objective:** to analyze Nuclear Factor kappa B (NFkB) and Vascular Endothelial Growth Factor (VEGF) expression as well as neovascular cells in the inflammatory stage of DM wound healing. **Materials and methods:** The twenty-four males *Rattus novergicus* were divided into three groups that were 20% *Channa micropeltes* ointment (Group I), 10% *Channa striata* extract ointment (Group II), and placebo ointment as control (Group III). Ointments were applied three times daily. **Results:** The highest expression of NFkB was observed in Group III on day 4 (15.50 ± 2.38), while the lowest was in treatment of Group I and Group II on day 8 (4.75 ± 0.96). The highest expression of VEGF was observed in Group I on day 8 (14.75 ± 0.96), while the lowest was Group III on day 4 (7.00 ± 1.41). The highest count of neovascular cells was observed in Group I on day 8 (11.00 ± 2.16), while the lowest was in Group III on day 4 (5.50 ± 0.58). **Conclusion:** *Channa micropeltes* have an anti-inflammatory effect by regulating NFkB expression and elevating VEGF expression in angiogenesis process of DM wound healing.

Keywords: *Channa micropeltes*, *nfkb*, *vegf*, *neovascular*, *wound healing*, *diabetes mellitus*

Introduction

Indonesia is ranked sixth among the countries with high prevalence of Diabetes mellitus in the world. In uncontrolled state, Diabetes mellitus will result in the variance of oral problems such as xerostomia, candidiasis, stomatitis, gingivitis and periodontitis. The healing of such conditions is often complicated due to hyperglycemia that initiates chronic inflammation.^{1,2,3} Previous study revealed that *Channa micropeltes* ointment at 20% concentration or *Channa striata* ointment at 10% concentration that was applied topically can accelerate wound healing in diabetes mellitus rat model. Both species are categorized in the same genus and contain albumin as well as omega 6 that act as anti-oxidant and anti-inflammation.^{3,4} As antioxidant, *Channa micropeltes* extract elevate Superoxide dismutase (SOD) activity and lower Malondialdehyd (MDA) level on day 7.² As anti-inflammation, the topical application of *Channa micropeltes* at

20% concentration on the back skin of diabetic rat model could increase the number of macrophage and lymphocyte cells on day 8 and gradually reduce it on day 14.¹

Macrophage is the key of inflammatory process in wound healing. Reduction in macrophage number at the end of inflammatory stage demonstrates tissue recovery by producing growth factors, cytokines, and induce as well as terminate angiogenesis.^{5,6} Macrophage is also produced Nuclear Factor kappa B (NFkB) that regulates inflammatory response of metabolic disease such as diabetes mellitus. Hyperglycemia state in diabetes mellitus will increase Reactive Oxygen Species (ROS) and Advanced Glycation End Products (AGEs) that elevate chronic inflammation through the activation of NFkB. This will change Vascular Endothelial Growth Factor (VEGF) expression that will generate the damage of blood vessel cell in angiogenesis process.^{7,8}

The extract of *Channa micropeltes* has been proven to promote wound healing on the skin of diabetic rat model by reducing macrophage number at the end of inflammatory stage.³ There has been no study that explore the effect of *Channa micropeltes* application on NFkB, VEGF, and neovascular cells that are pivotal components in diabetes mellitus wound healing process. Based on that, a study to analyze the expression of NFkB, VEGF and neovascular cells number at the inflammatory stage of diabetes mellitus wound healing process should be conducted.

Materials and Methods

This study was an experimental laboratory research incorporating post-test only control group design. It was approved by Ethical Clearance Committee, Faculty of Dentistry, Universitas Lambung Mangkurat, Banjarmasin, South Kalimantan, Indonesia, with number 111/KEPKG-FKGULM/EC/III/2020.

Manufacturing *Channa micropeltes* and *Channa striata* extract

Preparing both *Channa micropeltes* and *Channa striata* extract used fresh fish weighed 600-1000 g. Each of it was later steamed in a pan for 25-35 minutes under 60° temperature. The flesh were enclosed with flannelette and pressed in hydraulic device. Further, *Channa micropeltes* and *Channa striata* were centrifuged for 15 minutes within 6000 rpm speed. Each extract was kept inside dark glass bottle and then covered with aluminum foil and clean pack.

Formulation of *Channa micropeltes* and *Channa striata* ointment

Adeps lanae (Asian chemicals, Semarang) in a weight of 16.875 g and vaselin flavum (PT. Brataco, 1295578) in a weight of 23.125 g were used in the formulation of *Channa micropeltes* ointment. Meanwhile, a combination of 16.875 g adeps lanae and 28.125 g vaselin flavum were utilized in the formulation of *Channa striata* ointment. Adeps lanae was initially poured into different tubes for each extract and later added gradually with either *Channa micropeltes* at 20% concentration or *Channa striata* at 10% concentration. After the extract was fully absorbed by adeps lanae, the mixture was then mashed to obtain homogenous consistency. Subsequently, the composition was further mixed with vaselin flavum and mashed again until homogenous.

Comment [Ma1]: Both products to mentioned trade mark, source and date if related

In Vivo Study

This study included 2-3 months-old male Wistar (*Rattus norvegicus*) rats (weight, 250–300 g) obtained from animal laboratory, Faculty of Medicine, University of Lambung Mangkurat. The total of 24 rats were kept in cages, and the temperature and humidity were set within ± 25 °C and 60%, respectively. They were fed standard BR-II, and they had access to boil water ad libitum. Rats with hyperglycemia was obtained by injecting Streptozotosin (STZ) at 35 mg/kg dosage until the blood glucose level was over 126 mg/dL-1, while non Diabetic Rats is rats without intervention. All animals were divided into 3 treatment groups consisting of 20% *Channa micropeltes* extract ointment, 10% *Channa striata* extract ointment, and placebo ointment as control. Each substance was applied topically three times daily (every 6-8 hours). Incisional wound was made on the back of the rats with 1 cm length and 1 mm depth using sterile scalpel under inhaled anesthesia of 5 ml diethyl ether.

After the 4th and 8th day of application, rats were euthanized by inhaling lethal dosage of diethyl ether. The back skin was then biopsied for histopathology examination using Haematoxyllin Eosin (HE) to evaluate macrophages and neovascular cells, and Immunohistochemistry (IHC) to evaluate NF- κ B and VEGF. The number of macrophages and neovascular cells were calculated in three different field locations using a light microscope that were counted using light microscope (Olympus, United States) at 400 magnifications and subsequently calculated for its average. Immunohistochemistry (IHC) staining was performed using anti-mouse NF- κ B monoclonal antibody (Santa Cruz

Biotechnology Inc. NF- κ B p65 (F-6) : sc 8008) and anti-mouse VEGF monoclonal antibody (Santa Cruz Biotechnology Inc. VEGF (C1) : sc 7269). Positivity NF- κ B expression was defined as only distinct nuclear immunostaining, which is considered as activated NF- κ B in the studied field at 100 magnification.

Statistical Analysis

The results were analyzed using two-way analysis of variance parametric test based on Shapiro Wilk normality test and Levene's variance homogeneity test. The results showed normal data distribution and homogenous data variances. Consequently, further analysis by means of a Post Hoc Bonferroni test was conducted with significance $p < 0.05$.

Results

The results of NF κ B analysis were shown in table 1. The highest expression of NF κ B was observed in the control group (Group III) on day 4 (15.5 ± 2.38), while the lowest was in the treatment of 20% *Channa micropeltes* extract ointment (Group I) (4.75 ± 0.96) and 10% *Channa striata* extract ointment (Group II) (5.75 ± 1.71) on day 8. The expression of NF κ B between Group I and 10% *Channa striata* extract ointment (Group II) treatment groups did not show any difference ($p > 0.05$; Table 1). The significance value between treatment group and day were $p > 0.05$ that represents no interaction between treatment groups and days on NF κ B expression.

The highest expression of VEGF was observed in Group I (14.75 ± 0.96) on day 8, where as the lowest was in Group III (7.00 ± 1.41) on day 4. The expression of VEGF showed significant differences in all groups ($p < 0.05$; Table 1). The significance value between treatment groups and days were $p > 0.05$ that represents no interaction between treatment group and day on VEGF expression.

The highest count of neovascular cells was observed in Group I (11.00 ± 2.16) on day 8, while the lowest was in Group III (5.50 ± 0.58) on day 4. The count of neovascular cells showed significant differences in all groups ($p < 0.05$; Table 1). The significance value between treatment groups and days were $p > 0.05$ that represents no interaction between treatment groups and days on the number of neovascular cells.

Discussion

Diabetes mellitus is characterized with an increase in blood glucose level that induces glycation reaction. This process will result in amatory production to formulate toxic protein called Advanced Glycation End Products (AGEs). Interaction between AGE and Receptor Advanced Glycation End Product (RAGE) will increase the signal for nicotinamide adenine dinucleotide phosphate (NADPH) oxidase which produces superoxide anion. This process elevates the production of Reactive Oxygen Species (ROS) which are the key for molecular signaling as well as the development of inflammatory disorders such as diabetes mellitus. Excessive production of ROS will complicate the healing process of wound in diabetes mellitus.^{2,9}

Channa micropeltes contains albumin and omega-6 fatty acid. Albumin can decrease ROS by cutting chained oxidative reaction in the ROS formation's process. Albumin can bind metal ions and also catch oxygen that processing hydrogen peroxide into non radical compound. Omega-6 fatty acid, especially arachnoidic acid are the key of anti inflammatory. It plays the role in stimulating machropages to release growth factors, such as VEGF. Arachinodic acid will be metabolized through an enzymatic mechanism such as the 5-lipoxygenase and cyclo-oxygenase pathways that produce leukotrienes, prostaglandins, and thromboxane A2. These can stimulates the cell migration and new local vascularization in wound healing process of diabetes mellitus.^{4,10}

In previous studies, *Channa micropeltes* extract oinment at 20% concentration and *Channa striata* extract ointment at 10% concentration were proven to promote wound healing process in diabetes mellitus. *Channa micropeltes* and *Channa striata* are categorized in same genus. Both species contain albumin, the secondary antioxidant that can bind metal ion in ROS formation.^{1,2} ROS induce inflammatory response through the activation of Nuclear Factor kappa B (NFkB). NFkB signal is the main key of chronic inflammation in diabetes mellitus.^{7,8} This is proven by this study result on Day 4 that reveals the highest expression of NFkB in control group, while the result for 20% *Channa micropeltes* extract application was comparable to 10% *Channa striata* extract application.

Study result on day 8 demonstrates the reduction of NFkB expression in both *Channa micropeltes* extract ointment at 20% concentration and *Channa striata* extract ointment at 10% concentration when compared to control. Topical application of *Channa micropeltes* extract at 20% concentration or *Channa striata* extract at 10% concentration may reduce excessive ROS,

thus suppressing NFκB expression. Both extract possess potential as natural substance that may inhibit the expression of NFκB. Previous study reveals that the impediment of proinflammatory NFκB from therapeutical application of several natural and synthetic ingredients will be a good target to manage vascular complication in diabetes mellitus.⁷ Prolonged inflammatory response can be resolved by the inhibition of NFκB. As anti-inflammatory substance, *Channa micropeltes* will reduce inducible Nitric Oxide Synthase (iNOS) and Cyclooxygenase 2 (COX2) that suppress NFκB gene regulator. This will prevent prolonged inflammation in wound healing process of diabetes mellitus.^{11,12}

Excessive activation of NFκB will cause abnormal DNA transcription which include various gene expression of vascular complication occurring in VEGF, Platelet Derived Growth Factor (PDGF), Endothelin-1 (ET-1) and Transforming Growth Factor beta (TGF-β) that cause vascular cell damage.⁷ VEGF as pro-angiogenic modulators encounter down regulation in diabetes mellitus, thus disturbing the angiogenesis process.^{13,14} Prior study demonstrates Vascular Endothelial Growth Factor A (VEGF-A) protein and messenger Ribonucleic Acid (mRNA) level in the wound of diabetic rat model which shows reduction when compared to the group with normal wound. Diabetes mellitus leads to the decrease of angiogenesis in wound healing, so that it lessens vascular and capillary density.¹³

The angiogenic effect is initiated by VEGF-A binding to Vascular Endothelial Growth Factor Receptor-2 (VEGFR-2). Angiogenesis stimulation through PI3K-Akt-eNOS will cause endothelial cell to migrate, proliferate and differentiate. Molecular signal will be commenced by Phosphatidylinositol 3 kinase from serine/threonine kinase Akt/protein kinase B. Akt/PKB through the phosphorylation of endothelial Nitric Oxide synthase on Ser 1177 will stimulate NO production, vasodilatation, and endothelial cell migration.^{15,16} This result presents that *Channa micropeltes* extract ointment at 20% concentration increase the highest expression of VEGF when compared to *Channa striata* extract ointment at 10% concentration or control on day 8. This exhibits the potential of *Channa micropeltes* extract ointment at 20% concentration to promote angiogenesis on diabetes mellitus wound healing process.

Previous study by Carabelly (2019) reveals that the application of *Channa micropeltes* extract ointment at 20% concentration may elevate macrophage number on Day 8 and reduce them on Day 14.¹ Macrophage regulate angiogenesis signal in neovascular along the formation of granulation tissue process.¹⁷ This concept is in accordance with this study as the number of

macrophage was observed the highest on Day 8 and followed by the increase of neovascular cell number by the application of *Channa micropeltes* extract ointment at 20% concentration on Day 8. The highest number of neovascular cell was also observed in the application of *Channa micropeltes* extract ointment at 20% concentration when compared to *Channa striata* extract ointment at 10% concentration or control in Day 8. **This study did not continue to further day to limit the parameters.**

Comment [Ma2]: You have to mention the Limitations of the study.

It can be concluded that the application of *Channa micropeltes* extract ointment at 20% concentration on the wound of diabetic rat model can reduce the expression of NFkB. Anti-inflammatory effect of *Channa micropeltes* can elevate the expression of VEGF and the number of neovascular cells in angiogenesis process of diabetic wound healing. **This study requires further research using different parameters, adding time of evaluation, and using larger experimental animals.**

Comment [Ma3]: The conclusion should not be generalised, you mention only your findings and recommendation for further studies to explore more significant findings in different subjects and larger number.

Acknowledgements

The authors thank to Faculty of Dentistry, University of Lambung Mangkurat which have supported this work.

Funding Information

This study was financed by Faculty of Dentistry, University of Lambung Mangkurat which have supported this work.

Conflicts of Interest statement

The authors of the work have no conflict of interest.

References

1. Carabelly A.N, Firdaus I.W.A.K, Nurmardina P.C, Putri D.A, Apriasari M.L. The Effect of Topical Toman Fish (*Channa micropeltes*) Extract on Macrophages and Lymphocytes in Diabetes Mellitus Wound Healing. The 1st International Seminar on Smart Molecule of Natural Resources. Journal of Physics : Conference Series, 2019 : p. 1-9

2. Apriasari M.L, Ainah Y, Febrianty E, Carabelly A.N. Antioxidant Effect of Channa Micropeltes in Diabetic Wound of Oral Mucosa. *International Journal of Pharmacology*, 2019 ; 15 (1) : 137-143
3. Apriasari M.L, Puspitasari D. Effect of Channa micropeltes for increasing Lymphocyte and Fibroblast Cells in diabetic Wound Healing. *Journal of Medical Sciences*, 2018 ; 18 (4) : 205-210
4. Apriasari M.L, Syahadati M.A, Carabelly A.N. Clinical Analysis of Channa Micropeltes For Treating Wound of Diabetes Mellitus. *Berkala Kedokteran*, 2020 ; 16 (1) : 1-10
5. Brancato S.K, Albina J.E. Mini Review : Wound Macrophages as Key Regulators of Repair Origin, Phenotype, and Function. *The American Journal of Pathology*, 2011 ; 178 (1) : 19-25
6. Koh T.J, DiPietro L.A. Inflammation and Wound Healing : The role of the macrophage. *Expert Rev Mol Med*; 13 (e23) : 1-14
7. Kulkarni Y.A, Suryavanshi S.V. NFkB : Apotential Target in the Management of Vascular Complications of Diabetes. *Frontiers in Pharmacology*, 2017 ; 8 : 1-12
8. Baker R.G, Hayden M.S, Ghosh S. NFkB, inflammation and metabolic disease. *Cell Metab*, 2011 Januar 5 ; 13 (1) : 11-22
9. Mittal M, Siddiqui M.R, Tran K, Reddy S.P, Malik A.B. Reactive Oxygen Species in Inflammation and Tissue Injury. *Antioxidants and Redox Signaling*, 2014 ; 20 (7) : 1-108
10. Carabelly A.N, Utami J.P, Aspriyanto D, Reksi M.H, Puspitasari D, Rachmadi P. Effect of Channa Micropeltes in The Granulation, Fibrosis and Necrosis of Diabetic Wound Healing. *Dentino*, 2021 : 6 (2) : 1-10
11. Apriasari M.L, Pramitha S.R, Puspitasari D, Ernawati D.S. Anti-Inflammatory Effect of Musa acuminata Stem. *European Journal of Dentistry*, 2020 ; 14 (2) : 294-298
12. Tan W.S, Arulselvan P, Shio-Fern Ng, Taib C.N.M, Sarian M.N, Fakurazi S. Improvement of diabetic wound healing by topical application of Vicenin-2 hydrocolloid film on Sprague Dawley rats. *BMC Complementary and Alternative Medicine*, 2019 ; 19 (20) : 1-16
13. Okonkwo U, DiPietro L.A. Diabetes and Wound Angiogenesis. *International Journal of Molecular Sciences*, 2017 ; 18 (1419) : 1-15

14. Zhang J, Guan M, Xie C, Luo X,Zhang Q, Xue Y. Increased Growth Factors Play a Role in Wound Healing Promoted by Noninvasive Oxygen-Ozone Therapy in Diabetic Patients with Foot Ulcers. Hindawi Publishing Corporation *Oxidative Medicine and Cellular Longevity*, 2014, Article ID 273475 : 1-8.
15. Ammineni S, Kamili C, Chidrawar V.R, Rao U.M. A Review on Angiogenesis and Its Preventive Pathways. *International Journal of Universal Pharmacy and Bio Sciences*, 2014 ; 3 (6) : 50-54.
16. Majewska I, Darmach E.G. Proangiogenic activity of plant extracts in accelerating wound healing : a new face of old phytomedicines. *Acta Biochimica Polonica* ,2011 ; 58 (4) : 449-460.
17. Puspitasari D, Apriasari M.L. Analysis of traumatic ulcer healing time under the treatment of the Mauli banana (*Musa acuminata*) 25% stem extract gel. *Padjadjaran Journal of Dentistry*, 2017 ; 29 (1) : 21-25

**The Review of Diabetic Studies
INVOICE**

The Review of Diabetic Studies	Invoice Number: RDS-7-2 Invoice Date: 13/07/2022 Due Date: Upon Receipt		
BILL TO	Name: Maharani Laillyza Apriasari E-mail: maharaniroxy@gmail.com Indonesia		
Title:	Anti-Inflammatory Effect of Channa micropeltes Extract in Angiogenesis of Diabetes Wound Healing		
Amount	Invoice Number	Description	Amount (USD)
	RDS-7-2	Article Processing Charges and Wire Transfer Charges	USD 1000.00 +60 USD
		Total	USD 1060.00
Bank Details	WIRE TRANSFER INSTRUCTIONS a. Beneficiary Bank: Citibank India b. SWIFT Code: CITIINBX c. Beneficiary a/c no: 0124544556 d. Beneficiary a/c name: JCF Corporate Consulting Services Beneficiary Address: JCF Corporate Consulting Services 110 A, Westend Mall, Rd No 36, Jubilee Hills, Hyderabad, Telangana. 500033. <i>*Please reference the invoice number in your wire</i>		



maharani roxy <maharaniroxy@gmail.com>

Manuscript Accepted for Publication with Minor Revision - RDS-2022-7-2

6 pesan

maharani roxy <maharaniroxy@gmail.com>
Kepada: Rohan JCF Corp <rohan@jcfcorp.com>

14 Juli 2022 05.37

Dear Rohan Reddy RDS,

Thank you for the invoice. Before i pay it, i want to ask you some questions. First, when my manuscript will be published? Second, what the next step after i paid it? Thanks before.

Best regards,

Dr Maharani Laillyza Apriasari

Rohan JCF Corp <rohan@jcfcorp.com>
Kepada: maharani roxy <maharaniroxy@gmail.com>

14 Juli 2022 11.28

Dear Dr. Maharani,

Thank you for your email.

Your article will be published in the September 2022 issue.

After receiving the payment receipt from you, we will process your article through english editing, copy editing and galley proof stages.

We request you to kindly make the payment at the earliest.

Regards,
Rohan Reddy
RDS

[Kutipan teks disembunyikan]

maharani roxy <maharaniroxy@gmail.com>
Kepada: Rohan JCF Corp <rohan@jcfcorp.com>

14 Juli 2022 21.03

Dear Rohan Reddy RDS,

Thank you for the information. Tomorrow i will pay it by bank transfer, so please wait it.

Best regards,
Dr. Maharani Laillyza Apriasari

[Kutipan teks disembunyikan]

Rohan JCF Corp <rohan@jcfcorp.com>
Kepada: maharani roxy <maharaniroxy@gmail.com>

14 Juli 2022 21.28

Dear Dr. Maharani,

Thank you for the update.

Regards,
Rohan Reddy
RDS

[Kutipan teks disembunyikan]

maharani roxy <maharaniroxy@gmail.com>
Kepada: Rohan JCF Corp <rohan@jcfcorp.com>

15 Juli 2022 11.35

Dear Rohan RDS,

To day i have paid the invoice. Here i send you the proof of payment. Please, tell me if you get it. Thank you.

Best regards,

Dr Maharani

[Kutipan teks disembunyikan]



20220715_112942.jpg
3059K

Rohan JCF Corp <rohan@jcfcorp.com>
Kepada: maharani roxy <maharaniroxy@gmail.com>

15 Juli 2022 13.39

Dear Dr. Maharani,

Thank you for processing the payment and sending us the receipt.

We will forward it to our finance department, and we will let you know the further update.

Regards,
Rohan Reddy
RDS

[Kutipan teks disembunyikan]



maharani roxy <maharaniroxy@gmail.com>

RDS-2022-7-2 Accept manuscript

1 pesan

Review of Diabetic Studies <rds@manuscriptmanager.net>

16 Juli 2022 10.20

Balas Ke: Rohan Reddy <rohan@jfcfcorp.com>

Kepada: maharaniroxy@gmail.com

Manuscript: RDS-2022-7-2 - Anti Inflammatory Effect of Channa micropeltes Extract
in Angiogenesis of Diabetes Wound Healing

Date submitted: 2022-07-08

Dear Dr. Apriasari

We are pleased to inform you that your manuscript Anti Inflammatory Effect of Channa micropeltes Extract
in Angiogenesis of Diabetes Wound Healing
has been accepted for publication and passed on to our Production Editing Department. You will hear from a production editor in
due course.

We hope you will continue to submit work from your group to the Review of Diabetic Studies in the future and thank you for your
valuable contribution .

Sincerely,

Rohan Reddy
Administrator
rohan@jfcfcorp.com
Review of Diabetic Studies

YOUR SIGN IN INFORMATIONWebsite: <https://www.manuscriptmanager.net/rds>Email: maharaniroxy@gmail.com

Forgot password or not signed in before?

Click the URL below to create/reset your password.

[https://www.manuscriptmanager.net/sLib/v4/retrieve_pw.php?paramScreen=5m8kYjyCM/
78EJ5hi599BOWpnkI8qxgMnKSCuA0Z3Ok=](https://www.manuscriptmanager.net/sLib/v4/retrieve_pw.php?paramScreen=5m8kYjyCM/78EJ5hi599BOWpnkI8qxgMnKSCuA0Z3Ok=)



maharani roxy <maharaniroxy@gmail.com>

English Editing of Your Article - RDS-2022-7-2

1 pesan

Rohan JCF Corp <rohan@jcfcorp.com>
Kepada: maharani roxy <maharaniroxy@gmail.com>

20 Juli 2022 11.28

Dear Dr. Maharani,

Greetings.

Please find the attached English editing corrections of your article. We request you to kindly make the changes as per the suggestions and we request you to submit the article within 6 to 7 business days.

Awaiting your reply.

Regards,
Rohan Reddy
RDS

On Fri, Jul 15, 2022 at 11:09 AM Rohan JCF Corp <rohan@jcfcorp.com> wrote:

Dear Dr. Maharani,

Thank you for processing the payment and sending us the receipt.

We will forward it to our finance department, and we will let you know the further update.

Regards,
Rohan Reddy
RDS

On Fri, Jul 15, 2022 at 9:05 AM maharani roxy <maharaniroxy@gmail.com> wrote:

Dear Rohan RDS,

To day i have paid the invoice. Here i send you the proof of payment. Please, tell me if you get it. Thank you.

Best regards,

Dr Maharani

Pada tanggal Kam, 14 Jul 2022 21.28, Rohan JCF Corp <rohan@jcfcorp.com> menulis:

Dear Dr. Maharani,

Thank you for the update.

Regards,
Rohan Reddy
RDS

On Thu, Jul 14, 2022 at 6:33 PM maharani roxy <maharaniroxy@gmail.com> wrote:

Dear Rohan Reddy RDS,

Thank you for the information. Tomorrow i will pay it by bank transfer, so please wait it.

Best regards,
Dr. Maharani Laillyza Apriasari

Pada tanggal Kam, 14 Jul 2022 11.28, Rohan JCF Corp <rohan@jcfcorp.com> menulis:

Dear Dr. Maharani,

Thank you for your email.

Your article will be published in the September 2022 issue.

After receiving the payment receipt from you, we will process your article through english editing, copy editing and galley proof stages.

We request you to kindly make the payment at the earliest.

Regards,
Rohan Reddy
RDS

On Thu, Jul 14, 2022 at 3:07 AM maharani roxy <maharaniroxy@gmail.com> wrote:

Dear Rohan Reddy RDS,

Thank you for the invoice. Before i pay it, i want to ask you some questions. First, when my manuscript will be published? Second, what the next step after i paid it? Thanks before.

Best regards,

Dr Maharani Laillyza Apriasari



RDS-22-7-2 English Edited.docx

804K

Anti Inflammatory Effect of *Channa micropeltes* Extract in Angiogenesis of Diabetes Mellitus Wound Healing

Maharani Laillyza Apriasari¹, Dewi Puspitasari², Juliyatin Putri Utami³

¹Department of Oral Medicine, Faculty of Dentistry, Universitas Lambung Mangkurat, Banjarmasin, Kalimantan Selatan, Indonesia

²Department of Dental Material, Faculty of Dentistry, Universitas Lambung Mangkurat, Banjarmasin, Kalimantan Selatan, Indonesia

²Department of Biomedicine, Faculty of Dentistry, Universitas Lambung Mangkurat, Banjarmasin, Kalimantan Selatan, Indonesia

Address correspondence to : Maharani Laillyza Apriasari, Departement of Oral Medicine, Faculty of Dentistry, Universitas Lambung Mangkurat ; jl. Veteran 128B, Banjarmasin, Kalimantan Selatan, Indonesia, email : maharaniroxy@gmail.com

Article Title

Authors

Affiliations

Address correspondence to: Xxxxxx.Yyyyyy, email: xxxxxx@yyyyyy.country

Abstract

OBJECTIVE ~~Background:~~ *Channa micropeltes* extract contains albumin and ω -6 which possess anti-oxidant and anti-inflammatory agents that can promote macrophages in the wound healing process associated with diabetes mellitus (DM). ~~In this study, we~~ **Objective:** to analyzed Nuclear Factor kappa B (NFkB) and Vascular Endothelial Growth Factor (VEGF) expression as well as neovascular cells in the inflammatory stage of DM wound healing. ~~METHODS~~ **aterials and methods:** The ~~24~~ **Materials and methods:** The ~~twenty four~~ males *Rattus novergicus* were divided into ~~3~~ **three** groups that were 20% *Channa micropeltes* ointment (Group I), 10% *Channa striata* extract ointment (Group II), and placebo ointment as ~~a~~ **control** (Group III). Ointments were applied ~~3~~ **three** times daily. ~~RESULTS~~ **Results:** The highest expression of NFkB was observed in Group III on ~~Day~~ **Day** 4 (15.50 \pm 2.38), ~~and while~~ the lowest was in treatment of Group I and Group II on ~~day~~ **Day** 8 (4.75 \pm 0.96). The highest expression of VEGF was observed in Group I on ~~day~~ **Day** 8 (14.75 \pm 0.96),

Formatted: Superscript

Formatted: Centered

Formatted: Centered

Formatted: Adjust space between Latin and Asian text, Adjust space between Asian text and numbers

Formatted: Line spacing: single

Formatted: Left, Line spacing: single

Formatted: Font: Italic

and while the lowest was Group III on day-Day 4 (7.00 ± 1.41). The highest count of neovascular cells was observed in Group I on day-Day 8 (11.00 ± 2.16), and while the lowest was in Group III on day-Day 4 (5.50 ± 0.58).

-CONCLUSION Conclusion: *Channa micropeltes* has an anti-inflammatory effect by regulating NFkB expression and elevating VEGF expression in the angiogenesis process of DM wound healing.

Keywords: *Channa micropeltes*; NFkB; VEGF; neovascular; wound healing; diabetes mellitus

1. INTRODUCTION

Indonesia is ranked sixth among the countries with a high prevalence of diabetes mellitus (DM) in the world. In an uncontrolled state, DM will result in various oral problems such as xerostomia, candidiasis, stomatitis, gingivitis and periodontitis. The healing of such conditions is often complicated due to hyperglycemia that initiates chronic inflammation [1-3]. Previous study revealed that *Channa micropeltes* ointment at 20% concentration or *Channa striata* ointment at 10% concentration that was applied topically can accelerate wound healing in a DM rat model. Both species are categorized in the same genus and contain albumin as well as omega-6 that acts as an anti-oxidant and anti-inflammatory [3,4]. As an antioxidant, *Channa micropeltes* extract elevates superoxide dismutase (SOD) activity and lowers malondialdehyde (MDA) level on day-Day 7 [2]. As an anti-inflammatory, the topical application of *Channa micropeltes* at 20% concentration on the back skin of a diabetic rat model can increase the number of macrophage and lymphocyte cells on day-Day 8 and gradually reduce it on day-Day 14 [1].

Macrophage is the key of inflammatory process in wound healing. Reduction in macrophage number at the end of inflammatory stage demonstrates tissue recovery by producing

Formatted: Font: Bold

Formatted: Font: Not Italic

Formatted: Superscript

Formatted: Font: Not Italic

Formatted: Font: Not Italic

Formatted: Font: Not Italic

Formatted: Superscript

Formatted: Font: Not Italic

Formatted: Font: Not Italic

Formatted: Superscript

Formatted: Font: Not Italic

Formatted: Superscript

Formatted: Font: Not Italic

Formatted: Superscript

Formatted: Font: Not Italic

Formatted: Left

Formatted: Font: (Default) Times New Roman, 12 pt, Bold

Formatted: List Paragraph, Left, Indent: Left: 0", Line spacing: Double, Numbered + Level: 1 + Numbering Style: 1, 2, 3, ... + Start at: 1 + Alignment: Left + Aligned at: 0.25" + Indent at: 0.5"

Formatted: Font: (Default) Times New Roman, 12 pt, Bold

Formatted: Left, Indent: First line: 0.25", Line spacing: Double

Formatted: Indent: First line: 0.25"

Formatted: Left, Line spacing: Double

growth factors and, cytokines, and inducing as well as terminating angiogenesis [5,6].^{5,6} Macrophage is also produced Nuclear Factor kappa B (NFkB) that regulates the inflammatory response of metabolic disease such as DMdiabetes mellitus. A state of hHyperglycemia state in DMdiabetes mellitus will increase rReactive oOxygen sSpecies (ROS) and aAdvanced gGlycation eEnd pProducts (AGEs) that elevate chronic inflammation through the activation of NFkB. This will change vVascular eEndothelial gGrowth fFactor (VEGF) expression that will generate the damage to of blood vessels cell in the angiogenesis process [7,8].^{7,8}

The extract of *Channa micropeltes* has shownbeen proven to promote wound healing on the skin of diabetic rat model by reducing macrophage number at the end of inflammatory stage [3].³ There has been no study that explores the effect of *Channa micropeltes* application on NFkB, VEGF, and neovascular cells that are pivotal components in the DMdiabetes mellitus wound healing process. Based on that, a study to analyze the expression of NFkB, VEGF and neovascular cells number at the inflammatory stage of the DMdiabetes mellitus wound healing process was warrantedshould be conducted.

2. METHODSaterials and Methods

This study was an experimental laboratory research study incorporating a post-test only control group design. It was approved by Ethical Clearance Committee, Faculty of Dentistry, Universitas Lambung Mangkurat, Banjarmasin, South Kalimantan, Indonesia, with number 111/KEPKG-FKGULM/EC/III/2020.

2.1 Manufacturing Channa micropeltes and Channa striata extract

Formatted: Left, Line spacing: Double

Formatted: Font: (Default) Times New Roman, 12 pt, Bold

Formatted: Font: (Default) Times New Roman, 12 pt, Bold

Formatted: List Paragraph, Left, Indent: Left: 0", Line spacing: Double, Numbered + Level: 1 + Numbering Style: 1, 2, 3, ... + Start at: 1 + Alignment: Left + Aligned at: 0.25" + Indent at: 0.5"

Formatted: Left, Line spacing: Double

Formatted: Font: Not Bold, Italic

Formatted: Font: Not Bold

Formatted: Font: Not Bold, Italic

Formatted: Font: Not Bold

Formatted: Font: Not Bold, Italic

Preparing both *Channa micropeltes* and *Channa striata* extract used fresh fish weighing 600-1000 grams. Each extract was later steamed in a pan for 25-35 minutes at a temperature of under 60° Celsius. The flesh was enclosed with flannelette and pressed in a hydraulic device. Furthermore, *Channa micropeltes* and *Channa striata* were centrifuged for 15 minutes at a speed of within 6000 rpm. Each extract was kept inside a dark glass bottle and then covered with aluminum foil and clean pack.

Formatted: Left, Indent: First line: 0.5", Line spacing: Double

2.2 Formulation of *Channa micropeltes* and *Channa striata* ointment

Adeps lanae (Asian chemicals, Semarang) in a weight of 16.875 grams and vaselin flavum (PT. Brataco, 1295578) in a weight of 23.125 grams were used in the formulation of the *Channa micropeltes* ointment. Meanwhile, a combination of 16.875 grams adeps lanae and 28.125 grams vaselin flavum were combined in the formulation of *Channa striata* ointment. Adeps lanae was initially poured into different tubes for each extract and later added gradually with either *Channa micropeltes* at 20% concentration or *Channa striata* at 10% concentration. After the extract was fully absorbed by adeps lanae, the mixture was then mashed to obtain a homogenous consistency. Subsequently, the composition was further mixed with vaselin flavum and mashed again until homogenous.

Formatted: Left, Line spacing: Double

Formatted: Font: Not Bold, Italic

Formatted: Font: Not Bold

Formatted: Font: Not Bold, Italic

Formatted: Font: Not Bold

Formatted: Font: Not Bold, Italic

Formatted: Left, Indent: First line: 0.5", Line spacing: Double

2.3 In vivo Study

This study included 2-3 months-old male Wistar (*Rattus norvegicus*) rats (weight, 250-300 grams) obtained from an animal laboratory at the Faculty of Medicine, University of Lambung Mangkurat. The total of 24 rat specimens were kept in cages, and the temperature and humidity were set within ± 25 °C and 60%, respectively. They were fed standard BR-II, and they

Formatted: Left, Line spacing: Double

Formatted: Font: Not Bold, Italic

had access to boiled water *ad libitum*. Rats with hyperglycemia were obtained by injecting Streptozotocin (STZ) at 35 mg/kg dosage until the blood glucose level was over 126 mg/dL-1, while non-diabetic rats were ones is rats without intervention. All animals were divided into 3 treatment groups consisting of 20% *Channa micropeltes* extract ointment, 10% *Channa striata* extract ointment, and placebo ointment as control. Each substance was applied topically three times daily (every 6-8 hours). An incisional wound was made on the back of the rats with 1 cm length and 1 mm depth using sterile scalpel under inhaled anesthesia of 5 ml diethyl ether.

Formatted: Font: Italic

After the 4th and 8th day of application, rats were euthanized by inhaling a lethal dosage of diethyl ether. The back skin was then biopsied for histopathology examination using Haematoxylin-eosin (HE) to evaluate macrophages and neovascular cells, and Immunohistochemistry (IHC) to evaluate NF- κ B and VEGF. The number of macrophages and neovascular cells were calculated in three different field locations using a light microscope that were counted using light microscope (Olympus, WA-United States) at 400 magnifications and subsequently calculated for its average. Immunohistochemistry (IHC) staining was performed using anti-mouse NF- κ B monoclonal antibody (Santa Cruz Biotechnology Inc, Santa Cruz, CA, -NF- κ B p65 (F-6)-: sc 8008) and anti-mouse VEGF monoclonal antibody (Santa Cruz Biotechnology Inc, Santa Cruz, CA,- VEGF (C1) : sc 7269). Positivity NF- κ B expression was defined as only distinct nuclear immunostaining, which is considered as activated NF- κ B in the studied field at 100 magnification.

2.4 Data Statistical Analysis

Formatted: Font: Not Bold, Italic

The results were analyzed using a two-way analysis of variance parametric test based on the Shapiro-Wilk normality test and Levene's variance homogeneity test. The results showed

Formatted: Font: Not Bold, Italic

normal data distribution and homogenous data variances. Consequently, further analysis by means of a ~~post hoc~~*Post Hoc* Bonferroni test was conducted with a statistical significance of $p < 0.05$.

Formatted: Font: Italic

3. RESULTS

Formatted: Font: (Default) Times New Roman, 12 pt, Bold

Formatted: Font: (Default) Times New Roman, 12 pt, Bold

Formatted: List Paragraph, Left, Indent: Left: 0", Line spacing: Double, Numbered + Level: 1 + Numbering Style: 1, 2, 3, ... + Start at: 1 + Alignment: Left + Aligned at: 0.25" + Indent at: 0.5"

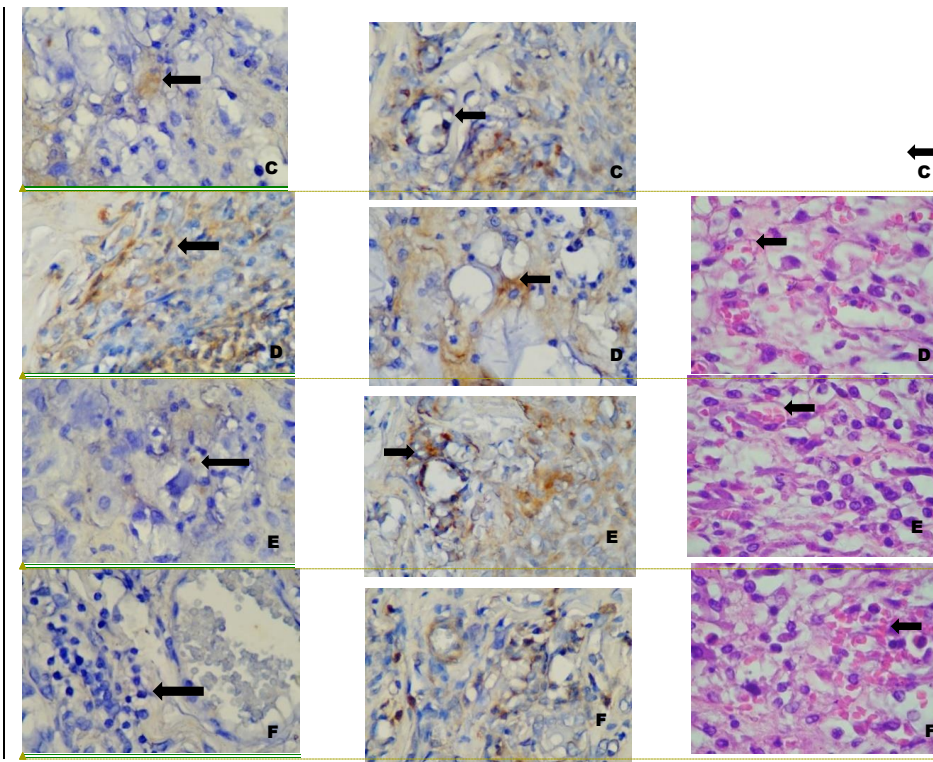
Formatted: Left, Indent: First line: 0", Line spacing: Double

Table 1 shows the results of NFkB analysis. The highest expression of NFkB was observed in the control group (Group III) on ~~day~~*Day* 4 (15.5 ± 2.38), and while the lowest was in the treatment of 20% *Channa micropeltes* extract ointment (Group I) (4.75 ± 0.96) and 10% *Channa striata* extract ointment (Group II) (5.75 ± 1.71) on ~~day~~*Day* 8. The expression of NFkB between Group I and 10% *Channa striata* extract ointment (Group II) treatment groups did not show any difference ($p > 0.05$; Table 1). The statistical significance value between treatment group and day ~~was~~*ere* $p > 0.05$, ~~that demonstrates~~*representings* no interaction between treatment groups and days on NFkB expression.

The highest expression of VEGF was observed in Group I (14.75 ± 0.96) on ~~day~~*Day* 8, where as the lowest was in Group III (7.00 ± 1.41) on ~~day~~*Day* 4. The expression of VEGF showed statistically significant differences in all groups ($p < 0.05$; Table 1). The significance value between treatment groups and days ~~was~~*ere* $p > 0.05$, ~~that demonstrating~~*represents* no interaction between treatment group and day on VEGF expression.

Formatted: Left, Line spacing: Double

The highest count of neovascular cells was observed in Group I (11.00 ± 2.16) on ~~day~~*Day* 8, while the lowest was in Group III (5.50 ± 0.58) on ~~day~~*Day* 4. The count of neovascular cells showed statistically significant differences in all groups ($p < 0.05$; Table 1). The statistical significance value between treatment groups and days ~~was~~*ere* $p > 0.05$, ~~demonstrating that~~*represents* no interaction between treatment groups and days on the number of neovascular cells.



Formatted: Font: (Default) Calibri
Formatted: Font: (Default) Times New Roman, 12 pt, Bold

Formatted: Font: (Default) Calibri
Formatted: Font: (Default) Times New Roman, 12 pt

Formatted: Font: (Default) Calibri
Formatted: Font: (Default) Times New Roman, 12 pt

Formatted: Font: (Default) Calibri
Formatted: Font: (Default) Times New Roman, 12 pt

Note.

Macrophage's expression of NFκB on control group (A), Channa micropeltes extract concentrations of 20% (B), Channa striata extract concentrations of 10% (C) on Day 4. Macrophage's expression of NFκB on control group (D), Channa micropeltes extract concentrations of 20% (E), Channa striata extract concentrations of 10% (F) on Day 8. 2. Neovascular's expression of VEGF on control group (A), Channa micropeltes extract concentrations of 20% (B), Channa striata extract concentrations of 10% (C) on Day 4. Neovascular's expression of VEGF on control group (D), Channa micropeltes extract concentrations of 20% (E), Channa striata extract concentrations of 10% (F) on Day 8. 3. Neovascular cell's count on control group (A), Channa micropeltes extract concentrations of 20% (B), Channa striata extract concentrations of 10% (C) on Day 4. Neovascular cell's count on control group (D), Channa micropeltes extract concentrations of 20% (E), Channa striata extract concentrations of 10% (F) on Day 8.

4. DISCUSSION

DM is characterized with an increase in blood glucose level that induces glycation reaction. This process will result in amadori production to formulate toxic proteins called Advanced Glication End Products (AGEs). Interaction between AGEs and a receptor aAdvanced gGlycication eEnd pProduct (RAGE) will increase the signal for nicotinamide adenine dinucleotide phosphate (NADPH) oxidase which produces superoxide anion. This process

Formatted: Font: (Default) Times New Roman, 12 pt, Bold

Formatted: List Paragraph, Left, Indent: Left: 0", Line spacing: Double, Numbered + Level: 1 + Numbering Style: 1, 2, 3, ... + Start at: 1 + Alignment: Left + Aligned at: 0.25" + Indent at: 0.5"

Formatted: Font: (Default) Times New Roman, 12 pt, Bold

Formatted: Left, Indent: First line: 0", Line spacing: Double

elevates the production of ~~r~~Reactive ~~o~~Oxygen ~~s~~Species (ROS) which are the key for molecular signaling as well as the development of inflammatory disorders such as ~~DM~~diabetes mellitus. Excessive production of ROS will complicate the healing process of wounds in ~~DM [2,9]~~diabetes mellitus.²⁻⁹

Channa micropeltes contains albumin and omega-6 fatty acid. Albumin can decrease ROS by cutting chained oxidative reaction in the ROS formation's process. Albumin can bind metal ions and also catch oxygen that processing hydrogen peroxide into non radical compound. Omega-6 fatty acid, especially arachnoidic acid are the keys ~~to~~of anti-inflammatory ~~processes~~. It plays the role in stimulating macrophages to release growth factors, such as VEGF. Arachidonic acid will be metabolized through an enzymatic mechanism such as the 5-lipoxygenase and cyclo-oxygenase pathways that produce leukotrienes, prostaglandins, and thromboxane A2. These can stimulates ~~the~~ cell migration and new local vascularization in ~~the~~ wound healing process of ~~DM [4,10]~~diabetes mellitus.⁴⁻¹⁰

In previous studies, *Channa micropeltes* extract ointment at 20% concentration and *Channa striata* extract ointment at 10% concentration were ~~shown~~proven to promote ~~the~~ wound healing process in ~~DM~~diabetes mellitus. *Channa micropeltes* and *Channa striata* are categorized in ~~the~~ same genus. Both species contain albumin, the secondary antioxidant that can bind metal ion in ROS formation [1,2].¹⁻² ROS induces ~~an~~ inflammatory response through the activation of Nuclear Factor kappa B (NFkB). NFkB signal is the main key of chronic inflammation in ~~DM [7,8]~~diabetes mellitus.⁷⁻⁸ This is ~~demonstrated~~proven by ~~the~~is study result on ~~Day~~Day 4 that

Formatted: Left, Line spacing: Double

Formatted: Left, Line spacing: Double

reveals the highest expression of NFkB in control group, while the result for 20% *Channa micropeltes* extract application was comparable to 10% *Channa striata* extract application.

Our study result on day 8 demonstrates the reduction of NFkB expression in both *Channa micropeltes* extract ointment at 20% concentration and *Channa striata* extract ointment at 10% concentration when compared to the control. Topical application of *Channa micropeltes* extract at 20% concentration or *Channa striata* extract at 10% concentration may reduce excessive ROS, thereby suppressing NFkB expression. Both extracts possess potential as natural substances that may inhibit the expression of NFkB. Previous studies reveal that the impediment of pro-inflammatory NFkB from therapeutic application of several natural and synthetic ingredients will be a good target to manage vascular complication in DM [7] diabetes mellitus.⁷ A prolonged inflammatory response can be resolved by the inhibition of NFkB. As an anti-inflammatory substance, *Channa micropeltes* will reduce inducible Nitric Oxide Synthase (iNOS) and Cyclooxygenase 2 (COX2) that suppress the NFkB gene regulator. This will prevent prolonged inflammation in the wound healing process of DM [11,12] diabetes mellitus.^{11,12}

Excessive activation of NFkB will cause abnormal DNA transcription which includes various gene expression of vascular complications occurring in VEGF, Platelet Derived Growth Factor (PDGF), Endothelin-1 (ET-1) and Transforming Growth Factor beta (TGF-b) that cause vascular cell damage [7]. VEGF as pro-angiogenic modulators encounter down regulation in DM diabetes mellitus, thus disturbing the angiogenesis process [13,14].^{13,14} Prior studies demonstrate Vascular Endothelial Growth Factor A (VEGF-A) protein and messenger Ribonucleic Acid (mRNA) level in the wound of a diabetic rat model which shows reduction

Formatted: Font: 12 pt

Formatted: Font: (Default) Times New Roman, 12 pt

Formatted: Not Superscript/ Subscript

when compared to the group with a normal wound. DM diabetes mellitus leads to the decrease of angiogenesis in wound healing, so that it lessens vascular and capillary density [13].⁴³

The angiogenic effect is initiated by VEGF-A binding to Vascular Endothelial Growth Factor Receptor-2 (VEGFR-2). Angiogenesis stimulation through PI3K-Akt-eNOS will cause endothelial cell to migrate, proliferate, and differentiate. Molecular signals will be commenced by Phosphatidylinositol 3 kinase from serine/threonine kinase Akt/protein kinase B. Akt/PKB through the phosphorylation of endothelial Nitric Oxide synthesis on Ser 1177, and will stimulate NO production, vasodilatation, and endothelial cell migration [15,16].^{45,46} This result presents that *Channa micropeltes* extract ointment at 20% concentration increases the highest expression of VEGF when compared to *Channa striata* extract ointment at 10% concentration or the control on day Day 8. This exhibits the potential of *Channa micropeltes* extract ointment at 20% concentration to promote angiogenesis on the DM diabetes mellitus wound healing process.

Previous study by Carabelly et al. [11] (2019) reveals that the application of *Channa micropeltes* extract ointment at 20% concentration may elevate macrophage number on Day 8 and reduce them on Day 14.⁴ Macrophage regulates angiogenesis signals in neovascular along the formation of granulation tissue process [17].⁴⁷ This concept is in accordance with this study as the number of macrophage was observed the highest on Day 8 and followed by the increase of neovascular cell number by the application of *Channa micropeltes* extract ointment at 20% concentration on Day 8. The highest number of neovascular cells was also observed in the application of *Channa micropeltes* extract ointment at 20% concentration when compared to *Channa striata* extract ointment at 10% concentration or the control in Day 8. This study did not continue to further days to limit the parameters.

Formatted: Left, Line spacing: Double

Formatted: Not Highlight

~~We can~~ ~~It can be~~ concluded that the application of *Channa micropeltes* extract ointment at 20% concentration on the wound of a diabetic rat model can reduce the expression of NFκB. The aAnti-inflammatory effect of *Channa micropeltes* can elevate the expression of VEGF and the number of neovascular cells in angiogenesis process of diabetic wound healing. Our findings requires This study requi_res further research using different parameters, adding time of evaluation, and using larger experimental animals.

Acknowledgements:

~~The authors thank to Faculty of Dentistry, University of Lambung Mangkurat which have supported this work.~~

Funding Information

This study was financed by the Faculty of Dentistry, University of Lambung Mangkurat, which have supported this work. The authors express their gratitude,

Conflicts of Interest statement:

~~The authors of the work~~ have no conflict of interest to report.

Ethical approval: Approval for this study was provided by the Ethical Clearance Committee, Faculty of Dentistry, Universitas Lambung Mangkurat, Banjarmasin, South Kalimantan, Indonesia (#111/KEPKG-FKGULM/EC/III/2020).

Formatted: Left, Line spacing: Double, Tab stops: Not at 0.64" + 1.27" + 1.91" + 2.54" + 3.18" + 3.82" + 4.45" + 5.09" + 5.73" + 6.36" + 7" + 7.63" + 8.27" + 8.91" + 9.54" + 10.18"

Formatted: Left, Line spacing: Double

Formatted: Left, Line spacing: Double, Tab stops: Not at 0.64" + 1.27" + 1.91" + 2.54" + 3.18" + 3.82" + 4.45" + 5.09" + 5.73" + 6.36" + 7" + 7.63" + 8.27" + 8.91" + 9.54" + 10.18"

Formatted: English (U.S.)

Formatted: Left, Line spacing: Double

Formatted: English (U.S.)

Formatted: Font: Bold

Formatted: Left, Line spacing: Double, Tab stops: Not at 0.64" + 1.27" + 1.91" + 2.54" + 3.18" + 3.82" + 4.45" + 5.09" + 5.73" + 6.36" + 7" + 7.63" + 8.27" + 8.91" + 9.54" + 10.18"

References

1. **Carabelly A.N, Firdaus I.W.A.K, Nurmardina P.C, Putri D.A, Apriasari M.L.** The Effect of Topical Toman Fish (*Channa micropeltes*) Extract on Macrophages and Lymphocytes in Diabetes Mellitus Wound Healing. The 1st International Seminar on Smart Molecule of Natural Resources. *Journal of Physics : Conference Series*, 2019 : p. 1-9
2. **Apriasari M.L, Ainah Y, Febrianty E, Carabelly A.N.** Antioxidant Effect of *Channa Micropeltes* in Diabetic Wound of Oral Mucosa. *International Journal of Pharmacology*, 2019, 15 (1) : 137-143
3. **Apriasari M.L, Puspitasari D.** Effect of *Channa micropeltes* for increasing Lymphocyte and Fibroblast Cells in diabetic Wound Healing. *Journal of Medical Sciences*, 2018, 18 (4) : 205-210
4. **Apriasari M.L, Syhadati M.A, Carabelly A.N.** Clinical Analysis of *Channa Micropeltes* For Treating Wound of Diabetes Mellitus. *Berkala Kedokteran*, 2020, 16 (1) : 1-10
5. **Brancato S.K, Albina J.E.** Mini Review : Wound Macrophages as Key Regulators of Repair Origin, Phenotype, and Function. *The American Journal of Pathology*, 2011, 178 (1) : 19-25
6. **Koh T.J, DiPietro L.A.** Inflammation and Wound Healing : The role of the macrophage. *Expert Rev Mol Med*, 13 (e23) : 1-14
7. **Kulkarni Y.A, Suryavanshi S.V.** NFkB : Apotential Target in the Management of Vascular Complications of Diabetes. *Frontiers in Pharmacology*, 2017, 8 : 1-12
8. **Baker R.G, Hayden M.S, Ghosh S.** NFkB, inflammation and metabolic disease. *Cell Metab*, 2011, Januar 5 ; 13 (1) : 11-22
9. **Mittal M, Siddiqui M.R, Tran K, Reddy S.P, Malik A.B.** Reactive Oxygen Species in Inflammation and Tissue Injury. *Antioxidants and Redox Signaling*, 2014, 20 (7) : 1-108

Formatted: Left

Formatted: Not Highlight

Formatted: Highlight

Formatted: Font: Bold

Formatted: Left

Formatted: Font: Italic

Formatted: Font: Bold

Formatted: Font: Italic

Formatted: Font: Bold

Formatted: Font: Italic

Formatted: Font: Bold

Formatted: Font: Italic

Formatted: Font: Bold

Formatted: Font: Italic

Formatted: Font: Bold

Formatted: Font: Italic

Formatted: Font: Bold

Formatted: Font: Italic

Formatted: Font: Bold

Formatted: Font: Italic

Formatted: Font: Bold

Formatted: Left

Formatted: Font: Italic

10. **Carabelly A.N, Utami J.P, Aspriyanto D, Reksi M.H, Puspitasari D, Rachmadi P.** Effect of Channa Micropeltes in The Granulation, Fibrosis and Necrosis of Diabetic Wound Healing. *Dentino*. 2021. 6 (2) : 1-10
11. **Apriasari M.L, Pramitha S.R, Puspitasari D, Ernawati D.S.** Anti-Inflammatory Effect of Musa acuminata Stem. *European Journal of Dentistry*. 2020. 14 (2) : 294-298
12. **Tan W.S, Arulselvan P, Shio-Fern Ng, Taib C.N.M, Sarian M.N, Fakurazi S.** Improvement of diabetic wound healing by topical application of Vicenin-2 hydrocolloid film on Sprague Dawley rats. *BMC Complementary and Alternative Medicine*. 2019. 19 (20) : 1-16
13. **Okonkwo U, DiPietro L.A.** Diabetes and Wound Angiogenesis. *International Journal of Molecular Sciences*. 2017. 18 (1419) : 1-15
14. **Zhang J, Guan M, Xie C, Luo X, Zhang Q, Xue Y.** Increased Growth Factors Play a Role in Wound Healing Promoted by Noninvasive Oxygen-Ozone Therapy in Diabetic Patients with Foot Ulcers. *Hindawi Publishing Corporation Oxidative Medicine and Cellular Longevity*. 2014. Article ID 273475 : 1-8.
15. **Ammineni S, Kamili C, Chidrawar V.R, Rao U.M.** A Review on Angiogenesis and Its Preventive Pathways. *International Journal of Universal Pharmacy and Bio Sciences*. 2014. 3 (6) : 50-54.
16. **Majewska I, Darmach E.G.** Proangiogenic activity of plant extracts in accelerating wound healing : a new face of old phytomedicines. *Acta Biochimica Polonica*. 2011. 58 (4) : 449-460.
17. **Puspitasari D, Apriasari M.L.** Analysis of traumatic ulcer healing time under the treatment of the Mauli banana (Musa acuminata) 25% stem extract gel. *Padjadjaran Journal of Dentistry*. 2017. 29 (1) : 21-25

Formatted: Font: Bold

Formatted: Font: Italic

Formatted: Font: Bold

Formatted: Font: Italic

Formatted: Font: Bold

Formatted: Font: Italic

Formatted: Font: Bold

Formatted: Font: Italic

Formatted: Font: Bold

Formatted: Font: Italic

Formatted: Font: Bold

Formatted: Font: Bold

Formatted: Font: Bold

Formatted: Font: Italic

Table 1. The expression of NFkB, expression of VEGF and count of neovascular cells

Group	Mean ± SD (cells)					
	Expression of NFkB		Expression of VEGF		Count of Neovascular	
	Day 4	Day 8	Day 4	Day 8	Day 4	Day 8
<u>Channa micropeltes (Group I)</u>	7.00 ± 1.41 ^A	4.75 ± 0.96 ^A	11.75 ± 1.71 ^C	14.75 ± 0.96 ^E	7.75 ± 0.96 ^E	11.00 ± 2.16 ^E
<u>Channa striata (Group II)</u>	7.75 ± 1.26 ^A	5.75 ± 1.71 ^A	10.50 ± 1.20 ^B	12.50 ± 1.20 ^B	6.25 ± 0.96 ^B	9.00 ± 0.81 ^B
<u>Control (Group III)</u>	15.50 ± 2.28 ^B	10.00 ± 2.58 ^B	7.00 ± 1.41 ^A	9.75 ± 0.96 ^A	5.50 ± 0.58 ^A	6.25 ± 0.96 ^A

Note:

Abbreviations: The different superscript character in each variable shows the differences for each group (p < .05).

A in Expression of NFkB has value p = .044

B in Expression of NFkB has value p = .000

A, B and C in Expression of VEGF has value p = .000

A, B and C in Count of Neovascular has value p = .000

Formatted: Left

Formatted: Font: Bold

Formatted: Left

Formatted: Left

Formatted: Left

Formatted: Left

Formatted: Left

Formatted: Left

Formatted: Left

Formatted: Left

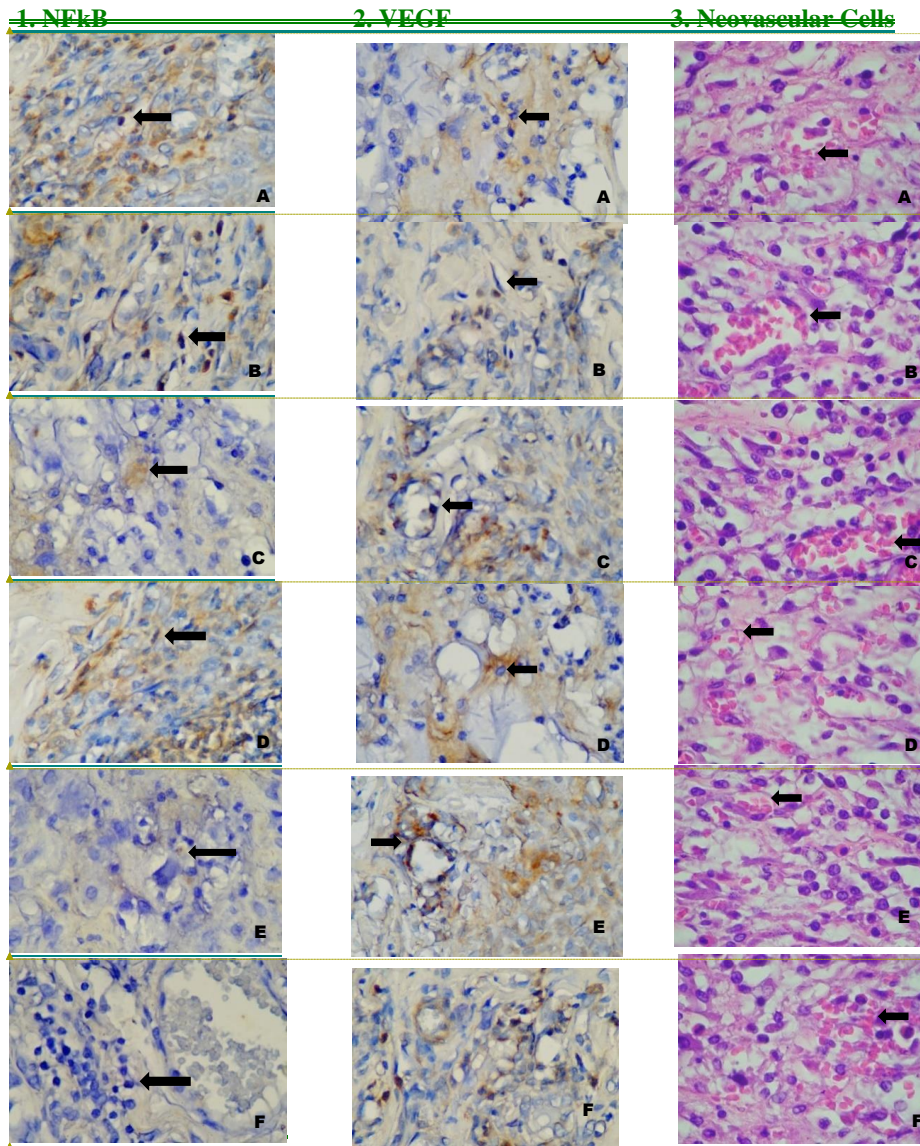
Formatted: Font: 8 pt

Formatted: Line spacing: single

Formatted: Left, Line spacing: single

Formatted: Line spacing: single

Figure 1. Macrophage expression of NFkB on the control group, Neovascular's expression of VEGF on the control group, and Neovascular cell's count on the control group



Note:

Macrophage's expression of NFkB on control group (A), *Channa micropeltes* extract concentrations of 20% (B), *Channa striata* extract concentrations of 10% (C) on Day 4. Macrophage's expression of NFkB on control group (D), *Channa micropeltes* extract concentrations of 20% (E), *Channa striata* extract concentrations of 10% (F) on Day 8. 2. Neovascular's expression of VEGF on control group (A), *Channa micropeltes* extract concentrations of 20% (B), *Channa striata* extract concentrations of 10% (C) on Day 4. Neovascular's expression of VEGF

Formatted: Left, Line spacing: single

Formatted: Font: Bold

Formatted: Left, Line spacing: single

Formatted: Font: (Default) Calibri

Formatted: Font: (Default) Calibri

Formatted: Font: (Default) Times New Roman, 12 pt, Bold

Formatted: Font: (Default) Calibri

Formatted: Font: (Default) Times New Roman, 12 pt, Bold

Formatted: Font: (Default) Calibri

Formatted: Font: (Default) Times New Roman, 12 pt, Bold

Formatted: Font: (Default) Calibri

Formatted: Font: (Default) Times New Roman, 12 pt

Formatted: Font: (Default) Calibri

Formatted: Font: (Default) Times New Roman, 12 pt

Formatted: Font: (Default) Calibri

Formatted: Font: (Default) Times New Roman, 12 pt

Formatted: Left

Formatted: Font: 8 pt

Formatted: Left

Formatted: Font: 8 pt

Formatted: Font: 8 pt

Formatted: Font: 8 pt

Formatted: Font: 8 pt

on control group (D), *Chama micropeltes* extract concentrations of 20% (E), *Chama striata* extract concentrations of 10% (F) on Day 8. 3. Neovascular cell's count on control group (A), *Chama micropeltes* extract concentrations of 20% (B), *Chama striata* extract concentrations of 10% (C) on Day 4. Neovascular cell's count on control group (D), *Chama micropeltes* extract concentrations of 20% (E), *Chama striata* extract concentrations of 10% (F) on Day 8.

Formatted: Font: 8 pt

Formatted: Font: 8 pt

Formatted: Font: 8 pt

Formatted: Left, Space After: 8 pt, Line spacing: Multiple 1.08 li



maharani roxy <maharaniroxy@gmail.com>

RDS-22-7-2 English Edited

4 pesan

maharani roxy <maharaniroxy@gmail.com>
Kepada: Rohan JCF Corp <rohan@jcfcorp.com>

21 Juli 2022 19.09

Dear Rohan,

Thank you for the response. Here i send my manuscript that have been revised.

Regards,

Dr. Maharani

 **RDS-22-7-2 English Edited.docx**
847K

Rohan JCF Corp <rohan@jcfcorp.com>
Kepada: maharani roxy <maharaniroxy@gmail.com>

22 Juli 2022 10.47

Dear Dr. Maharani,

Thank you for sending us the updated file.

Within 10 business days, you will receive the copyediting of your article.

Regards,
Rohan Reddy
RDS

[Kutipan teks disembunyikan]

maharani roxy <maharaniroxy@gmail.com>
Kepada: Rohan JCF Corp <rohan@jcfcorp.com>

29 Juli 2022 10.48

Dear Rohan,

Thanks for the response. I am waiting it.

Regards,

Maharani L.A

[Kutipan teks disembunyikan]

Rohan JCF Corp <rohan@jcfcorp.com>
Kepada: maharani roxy <maharaniroxy@gmail.com>

30 Juli 2022 10.50

Dear Dr. Maharani,

Greetings.

We are lacking two submissions for the upcoming issue. We would be grateful if you could submit your other research article (if any) by August 12 2022, or we request you to kindly suggest our Journal to your friends/colleagues to submit their article .

Awaiting your reply.

Regards,
Rohan Reddy
RDS

[Kutipan teks disembunyikan]

Article Title

Authors

Affiliations

Address correspondence to: XXXXXX.YYYYYY, email: xxxxxx@yyyyyy.country

Abstract

OBJECTIVE ~~Background:~~ *Channa micropeltes* extract contains albumin and ω -6 which possess anti-oxidant and anti-inflammatory agents that can promote macrophages in the wound healing process associated with diabetes mellitus (DM). In this study, we analyzed Nuclear Factor kappa B (NFkB) and Vascular Endothelial Growth Factor (VEGF) expression as well as neovascular cells in the inflammatory stage of DM wound healing.

METHODS ~~aterials and methods:~~ The ~~24~~ ²⁰ ~~four~~ ^{four} males *Rattus novergicus* were divided into ~~3~~ ³ groups that were 20% *Channa micropeltes* ointment (Group I), 10% *Channa striata* extract ointment (Group II), and placebo ointment as a control (Group III). Ointments were applied ~~3~~ ³ times daily.

RESULTS ~~Results:~~ The highest expression of NFkB was observed in Group III on ~~Day~~ ^{Day} 4 (15.50 ± 2.38), ~~and while~~ the lowest was in treatment of Group I and Group II on ~~day~~ ^{Day} 8 (4.75 ± 0.96). The highest expression of VEGF was observed in Group I on ~~day~~ ^{Day} 8 (14.75 ± 0.96), ~~and while~~ the lowest was Group III on ~~day~~ ^{Day} 4 (7.00 ± 1.41). The highest count of neovascular cells was observed in Group I on ~~day~~ ^{Day} 8 (11.00 ± 2.16), ~~and while~~ the lowest was in Group III on ~~day~~ ^{Day} 4 (5.50 ± 0.58).

CONCLUSIONS ~~Conclusion:~~ *Channa micropeltes* has ~~ve~~ ^{an} anti-inflammatory effect by regulating NFkB expression and elevating VEGF expression in the angiogenesis process of DM wound healing.

Keywords: *Channa micropeltes*; NFkB; VEGF; neovascular; wound healing; diabetes mellitus

1. INTRODUCTION

Indonesia is ranked sixth among the countries with a high prevalence of Diabetes mellitus

(DM) in the world. In an uncontrolled state, DM will result in various

of oral problems such as xerostomia, candidiasis, stomatitis, gingivitis and periodontitis. The

healing of such conditions is often complicated due to hyperglycemia that initiates chronic

Formatted: Adjust space between Latin and Asian text, Adjust space between Asian text and numbers

Formatted: Line spacing: single

Formatted: Left, Line spacing: single

Formatted: Font: Italic

Formatted: Font: Bold

Formatted: Font: Not Italic

Formatted: Superscript

Formatted: Font: Not Italic

Formatted: Font: Not Italic

Formatted: Font: Not Italic

Formatted: Superscript

Formatted: Font: Not Italic

Formatted: Font: Not Italic

Formatted: Superscript

Formatted: Font: Not Italic

Formatted: Superscript

Formatted: Font: Not Italic

Formatted: Superscript

Formatted: Font: Not Italic

Formatted: Left

Formatted: Font: (Default) Times New Roman, 12 pt, Bold

Formatted: List Paragraph, Left, Indent: Left: 0", Line spacing: Double, Numbered + Level: 1 + Numbering Style: 1, 2, 3, ... + Start at: 1 + Alignment: Left + Aligned at: 0.25" + Indent at: 0.5"

Formatted: Font: (Default) Times New Roman, 12 pt, Bold

Formatted: Left, Indent: First line: 0", Line spacing: Double

inflammation [1-3].^{1,2,3} Previous study revealed that *Channa micropeltes* ointment at 20% concentration or *Channa striata* ointment at 10% concentration that was applied topically can accelerate wound healing in a DM diabetes mellitus rat model. Both species are categorized in the same genus and contain albumin as well as omega-6 that acts as an anti-oxidant and anti-inflammatory [3,4].^{3,4} As an antioxidant, *Channa micropeltes* extract elevates superoxide dismutase (SOD) activity and lowers malondialdehyde (MDA) level on day Day 7 [2].² As an anti-inflammatory, the topical application of *Channa micropeltes* at 20% concentration on the back skin of a diabetic rat model cannot increase the number of macrophage and lymphocyte cells on day Day 8 and gradually reduce it on day Day 14 [1].¹

Macrophage is the key of inflammatory process in wound healing. Reduction in macrophage number at the end of inflammatory stage demonstrates tissue recovery by producing growth factors and cytokines, and inducing as well as terminating angiogenesis [5,6].^{5,6} Macrophage is also produced Nuclear Factor kappa B (NFkB) that regulates the inflammatory response of metabolic disease such as DM diabetes mellitus. A state of hyperglycemia state in DM diabetes mellitus will increase reactive oxygen species (ROS) and advanced glycation end products (AGEs) that elevate chronic inflammation through the activation of NFkB. This will change vascular endothelial growth factor (VEGF) expression that will generate the damage to blood vessels in the angiogenesis process [7,8].^{7,8}

The extract of *Channa micropeltes* has shown been proven to promote wound healing on the skin of diabetic rat model by reducing macrophage number at the end of inflammatory stage [3].³ There has been no study that explores the effect of *Channa micropeltes* application on

Formatted: Left, Line spacing: Double

Formatted: Left, Line spacing: Double

NFkB, VEGF, and neovascular cells that are pivotal components in ~~the DMdiabetes mellitus~~ wound healing process. Based on that, a study to analyze the expression of NFkB, VEGF and neovascular cells number at the inflammatory stage of ~~the DMdiabetes mellitus~~ wound healing process ~~was warranted~~~~should be conducted~~.

2. METHODS~~aterials and Methods~~

This study was an experimental laboratory research ~~study~~ incorporating ~~a~~ post-test only control group design. It was approved by Ethical Clearance Committee, Faculty of Dentistry, Universitas Lambung Mangkurat, Banjarmasin, South Kalimantan, Indonesia, with number 111/KEPKG-FKGULM/EC/III/2020.

2.1 Manufacturing *Channa micropeltes* and *Channa striata* extract

Preparing both *Channa micropeltes* and *Channa striata* extract used fresh fish weighing ~~600-1000 grams~~. Each ~~extract of it~~ was later steamed in a pan for 25-35 minutes ~~at a temperature of under 60° Celsius~~~~temperature~~. The flesh ~~was~~~~ere~~ enclosed with flannelette and pressed in ~~a~~ hydraulic device. ~~Further~~~~more~~, *Channa micropeltes* and *Channa striata* were centrifuged for 15 minutes ~~at a speed of within 6000 rpm~~~~speed~~. Each extract was kept inside ~~a~~ dark glass bottle and then covered with aluminum foil and clean pack.

2.2 Formulation of *Channa micropeltes* and *Channa striata* ointment

Adeps lanae (Asian chemicals, Semarang) in a weight of 16.875 ~~grams~~ and vaselin flavum (PT. Brataco, 1295578) in a weight of 23.125 ~~grams~~ were used in the formulation of ~~the~~ *Channa micropeltes* ointment. Meanwhile, a combination of 16.875 ~~grams~~ adeps lanae and

Formatted: Font: (Default) Times New Roman, 12 pt, Bold

Formatted: Font: (Default) Times New Roman, 12 pt, Bold

Formatted: List Paragraph, Left, Indent: Left: 0", Line spacing: Double, Numbered + Level: 1 + Numbering Style: 1, 2, 3, ... + Start at: 1 + Alignment: Left + Aligned at: 0.25" + Indent at: 0.5"

Formatted: Left, Line spacing: Double

Formatted: Font: Not Bold, Italic

Formatted: Font: Not Bold

Formatted: Font: Not Bold, Italic

Formatted: Font: Not Bold

Formatted: Font: Not Bold, Italic

Formatted: Left, Indent: First line: 0.5", Line spacing: Double

Formatted: Left, Line spacing: Double

Formatted: Font: Not Bold, Italic

Formatted: Font: Not Bold

Formatted: Font: Not Bold, Italic

Formatted: Font: Not Bold

Formatted: Font: Not Bold, Italic

Formatted: Left, Indent: First line: 0.5", Line spacing: Double

28.125 grams vaselin flavum were ~~combined+utilized~~ in the formulation of *Channa striata* ointment. Adeps lanae was initially poured into different tubes for each extract and later added gradually with either *Channa micropeltes* at 20% concentration or *Channa striata* at 10% concentration. After the extract was fully absorbed by adeps lanae, the mixture was then mashed to obtain a homogenous consistency. Subsequently, the composition was further mixed with vaselin flavum and mashed again until homogenous.

2.3 In vivo Study

This study included 2-3 months-old male Wistar (*Rattus norvegicus*) rats (weight, 250–300 grams) obtained from an animal laboratory at the Faculty of Medicine, University of Lambung Mangkurat. The total of 24 rat specimens were kept in cages, and the temperature and humidity were set within ± 25 °C and 60%, respectively. They were fed standard BR-II, and they had access to boiled water *ad libitum*. Rats with hyperglycemia were obtained by injecting Streptozotocin (STZ) at 35 mg/kg dosage until the blood glucose level was over 126 mg/dL-1; while non-diabetic rats were ones is rats without intervention. All animals were divided into 3 treatment groups consisting of 20% *Channa micropeltes* extract ointment, 10% *Channa striata* extract ointment, and placebo ointment as control. Each substance was applied topically three times daily (every 6-8 hours). An incisional wound was made on the back of the rats with 1 cm length and 1 mm depth using sterile scalpel under inhaled anesthesia of 5 ml diethyl ether.

After the 4th and 8th day of application, rats were euthanized by inhaling a lethal dosage of diethyl ether. The back skin was then biopsied for histopathology examination using Haematoxylin-Eosin (HE) to evaluate macrophages and neovascular cells, and Immunohistochemistry (IHC) to evaluate NF- κ B and VEGF. The number of macrophages and

Formatted: Left, Line spacing: Double

Formatted: Font: Not Bold, Italic

Formatted: Font: Italic

neovascular cells were calculated in ~~3~~ three different field locations using a light microscope ~~that were counted using light microscope~~ (Olympus, ~~WA United States~~) at 400 magnifications and subsequently calculated for its average. ~~Immunohistochemistry (IHC)~~ staining was performed using anti-mouse NF-κB monoclonal antibody (Santa Cruz Biotechnology Inc, ~~Santa Cruz, CA,~~ -NF-κB p65 (F-6)_: sc 8008) and anti-mouse VEGF monoclonal antibody (Santa Cruz Biotechnology Inc, ~~Santa Cruz, CA,~~ VEGF (C1) : sc 7269). Positivity NF-κB expression was defined as only distinct nuclear immunostaining, which is considered as activated NF-κB in the studied field at 100 magnification.

2.4 ~~Data~~ Statistical Analysis

The results were analyzed using a ~~2~~ two-way analysis of variance parametric test based on ~~the~~ Shapiro-Wilk normality test and Levene's variance homogeneity test. The results showed normal data distribution and homogenous data variances. Consequently, further analysis by means of a ~~post hoc~~ ~~Post Hoc~~ Bonferroni test was conducted with a ~~statistical~~ significance of $p < 0.05$.

3. RESULTS ~~results~~

Table 1 shows ~~the~~ the results of NFκB analysis ~~were shown in table 1~~. The highest expression of NFκB was observed in the control group (Group III) on ~~day~~ Day 4 (15.5 ± 2.38), ~~and while~~ the lowest was in the treatment of 20% *Channa micropeltes* extract ointment (Group I) (4.75 ± 0.96) and 10% *Channa striata* extract ointment (Group II) (5.75 ± 1.71) on ~~day~~ Day 8. The expression of NFκB between Group I and- 10% *Channa striata* extract ointment (Group II) treatment groups did not show any difference ($p > 0.05$; Table 1). The ~~statistical~~ significance value between

Formatted: Font: Not Bold, Italic

Formatted: Font: Not Bold, Italic

Formatted: Font: Italic

Formatted: Font: (Default) Times New Roman, 12 pt, Bold

Formatted: List Paragraph, Left, Indent: Left: 0", Line spacing: Double, Numbered + Level: 1 + Numbering Style: 1, 2, 3, ... + Start at: 1 + Alignment: Left + Aligned at: 0.25" + Indent at: 0.5"

Formatted: Font: (Default) Times New Roman, 12 pt, Bold

Formatted: Left, Indent: First line: 0", Line spacing: Double

treatment group and day ~~were~~ $p > 0.05$, ~~that demonstrating~~ representing no interaction between treatment groups and days on NFkB expression.

The highest expression of VEGF was observed in Group I (14.75 ± 0.96) on ~~day~~ Day 8, where as the lowest was in Group III (7.00 ± 1.41) on ~~day~~ Day 4. The expression of VEGF showed statistically significant differences in all groups ($p < 0.05$; Table 1). The significance value between treatment groups and days ~~were~~ $p > 0.05$, ~~that demonstrating~~ represents no interaction between treatment group and day on VEGF expression.

The highest count of neovascular cells was observed in Group I (11.00 ± 2.16) on ~~day~~ Day 8, while the lowest was in Group III (5.50 ± 0.58) on ~~day~~ Day 4. The count of neovascular cells showed statistically significant differences in all groups ($p < 0.05$; Table 1). The statistical significance value between treatment groups and days ~~were~~ $p > 0.05$, ~~demonstrating that~~ represents no interaction between treatment groups and days on the number of neovascular cells.

[Table 1 about here](#)

[Figure 1 about here](#)

4. DISCUSSION~~iscussion~~

~~D~~Miabetes mellitus is characterized with an increase in blood glucose level that induces gly~~y~~ication reaction. This process will result in amatory production to formulate toxic proteins ~~s~~called Advanced Glication End Products-(AGEs). Interaction between AGEs and a ~~r~~Receptor ~~a~~Advanced ~~g~~Glycicatio~~n~~e ~~E~~nd ~~p~~Product (RAGE) will increase the signal for nicotinamide adenine dinucleotide phosphate (NADPH) oxidase which produces superoxide anion. This process

Formatted: Left, Line spacing: Double

Formatted: Font: Not Bold

Formatted: Font: Not Bold

Formatted: Font: (Default) Times New Roman, 12 pt, Bold

Formatted: List Paragraph, Left, Indent: Left: 0", Line spacing: Double, Numbered + Level: 1 + Numbering Style: 1, 2, 3, ... + Start at: 1 + Alignment: Left + Aligned at: 0.25" + Indent at: 0.5"

Formatted: Font: (Default) Times New Roman, 12 pt, Bold

Formatted: Left, Indent: First line: 0", Line spacing: Double

elevates the production of Reactive Oxygen Species (ROS) which are the key for molecular signaling as well as the development of inflammatory disorders such as DM~~diabetes mellitus~~. Excessive production of ROS will complicate the healing process of wounds in DM ~~[2,9]~~diabetes mellitus.²⁻⁹

Channa micropeltes contains albumin and omega-6 fatty acid. Albumin can decrease ROS by cutting chained oxidative reaction in the ROS formation's process. Albumin can bind metal ions and also catch oxygen that processing hydrogen peroxide into non radical compound. Omega-6 fatty acid, especially arachnoidic acid are the keys ~~to~~ anti-inflammatory processes. It plays the role in stimulating macrophages to release growth factors, such as VEGF. Arachnoidic acid will be metabolized through an enzymatic mechanism such as the 5-lipoxygenase and cyclo-oxygenase pathways that produce leukotrienes, prostaglandins, and thromboxane A2. These can stimulates ~~the~~ cell migration and new local vascularization in the wound healing process of DM ~~[4,10]~~diabetes mellitus.⁴⁻¹⁰

In previous studies, *Channa micropeltes* extract ointment at 20% concentration and *Channa striata* extract ointment at 10% concentration were ~~shown~~proven to promote the wound healing process in DM~~diabetes mellitus~~. *Channa micropeltes* and *Channa striata* are categorized in the same genus. Both species contain albumin, the secondary antioxidant that can bind metal ion in ROS formation [1,2].¹⁻² ROS induces an inflammatory response through the activation of Nuclear Factor kappa B (NFkB). NFkB signal is the main key of chronic inflammation in DM ~~[7,8]~~diabetes mellitus.⁷⁻⁸ This is ~~demonstrated~~proven by ~~the~~is study result on Day~~Day~~ 4 that

Formatted: Left, Line spacing: Double

Formatted: Left, Line spacing: Double

reveals the highest expression of NFkB in control group, while the result for 20% *Channa micropeltes* extract application was comparable to 10% *Channa striata* extract application.

Our study result on day 8 demonstrates the reduction of NFkB expression in both *Channa micropeltes* extract ointment at 20% concentration and *Channa striata* extract ointment at 10% concentration when compared to the control. Topical application of *Channa micropeltes* extract at 20% concentration or *Channa striata* extract at 10% concentration may reduce excessive ROS, thereby suppressing NFkB expression. Both extracts possess potential as natural substances that may inhibit the expression of NFkB. Previous studies reveal that the impediment of pro-inflammatory NFkB from therapeutic application of several natural and synthetic ingredients will be a good target to manage vascular complication in DM [7] diabetes mellitus.⁷ A prolonged inflammatory response can be resolved by the inhibition of NFkB. As an anti-inflammatory substance, *Channa micropeltes* will reduce inducible Nitric Oxide Synthase (iNOS) and Cyclooxygenase 2 (COX2) that suppress the NFkB gene regulator. This will prevent prolonged inflammation in the wound healing process of DM [11,12] diabetes mellitus.^{11,12}

Excessive activation of NFkB will cause abnormal DNA transcription which includes various gene expression of vascular complications occurring in VEGF, Platelet Derived Growth Factor (PDGF), Endothelin-1 (ET-1) and Transforming Growth Factor beta (TGF-b) that cause vascular cell damage [7]. VEGF as pro-angiogenic modulators encounter down regulation in DM diabetes mellitus, thus disturbing the angiogenesis process [13,14].^{13,14} Prior studies demonstrate Vascular Endothelial Growth Factor A (VEGF-A) protein and messenger Ribonucleic Acid (mRNA) level in the wound of a diabetic rat model which shows reduction

Formatted: Font: 12 pt

Formatted: Font: (Default) Times New Roman, 12 pt

Formatted: Not Superscript/ Subscript

when compared to the group with a normal wound. DM diabetes mellitus leads to the decrease of angiogenesis in wound healing, so that it lessens vascular and capillary density [13].⁴³

The angiogenic effect is initiated by VEGF-A binding to Vascular Endothelial Growth Factor Receptor-2 (VEGFR-2). Angiogenesis stimulation through PI3K-Akt-eNOS will cause endothelial cell to migrate, proliferate, and differentiate. Molecular signals will be commenced by Phosphatidylinositol 3 kinase from serine/threonine kinase Akt/protein kinase B. Akt/PKB through the phosphorylation of endothelial Nitric Oxide synthesis on Ser 1177, and will stimulate NO production, vasodilatation, and endothelial cell migration [15,16].^{45,46} This result presents that *Channa micropeltes* extract ointment at 20% concentration increases the highest expression of VEGF when compared to *Channa striata* extract ointment at 10% concentration or the control on Day 8. This exhibits the potential of *Channa micropeltes* extract ointment at 20% concentration to promote angiogenesis on the DM diabetes mellitus wound healing process.

Previous study by Carabelly et al. [11] (2019) reveals that the application of *Channa micropeltes* extract ointment at 20% concentration may elevate macrophage number on Day 8 and reduce them on Day 14.⁴ Macrophage regulates angiogenesis signals in neovascular along the formation of granulation tissue process [17].⁴⁷ This concept is in accordance with this study as the number of macrophage was observed the highest on Day 8 and followed by the increase of neovascular cell number by the application of *Channa micropeltes* extract ointment at 20% concentration on Day 8. The highest number of neovascular cells was also observed in the application of *Channa micropeltes* extract ointment at 20% concentration when compared to *Channa striata* extract ointment at 10% concentration or the control in Day 8. This study did not continue to further days to limit the parameters.

Formatted: Left, Line spacing: Double

Formatted: Not Highlight

~~We can~~ ~~It can be~~ concluded that the application of *Channa micropeltes* extract ointment at 20% concentration on the wound of a diabetic rat model can reduce the expression of NFκB. The ~~a~~Anti-inflammatory effect of *Channa micropeltes* can elevate the expression of VEGF and the number of neovascular cells in angiogenesis process of diabetic wound healing. Our findings ~~requires~~This study requires further research using different parameters, adding time of evaluation, and using larger experimental animals.

Acknowledgements:

~~The authors thank to Faculty of Dentistry, University of Lambung Mangkurat which have supported this work.~~

Funding Information

This study was financed by the Faculty of Dentistry, University of Lambung Mangkurat, ~~which~~ ~~have supported this work.~~ The authors express their gratitude,

Conflicts of Interest statement:

~~The authors~~ ~~of the work~~ have no conflict of interest to report.

Ethical approval: Approval for this study was provided by the Ethical Clearance Committee, Faculty of Dentistry, Universitas Lambung Mangkurat, Banjarmasin, South Kalimantan, Indonesia (#111/KEPKG-FKGULM/EC/III/2020).

Formatted: Left, Line spacing: Double, Tab stops: Not at 0.64" + 1.27" + 1.91" + 2.54" + 3.18" + 3.82" + 4.45" + 5.09" + 5.73" + 6.36" + 7" + 7.63" + 8.27" + 8.91" + 9.54" + 10.18"

Formatted: Left, Line spacing: Double

Formatted: Left, Line spacing: Double, Tab stops: Not at 0.64" + 1.27" + 1.91" + 2.54" + 3.18" + 3.82" + 4.45" + 5.09" + 5.73" + 6.36" + 7" + 7.63" + 8.27" + 8.91" + 9.54" + 10.18"

Formatted: English (U.S.)

Formatted: Left, Line spacing: Double

Formatted: English (U.S.)

Formatted: Font: Bold

Formatted: Left, Line spacing: Double, Tab stops: Not at 0.64" + 1.27" + 1.91" + 2.54" + 3.18" + 3.82" + 4.45" + 5.09" + 5.73" + 6.36" + 7" + 7.63" + 8.27" + 8.91" + 9.54" + 10.18"

References

1. Carabelly A.N, Firdaus I.W.A.K, Nurmardina P.C, Putri D.A, Apriasari M.L. The Effect of Topical Toman Fish (*Channa micropeltes*) Extract on Macrophages and Lymphocytes in Diabetes Mellitus Wound Healing. The 1st International Seminar on Smart Molecule of Natural Resources. Journal of Physics : Conference Series, 2019 : p. 1-9
2. Apriasari M.L, Ainah Y, Febrianty E, Carabelly A.N. Antioxidant Effect of *Channa Micropeltes* in Diabetic Wound of Oral Mucosa. International Journal of Pharmacology, 2019 ; 15 (1) : 137-143
3. Apriasari M.L, Puspitasari D. Effect of *Channa micropeltes* for increasing Lymphocyte and Fibroblast Cells in diabetic Wound Healing. Journal of Medical Sciences, 2018 ; 18 (4) : 205-210
4. Apriasari M.L, Syahadati M.A, Carabelly A.N. Clinical Analysis of *Channa Micropeltes* For Treating Wound of Diabetes Mellitus. Berkala Kedokteran, 2020 ; 16 (1) : 1-10
5. Brancato S.K, Albina J.E. Mini Review : Wound Macrophages as Key Regulators of Repair Origin, Phenotype, and Function. The American Journal of Pathology, 2011 ; 178 (1) : 19-25
6. Koh T.J, DiPietro L.A. Inflammation and Wound Healing : The role of the macrophage. Expert Rev Mol Med; 13 (e23) : 1-14
7. Kulkarni Y.A, Suryavanshi S.V. NFkB : Apotential Target in the Management of Vascular Complications of Diabetes. Frontiers in Pharmacology, 2017 ; 8 : 1-12
8. Baker R.G, Hayden M.S, Ghosh S. NFkB, inflammation and metabolic disease. Cell Metab, 2011 Januar 5 ; 13 (1) : 11-22
9. Mittal M, Siddiqui M.R, Tran K, Reddy S.P, Malik A.B. Reactive Oxygen Species in Inflammation and Tissue Injury. Antioxidants and Redox Signaling, 2014 ; 20 (7) : 1-108
10. Carabelly A.N, Utami J.P, Aspriyanto D, Reksi M.H, Puspitasari D, Rachmadi P. Effect of *Channa Micropeltes* in The Granulation, Fibrosis and Necrosis of Diabetic Wound Healing. Dentino, 2021 : 6 (2) : 1-10
11. Apriasari M.L, Pramitha S.R, Puspitasari D, Ernawati D.S. Anti-Inflammatory Effect of *Musa acuminata* Stem. European Journal of Dentistry, 2020 ; 14 (2) : 294-298

Formatted: Left

Formatted: Highlight

Formatted: Left

Formatted: Left

12. Tan W.S, Arulselvan P, Shio-Fern Ng, Taib C.N.M, Sarian M.N, Fakurazi S. Improvement of diabetic wound healing by topical application of Vicenin-2 hydrocolloid film on Sprague Dawley rats. *BMC Complementary and Alternative Medicine*, 2019 ; 19 (20) : 1-16
13. Okonkwo U, DiPietro L.A. Diabetes and Wound Angiogenesis. *International Journal of Molecular Sciences*, 2017 ; 18 (1419) : 1-15
14. Zhang J, Guan M, Xie C, Luo X,Zhang Q, Xue Y. Increased Growth Factors Play a Role in Wound Healing Promoted by Noninvasive Oxygen-Ozone Therapy in Diabetic Patients with Foot Ulcers. Hindawi Publishing Corporation *Oxidative Medicine and Cellular Longevity*, 2014, Article ID 273475 : 1-8.
15. Ammineni S, Kamili C, Chidrawar V.R, Rao U.M. A Review on Angiogenesis and Its Preventive Pathways. *International Journal of Universal Pharmacy and Bio Sciences*, 2014 ; 3 (6) : 50-54.
16. Majewska I, Darmach E.G. Proangiogenic activity of plant extracts in accelerating wound healing : a new face of old phytomedicines. *Acta Biochimica Polonica* ,2011 ; 58 (4) : 449-460.
17. Puspitasari D, Apriasari M.L. Analysis of traumatic ulcer healing time under the treatment of the Mauli banana (*Musa acuminata*) 25% stem extract gel. *Padjadjaran Journal of Dentistry*, 2017 ; 29 (1) : 21-25

Table 1. The expression of NFkB, expression of VEGF and count of neovascular cells

Group	Mean ± SD (cells)					
	Expression of NFkB		Expression of VEGF		Count of Neovascular	
	Day 4	Day 8	Day 4	Day 8	Day 4	Day 8
<u>Channa micropeltes (Group I)</u>	7.00 ± 1.41 ^A	4.75 ± 0.96 ^A	11.75 ± 1.71 ^C	14.75 ± 0.96 ^C	7.75 ± 0.96 ^C	11.00 ± 2.16 ^C
<u>Channa striata (Group II)</u>	7.75 ± 1.26 ^A	5.75 ± 1.71 ^A	10.50 ± 1.29 ^B	12.50 ± 1.29 ^B	6.25 ± 0.96 ^B	9.00 ± 0.816 ^B
<u>Control (Group III)</u>	15.50 ± 2.38 ^B	10.00 ± 2.58 ^B	7.00 ± 1.41 ^A	9.75 ± 0.96 ^A	5.50 ± 0.58 ^A	6.25 ± 0.96 ^A

Note.

Abbreviations: The different superscript character in each variable shows the differences for each group (p < .05).

A in Expression of NFkB has value p = .044

B in Expression of NFkB has value p = .000

A, B and C in Expression of VEGF has value p = .000

A, B and C in Count of Neovascular has value p = .000

Formatted: Left

Formatted: Font: Bold

Formatted: Left

Formatted: Left

Formatted: Left

Formatted: Left

Formatted: Left

Formatted: Left

Formatted: Left

Formatted: Left

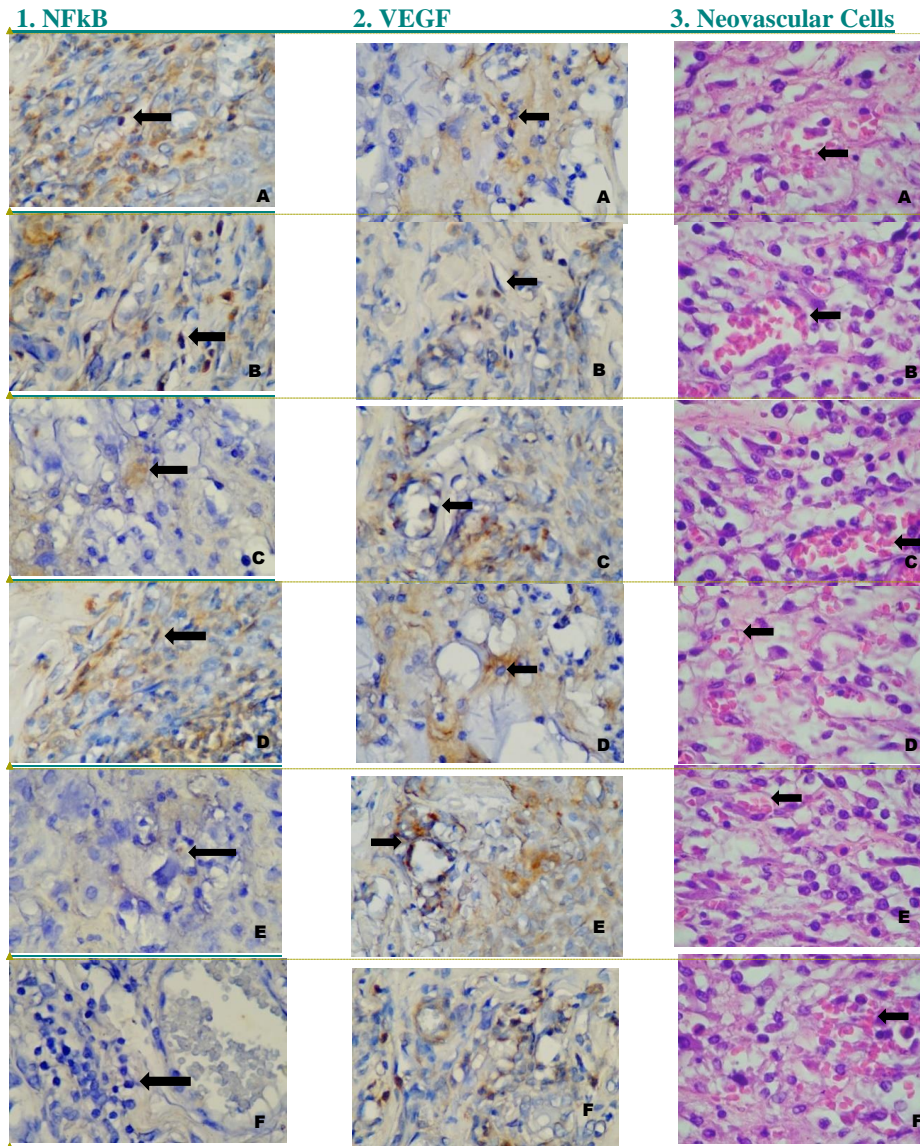
Formatted: Font: 8 pt

Formatted: Line spacing: single

Formatted: Left, Line spacing: single

Formatted: Line spacing: single

Figure 1. Macrophage expression of NFkB on the control group, Neovascular's expression of VEGF on the control group, and Neovascular cell's count on the control group



Note.

Macrophage's expression of NFkB on control group (A), *Channa micropeltes* extract concentrations of 20% (B), *Channa striata* extract concentrations of 10% (C) on Day 4, Macrophage's expression of NFkB on control group (D), *Channa micropeltes* extract concentrations of 20% (E), *Channa striata* extract concentrations of 10% (F) on Day 8. 2. Neovascular's expression of VEGF on control group (A), *Channa micropeltes* extract concentrations of 20% (B), *Channa striata* extract concentrations of 10% (C) on Day 4, Neovascular's expression of VEGF

Formatted: Left, Line spacing: single

Formatted: Font: Bold

Formatted: Font: (Default) Calibri

Formatted: Font: (Default) Calibri

Formatted: Font: (Default) Times New Roman, 12 pt, Bold

Formatted: Font: (Default) Calibri

Formatted: Font: (Default) Times New Roman, 12 pt, Bold

Formatted: Font: (Default) Calibri

Formatted: Font: (Default) Times New Roman, 12 pt, Bold

Formatted: Font: (Default) Calibri

Formatted: Font: (Default) Times New Roman, 12 pt

Formatted: Font: (Default) Calibri

Formatted: Font: (Default) Times New Roman, 12 pt

Formatted: Font: (Default) Calibri

Formatted: Font: (Default) Times New Roman, 12 pt

Formatted: Left

Formatted: Font: 8 pt

Formatted: Left

Formatted: Font: 8 pt

Formatted: Font: 8 pt

Formatted: Font: 8 pt

Formatted: Font: 8 pt

on control group (D), *Channa micropeltes* extract concentrations of 20% (E), *Channa striata* extract concentrations of 10% (F) on Day 8. 3. Neovascular cell's count on control group (A), *Channa micropeltes* extract concentrations of 20% (B), *Channa striata* extract concentrations of 10% (C) on Day 4. Neovascular cell's count on control group (D), *Channa micropeltes* extract concentrations of 20% (E), *Channa striata* extract concentrations of 10% (F) on Day 8.

Formatted: Font: 8 pt

Formatted: Font: 8 pt

Formatted: Font: 8 pt

Formatted: Left, Line spacing: single



maharani roxy <maharaniroxy@gmail.com>

Copy Editing of Your Article- RDS-22-7-2

6 pesan

Rohan JCF Corp <rohan@jcfcorp.com>
Kepada: maharani roxy <maharaniroxy@gmail.com>

1 Agustus 2022 10.26

Dear Dr. Maharani,

Greetings,

Please find the attached copy editing of your article.

Kindly highlight the changes (if any) in the word document and send us the updated file within 48hrs.

Also, please send us the short title of your article and list of abbreviations.

Awaiting your reply.

Regards,
Rohan Reddy
RDS

On Fri, Jul 29, 2022 at 8:18 AM maharani roxy <maharaniroxy@gmail.com> wrote:

Dear Rohan,

Thanks for the response. I am waiting it.

Regards,

Maharani L.A

Pada tanggal Jum, 22 Jul 2022 10.48, Rohan JCF Corp <rohan@jcfcorp.com> menulis:

Dear Dr. Maharani,

Thank you for sending us the updated file.

Within 10 business days, you will receive the copyediting of your article.

Regards,
Rohan Reddy
RDS

On Thu, Jul 21, 2022 at 4:39 PM maharani roxy <maharaniroxy@gmail.com> wrote:

Dear Rohan,

Thank you for the response. Here i send my manuscript that have been revised.

Regards,

Dr. Maharani

**RDS-22-7-2.zip**
1013K

maharani roxy <maharaniroxy@gmail.com>
Kepada: Rohan JCF Corp <rohan@jcfcorp.com>

2 Agustus 2022 15.39

Dear Rohan Reddy,


Thank you for the reponse. I have revised and changed any words in my manuscript, so i hope it more better than before.


Regards,
Dr. Maharani

[Kutipan teks disembunyikan]

3 lampiran

 **Figure edited.docx**
950K

 **Manuscript edited.docx**
28K

 **Titile page edited.docx**
24K

Rohan JCF Corp <rohan@jcfcorp.com>
Kepada: maharani roxy <maharaniroxy@gmail.com>

2 Agustus 2022 16.40

Dear Dr. Maharani,

Thank you for sending us the updated files.

Soon, you will receive the galley proof of your article.

Regards,
Rohan Reddy
RDS

[Kutipan teks disembunyikan]

Rohan JCF Corp <rohan@jcfcorp.com>
Kepada: maharani roxy <maharaniroxy@gmail.com>

3 Agustus 2022 12.01

Dear Dr. Maharani,

Could you please let us know the short title of your article.

Awaiting your reply.

Regards,
Rohan Reddy
RDS

[Kutipan teks disembunyikan]

maharani roxy <maharaniroxy@gmail.com>
Kepada: Rohan JCF Corp <rohan@jcfcorp.com>

4 Agustus 2022 08.50

Dear Rohan Reddy,

The manuscript short title is " In vivo Study of Diabetes Based on Histopathology"
Thank you

Regards,
Dr. Maharani

[Kutipan teks disembunyikan]

Rohan JCF Corp <rohan@jcfcorp.com>
Kepada: maharani roxy <maharaniroxy@gmail.com>

4 Agustus 2022 10.36

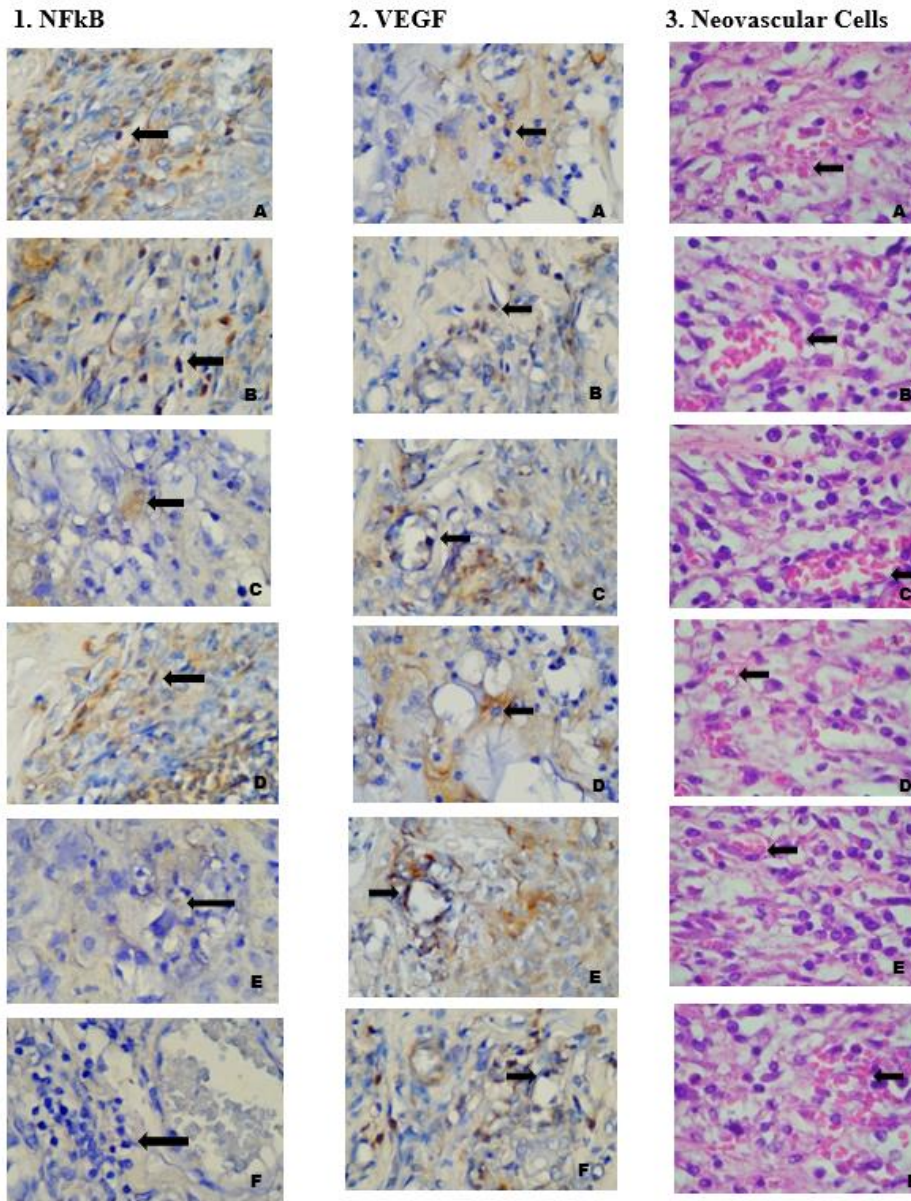
Dear Dr. Maharani,

Thank you for your kind response.

Regards,
Rohan Reddy
RDS

[Kutipan teks disembunyikan]

Figure 1. Macrophage expression of **NF-κB** on the control group, Neovascular's expression of VEGF on the control group, and Neovascular cell's count on the control group.



Note:

Macrophage's expression of **NF-κB** on control group (A), *Channa micropeltes* extract concentrations of 20% (B), *Channa striata* extract concentrations of 10% (C) on Day 4. Macrophage's expression of **NF-κB** on control group (D), *Channa micropeltes* extract concentrations of 20% (E), *Channa striata* extract concentrations of 10% (F) on Day 8. **2.** Neovascular's expression of VEGF on control group (A), *Channa micropeltes* extract concentrations of 20% (B), *Channa striata* extract concentrations of 10% (C) on Day 4. Neovascular's expression of VEGF on control group (D), *Channa micropeltes* extract concentrations of 20% (E), *Channa striata* extract concentrations of 10% (F) on Day 8. **3.** Neovascular cell's count on control group (A), *Channa micropeltes* extract concentrations of 20% (B), *Channa striata* extract concentrations of 10% (C) on Day 4. Neovascular cell's count

on control group (D), *Channa micropeltes* extract concentrations of 20% (E), *Channa striata* extract concentrations of 10% (F) on Day 8.

Anti-Inflammatory Effect of *Channa micropeltes* Extract in Angiogenesis of Diabetes Mellitus Wound Healing

Maharani Laillyza Apriasari¹, Dewi Puspitasari², Juliyatin Putri Utami³

¹Department of Oral Medicine, Faculty of Dentistry, Universitas Lambung Mangkurat, Banjarmasin, Kalimantan Selatan, Indonesia, ²Department of Dental Material, Faculty of Dentistry, Universitas Lambung Mangkurat, Banjarmasin, Kalimantan Selatan, Indonesia, ³Department of Biomedicine, Faculty of Dentistry, Universitas Lambung Mangkurat, Banjarmasin, Kalimantan Selatan, Indonesia. Address correspondence to: Maharani Laillyza Apriasari. email: maharaniroxy@gmail.com

Abstract:

OBJECTIVE: *Channa micropeltes* extract contains albumin and omega-6 which possess antioxidant and anti-inflammatory agents that can promote macrophages in the wound healing process associated with diabetes mellitus (DM). In this study, we analyzed Nuclear Factor kappa B (NF- κ B) and Vascular Endothelial Growth Factor (VEGF) expression as well as neovascular cells in the inflammatory stage of DM wound healing. **METHODS:** The 24 males *Rattus novergicus* were divided into 3 groups that were 20% *Channa micropeltes* ointment (Group I), 10% *Channa striata* extract ointment (Group II), and placebo ointment as a control (Group III). Ointments were applied 3 times daily. **RESULTS:** The highest expression of NF- κ B was observed in Group III on Day 4 (15.50 ± 2.38), and the lowest was in treatment of Group I and Group II on Day 8 (4.75 ± 0.96). The highest expression of VEGF was observed in Group I on Day 8 (14.75 ± 0.96), and the lowest was Group III on Day 4 (7.00 ± 1.41). The highest count of neovascular cells was observed in Group I on Day 8 (11.00 ± 2.16), and the lowest was in Group III on Day 4 (5.50 ± 0.58). **CONCLUSIONS:** *Channa micropeltes* has an anti-inflammatory effect by regulating NF- κ B expression and elevating VEGF expression in the angiogenesis process of DM wound healing.

Keywords: *channa micropeltes*, NF- κ B, VEGF, neovascular, wound healing, diabetes mellitus

List of abbreviations:

AGEs Advanced Glycation End products

COX2 cyclooxygenase 2

DM Diabetes mellitus

ET-1 Endothelin-1

HE Hematoxylin eosin

IHC immunohistochemistry

iNOS nitric oxide synthase
MDA malondialdehyd
mRNA messenger ribonucleic acid
NADPH nicotinamide adenine dinucleotide phosphate
NF- κ B Nuclear Factor Kappa Beta
PDGF Platelet Derived Growth Factor
RAGE receptor advanced glycation end product
ROS reactive oxygen species
SOD superoxide dismutase
STZ streptozotocin
VEGF Vascular Endothelial Growth Factor

Manuscript submitted: July 09, 2022

Resubmitted: August 01, 2022

Accepted: August 06, 2022



maharani roxy <maharaniroxy@gmail.com>

Galley Proof of Your Article- RDS-22-7-2

4 pesan

Rohan JCF Corp <rohan@jcfcorp.com>
Kepada: maharani roxy <maharaniroxy@gmail.com>

5 Agustus 2022 10.38

Dear Dr. Maharani,

Please find the attached galley proof of your article.

Kindly let us know if any modifications/changes are needed.

Awaiting your reply.

Regards,
Rohan Reddy
RDS

On Thu, Aug 4, 2022 at 8:06 AM Rohan JCF Corp <rohan@jcfcorp.com> wrote:

Dear Dr. Maharani,

Thank you for your kind response.

Regards,
Rohan Reddy
RDS

On Thu, Aug 4, 2022 at 6:20 AM maharani roxy <maharaniroxy@gmail.com> wrote:

Dear Rohan Reddy,

The manuscript short title is " In vivo Study of Diabetes Based on Histopathology"
Thank youRegards,
Dr. Maharani

Pada tanggal Rab, 3 Agu 2022 12.01, Rohan JCF Corp <rohan@jcfcorp.com> menulis:

Dear Dr. Maharani,

Could you please let us know the short title of your article.

Awaiting your reply.

Regards,
Rohan Reddy
RDS

On Tue, Aug 2, 2022 at 1:09 PM maharani roxy <maharaniroxy@gmail.com> wrote:

Dear Rohan Reddy,

Thank you for the reponse. I have revised and changed any words in my manuscript, so i hope it more better than before.

Regards,
Dr. Maharani

Pada tanggal Sen, 1 Agu 2022 pukul 10.26 Rohan JCF Corp <rohan@jcfcorp.com> menulis:

Dear Dr. Maharani,

Greetings,

Please find the attached copy editing of your article.

Kindly highlight the changes (if any) in the word document and send us the updated file within 48hrs.

Also, please send us the short title of your article and list of abbreviations.

Awaiting your reply.

Regards,
Rohan Reddy
RDS

On Fri, Jul 29, 2022 at 8:18 AM maharani roxy <maharaniroxy@gmail.com> wrote:

Dear Rohan,

Thanks for the response. I am waiting it.

Regards,

Maharani L.A

Pada tanggal Jum, 22 Jul 2022 10.48, Rohan JCF Corp <rohan@jcfcorp.com> menulis:

Dear Dr. Maharani,

Thank you for sending us the updated file.

Within 10 business days, you will receive the copyediting of your article.

Regards,
Rohan Reddy
RDS

On Thu, Jul 21, 2022 at 4:39 PM maharani roxy <maharaniroxy@gmail.com> wrote:

Dear Rohan,

Thank you for the response. Here i send my manuscript that have been revised.

Regards,

Dr. Maharani

 **RDS 7-2.pdf**
769K

maharani roxy <maharaniroxy@gmail.com>
Kepada: Rohan JCF Corp <rohan@jcfcorp.com>

8 Agustus 2022 14.43

Dear Rohan Reddy,

Thank you for the galley proof of my article. I have checked it, and i think it is fine, so it does not need any changed or modification. Thank you

Best regards,

Dr. Maharani

[Kutipan teks disembunyikan]

Rohan JCF Corp <rohan@jcfcorp.com>
Kepada: maharani roxy <maharaniroxy@gmail.com>

8 Agustus 2022 15.12

Dear Dr. Maharani,

Thank you for confirming the galley proof.

Regards,
Rohan Reddy
RDS

[Kutipan teks disembunyikan]

maharani roxy <maharaniroxy@gmail.com>
Kepada: Rohan JCF Corp <rohan@jcfcorp.com>

11 Agustus 2022 06.31

You are welcome.

[Kutipan teks disembunyikan]

Anti-Inflammatory Effect of *Channa micropeltes* Extract in Angiogenesis of Diabetes Mellitus Wound Healing

Maharani Laillyza Apriasari¹, Dewi Puspitasari², Juliyatin Putri Utami³

¹Department of Oral Medicine, Faculty of Dentistry, Universitas Lambung Mangkurat, Banjarmasin, Kalimantan Selatan, Indonesia,

²Department of Dental Material, Faculty of Dentistry, Universitas Lambung Mangkurat, Banjarmasin, Kalimantan Selatan, Indonesia,

³Department of Biomedicine, Faculty of Dentistry, Universitas Lambung Mangkurat, Banjarmasin, Kalimantan Selatan, Indonesia.

Address correspondence to: Maharani Laillyza Apriasari, e-mail: maharaniroxy@gmail.com

Manuscript submitted July 09, 2022; resubmitted August 01, 2022; accepted September 06, 2022

Abstract

OBJECTIVE: *Channa micropeltes* extract contains albumin and omega-6 which possess antioxidant and anti-inflammatory agents that can promote macrophages in the wound healing process associated with diabetes mellitus (DM). In this study, we analyzed Nuclear Factor kappa B (NF-κB) and Vascular Endothelial Growth Factor (VEGF) expression as well as neovascular cells in the inflammatory stage of DM wound healing. **METHODS:** The 24 males *Rattus norvegicus* were divided into 3 groups that were 20% *Channa micropeltes* ointment (Group I), 10% *Channa striata* extract ointment (Group II), and placebo ointment as a control (Group III). Ointments were applied 3 times daily. **RESULTS:** The highest expression of NF-κB was observed in

Group III on Day 4 (15.50 ± 2.38), and the lowest was in treatment of Group I and Group II on Day 8 (4.75 ± 0.96). The highest expression of VEGF was observed in Group I on Day 8 (14.75 ± 0.96), and the lowest was Group III on Day 4 (7.00 ± 1.41). The highest count of neovascular cells was observed in Group I on Day 8 (11.00 ± 2.16), and the lowest was in Group III on Day 4 (5.50 ± 0.58). **CONCLUSIONS:** *Channa micropeltes* has an anti-inflammatory effect by regulating NF-κB expression and elevating VEGF expression in the angiogenesis process of DM wound healing.

Keywords: *channa micropeltes* · NF-κB · VEGF · neovascular · wound healing · diabetes mellitus · retinopathy

1. Introduction

Indonesia ranks sixth among countries with a high prevalence of diabetes mellitus (DM). In an uncontrolled state, DM will result in various oral problems such as xerostomia, candidiasis, stomatitis, gingivitis and periodontitis. The healing of such conditions is often complicated due to hyperglycemia that initiates chronic inflammation [1-3]. Previous study revealed that *Channa micropeltes* ointment at 20% concentration or *Channa striata* ointment at 10% concentration applied topically can accelerate wound healing in a DM rat model. Both species are categorized in the same genus and contain albumin as well as omega-6 that acts as an antioxidant and anti-inflammatory [3,4]. As an antioxidant, *Channa micropeltes* extract elevates superoxide dismutase (SOD) activity and lowers malondialdehyd (MDA) level on Day 7 [2]. As an anti-inflammatory, the topical application of *Channa micropeltes* at 20% concentration on the back skin of a diabetic rat model can increase the number of macrophage and lymphocyte cells on Day 8 and gradually reduce it on Day 14 [1].

Macrophage is the key inflammatory process in

wound healing. Reduction in macrophage number at the end of inflammatory stage demonstrates tissue recovery by producing growth factors and cytokines and inducing as well as terminating angiogenesis [5,6]. Macrophage is also produced Nuclear Factor kappa B (NF-κB) that regulates the inflammatory response of metabolic disease such as DM. A state of hyperglycemia in DM will increase reactive oxygen species (ROS) and advanced glycation end products (AGEs) that elevate chronic inflammation through the activation of NF-κB. This will change vascular endothelial growth factor (VEGF) expression that will generate the damage to blood vessels in the angiogenesis process [7,8].

The extract of *Channa micropeltes* has shown to promote wound healing on the skin of diabetic rat model by reducing macrophage number at the end of inflammatory stage [3]. There has been no study that explores the effect of *Channa micropeltes* application on NF-κB, VEGF, and neovascular cells that are pivotal components in the DM wound healing process. Based on that, a study to analyze the expression of NF-κB, VEGF and neovascular cells number at the inflammatory stage of the DM wound healing process was warranted.

2. Methods

This study was an experimental laboratory research study incorporating a post-test only control group design. It was approved by Ethical Clearance Committee, Faculty of Dentistry, Universitas Lambung Mangkurat, Banjarmasin, South Kalimantan, Indonesia, with number 111/KEPKG-FKGULM/EC/III/2020.

2.1 Manufacturing *Channa micropeltes* and *Channa striata* extract

Preparing both *Channa micropeltes* and *Channa striata* extract used fresh fish weighing 600-1000 grams. Each extract was later steamed in a pan for 25-35 minutes at a temperature of 60° Celsius. The flesh was enclosed with flannelette and pressed in a hydraulic device. Furthermore, *Channa micropeltes* and *Channa striata* were centrifuged for 15 minutes at a speed of 6000 rpm. Each extract was kept inside a dark glass bottle and then covered with aluminum foil and clean pack.

2.2 Formulation of *Channa micropeltes* and *Channa striata* ointment

Adeps lanae (Asian chemicals, Semarang) in a weight of 16.875 grams and vaselin flavum (PT. Brataco, 1295578) in a weight of 23.125 grams were used in the formulation of the *Channa micropeltes* ointment. Meanwhile, a combination of 16.875 grams adeps lanae and 28.125 grams vaselin flavum were combined in the formulation of *Channa striata* ointment. Adeps lanae was initially poured into different tubes for each extract and later added gradually with either *Channa micropeltes* at 20% concentration or *Channa striata* at 10% concentration. After the extract was fully absorbed by adeps lanae, the mixture was then mashed to obtain a homogenous consistency. Subsequently, the composition was further mixed with vaselin flavum and mashed again until homogenous.

2.3 In vivo study

This study included 2-3 months old male Wistar (*Rattus norvegicus*) rats (weight, 250-300 grams) obtained from an animal laboratory at the Faculty of Medicine, University of Lambung Mangkurat. The 24 rat specimens were kept in cages, and the temperature and humidity were set within ± 25 °C and 60%, respectively. They were fed standard BR-II, and they had access to boiled water *ad libitum*. Rats with hyperglycemia were obtained by injecting streptozotocin (STZ) at 35 mg/kg dosage until the blood glucose level was over 126 mg/dL-1; non-diabetic rats were ones without intervention. All animals were divided into 3 treatment groups consisting of 20% *Channa micropeltes* extract ointment, 10% *Channa striata* extract ointment, and placebo ointment as control. Each substance was applied topically 3 times daily (every 6-8 hours). An incisional wound was made on the back of the rats with 1 cm length and 1 mm

Abbreviations:

AGEs	Advanced Glycation End products
COX2	Cyclooxygenase 2
DM	Diabetes mellitus
ET-1	Endothelin-1
HE	Hematoxylin eosin
IHC	Immunohistochemistry
iNOS	Nitric oxide synthase
MDA	Malondialdehyd
mRNA	Messenger ribonucleic acid
NADPH	Nicotinamide adenine dinucleotide phosphate
NF- κ B	Nuclear Factor Kappa Beta
PDGF	Platelet Derived Growth Factor
RAGE	Receptor advanced glycation end product
ROS	Reactive oxygen species
SOD	Superoxide dismutase
STZ	Streptozotocin
VEGF	Vascular Endothelial Growth Factor

depth using sterile scalpel under inhaled anesthesia of 5 ml diethyl ether.

After the 4th and 8th day of application, rats were euthanized by inhaling a lethal dosage of diethyl ether. The back skin was then biopsied for histopathology examination using hematoxylin eosin (HE) to evaluate macrophages and neovascular cells, and immunohistochemistry (IHC) to evaluate NF- κ B and VEGF. The number of macrophages and neovascular cells were calculated in 3 different field locations using a light microscope (Olympus, WA) at 400 magnifications and subsequently calculated for its average. IHC staining was performed using anti-mouse NF- κ B monoclonal antibody (Santa Cruz Biotechnology Inc, Santa Cruz, CA, NF- κ B p65 (F-6): sc 8008) and anti-mouse VEGF monoclonal antibody (Santa Cruz Biotechnology Inc, Santa Cruz, CA, VEGF (C1): sc 7269). Positivity NF- κ B expression was defined as only distinct nuclear immunostaining, which is considered as activated NF- κ B in the studied field at 100 magnifications.

2.4 Data analysis

The results were analyzed using a 2-way analysis of variance parametric test based on the Shapiro-Wilk normality test and Levene's variance homogeneity test. The results showed normal data distribution and homogenous data variances. Consequently, further analysis by means of a *post hoc* Bonferroni test was conducted with a statistical significance of $p < 0.05$.

3. Results

Table 1 shows the results of NF- κ B analysis. The highest expression of NF- κ B was observed in the control group (Group III) on Day 4 (15.5 ± 2.38), and the lowest was in the treatment of 20% *Channa micropeltes* extract ointment (Group I) (4.75 ± 0.96) and

10% *Channa striata* extract ointment (Group II) (5.75 ± 1.71) on Day 8. The expression of NF- κ B between Group I and 10% *Channa striata* extract ointment (Group II) treatment groups did not show any difference ($p > .05$; Table 1). The statistical significance value between treatment group and day was $p > 0.05$, demonstrating no interaction between treatment groups and days on NF- κ B expression.

The highest expression of VEGF was observed in Group I (14.75 ± 0.96) on Day 8, whereas the lowest was in Group III (7.00 ± 1.41) on Day 4. The expression of VEGF showed statistically significant differences in all groups ($p < 0.05$; Table 1). The significance value between treatment groups and days was $p > 0.05$, demonstrating no interaction between treatment group and day on VEGF expression.

The highest count of neovascular cells was observed in Group I (11.00 ± 2.16) on Day 8, while the lowest was in Group III (5.50 ± 0.58) on Day 4. The count of neovascular cells showed statistically significant differences in all groups ($p < 0.05$; Table 1). The statistical significance value between treatment groups and days was $p > 0.05$, demonstrating no interaction between treatment groups and days on the number of neovascular cells.

4. Discussion

DM is characterized with an increase in blood glucose level that induces glycation reaction. This process will result in amadori production to formulate toxic proteins (AGEs). Interaction between AGEs and a receptor advanced glycation end product (RAGE) will increase the signal for nicotinamide adenine dinucleotide phosphate (NADPH) oxidase which produces superoxide anion. This process elevates the production of reactive oxygen species (ROS) which are the key for molecular signaling as well as the development of inflammatory disorders such as DM. Excessive production of ROS will complicate the healing process of wounds in DM [2,9].

Channa micropeltes contains albumin and omega-6 fatty acid. Albumin can decrease ROS by cutting chained oxidative reaction in the ROS formation's process.

Albumin can bind metal ions and also catch oxygen that processing hydrogen peroxide into non radical compound. Omega-6 fatty acid, especially arachnoidic acid are the keys to anti-inflammatory processes. It plays the role in stimulating macrophages to release growth factors, such as VEGF. Arachidonic acid will be metabolized through an enzymatic mechanism such as the 5-lipoxygenase and cyclo-oxygenase pathways that produce leukotrienes, prostaglandins, and thromboxane A2. These can stimulate cell migration and new local vascularization in the wound healing process of DM [4,10].

In previous studies, *Channa micropeltes* extract ointment at 20% concentration and *Channa striata* extract ointment at 10% concentration were shown to promote the wound healing process in DM. *Channa micropeltes* and *Channa striata* are categorized in the same genus. Both species contain albumin, the secondary antioxidant that can bind metal ion in ROS formation [1,2]. ROS induces an inflammatory response through the activation of Nuclear Factor kappa B (NF- κ B). NF- κ B signal is the main key of chronic inflammation in DM [7,8]. This is demonstrated by the study result on Day 4 that reveals the highest expression of NF- κ B in control group, while the result for 20% *Channa micropeltes* extract application was comparable to 10% *Channa striata* extract application (Figure 1).

Our study result on Day 8 demonstrates the reduction of NF- κ B expression in both *Channa micropeltes* extract ointment at 20% concentration and *Channa striata* extract ointment at 10% concentration when compared to the control. Topical application of *Channa micropeltes* extract at 20% concentration or *Channa striata* extract at 10% concentration may reduce excessive ROS, thereby suppressing NF- κ B expression. Both extracts possess potential as natural substances that may inhibit the expression of NF- κ B. Previous studies reveal that the impediment of pro-inflammatory NF- κ B from therapeutical application of several natural and synthetic ingredients will be a good target to manage vascular complication in DM [7]. A prolonged inflammatory response can be resolved

Table 1. The expression of NF κ B, expression of VEGF and count of neovascular cells

Group	Mean \pm SD (cells)					
	Expression of NF κ B		Expression of VEGF		Count of Neovascular	
	Day 4	Day 8	Day 4	Day 8	Day 4	Day 8
Channa micropeltes (Group I)	7.00 \pm 1.41 ^A	4.75 \pm 0.96 ^A	11.75 \pm 1.71 ^C	14.75 \pm 0.96 ^C	7.75 \pm 0.96 ^C	11.00 \pm 2.16 ^C
Channa striata (Group II)	7.75 \pm 1.26 ^A	5.75 \pm 1.71 ^A	10.50 \pm 1.29 ^B	12.50 \pm 1.29 ^B	6.25 \pm 0.96 ^B	9.00 \pm 0.816 ^B
Control (Group III)	15.50 \pm 2.38 ^B	10.00 \pm 2.58 ^B	7.00 \pm 1.41 ^A	9.75 \pm 0.96 ^A	5.50 \pm 0.58 ^A	6.25 \pm 0.96 ^A

Note.

Abbreviations: The different superscript character in each variable shows the differences for each group ($p < 0.05$).

A in Expression of NF κ B has value $p = 0.044$

B in Expression of NF κ B has value $p = 0.000$

A, B and C in Expression of VEGF has value $p = 0.000$

A, B and C in Count of Neovascular has value $p = 0.000$

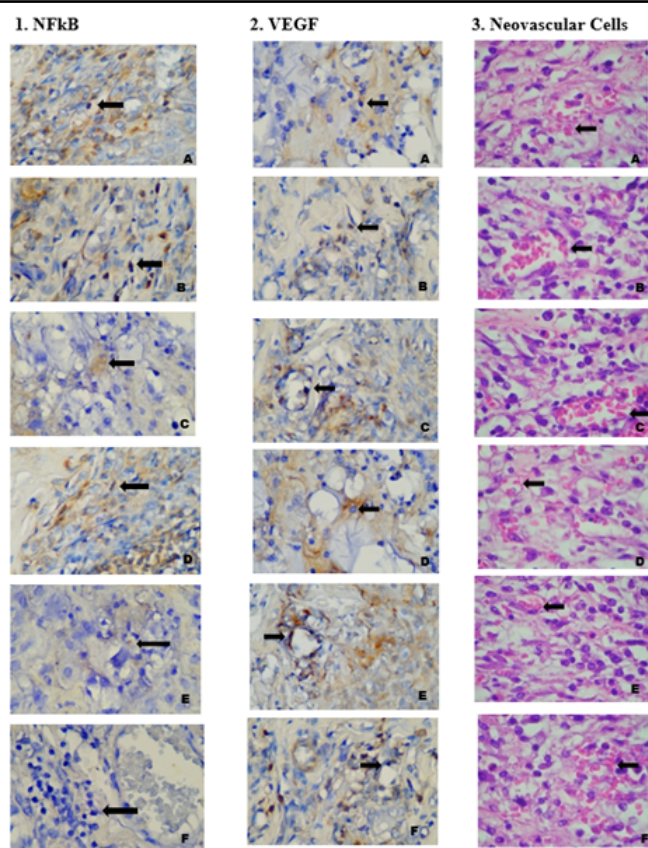


Figure 1. Macrophage expression of NF- κ B on the control group, Neovascular's expression of VEGF on the control group, and Neovascular cell's count on the control group.

Note: Macrophage's expression of NF- κ B on control group (A), *Channa micropeltes* extract concentrations of 20% (B), *Channa striata* extract concentrations of 10% (C) on Day 4. Macrophage's expression of NF- κ B on control group (D), *Channa micropeltes* extract concentrations of 20% (E), *Channa striata* extract concentrations of 10% (F) on Day 8. 2. Neovascular's expression of VEGF on control group (A), *Channa micropeltes* extract concentrations of 20% (B), *Channa striata* extract concentrations of 10% (C) on Day 4. Neovascular's expression of VEGF on control group (D), *Channa micropeltes* extract concentrations of 20% (E), *Channa striata* extract concentrations of 10% (F) on Day 8. 3. Neovascular cell's count on control group (A), *Channa micropeltes* extract concentrations of 20% (B), *Channa striata* extract concentrations of 10% (C) on Day 4. Neovascular cell's count on control group (D), *Channa micropeltes* extract concentrations of 20% (E), *Channa striata* extract concentrations of 10% (F) on Day 8.

by the inhibition of NF- κ B. As an anti-inflammatory substance, *Channa micropeltes* will reduce inducible nitric oxide synthase (iNOS) and cyclooxygenase 2 (COX2) that suppress the NF- κ B gene regulator. This will prevent prolonged inflammation in the wound healing process of DM [11,12].

Excessive activation of NF- κ B will cause abnormal DNA transcription which includes various gene expression of vascular complications occurring in VEGF, Platelet Derived Growth Factor (PDGF), Endothelin-1 (ET-1) and Transforming Growth Factor beta (TGF- β) that cause vascular cell damage [7]. VEGF as pro-angiogenic modulators encounter down regulation in DM, disturbing the angiogenesis process [13,14]. Prior studies demonstrate Vascular Endothelial Growth Factor A (VEGF-A) protein and messenger ribonucleic acid (mRNA) level in the wound of a diabetic rat model which shows reduction when

compared to the group with a normal wound. DM leads to the decrease of angiogenesis in wound healing, so that it lessens vascular and capillary density [13].

The angiogenic effect is initiated by VEGF-A binding to Vascular Endothelial Growth Factor Receptor-2 (VEGFR-2). Angiogenesis stimulation through PI3K-Akt-eNOS will cause endothelial cell to migrate, proliferate, and differentiate. Molecular signals will be commenced by phosphatidylinositol 3 kinase from serine/threonine kinase Akt/protein kinase B. Akt/PKB through the phosphorylation of endothelial nitric oxide synthesis on Ser 1177, and will stimulate NO production, vasodilatation, and endothelial cell migration [15,16]. This result presents that *Channa micropeltes* extract ointment at 20% concentration increases the highest expression of VEGF when compared to *Channa striata* extract ointment at 10% concentration or the control on Day 8. This exhibits the potential of *Channa micropeltes* extract ointment at 20% concentration to promote angiogenesis on the DM wound healing process.

Previous study by Carabelly et al. [1] reveals that the application of *Channa micropeltes* extract ointment at 20% concentration may elevate macrophage number on Day 8 and reduce them on Day 14. Macrophage regulates angiogenesis signals in neovascular along the formation of granulation tissue process [17]. This concept is in accordance with this study as the number of macrophages was observed the highest on Day 8 and followed by the increase of neovascular cell number by the application of *Channa micropeltes* extract ointment at 20% concentration on Day 8. The highest number of neovascular cells also was observed in the application of *Channa micropeltes* extract ointment at 20% concentration when compared to *Channa striata* extract ointment at 10% concentration or the control in Day 8. This study did not continue to further days to limit the parameters.

We can conclude that the application of *Channa micropeltes* extract ointment at 20% concentration on the wound of a diabetic rat model can reduce the expression of NF- κ B. The anti-inflammatory effect of *Channa micropeltes* can elevate the expression of VEGF and the number of neovascular cells in angiogenesis process of diabetic wound healing. Our findings require further research using different parameters, adding time of evaluation, and using larger experimental animals.

Acknowledgements: This study was financed by the Faculty of Dentistry, University of Lambung Mangkurat. The authors express their gratitude.

Conflicts of interest statement: The authors have no conflicts of interest to report.

Ethical approval: Approval for this study was provided by the Ethical Clearance Committee, Faculty of Dentistry, Universitas Lambung Mangkurat, Banjarmasin, South Kalimantan, Indonesia (#111/KEPKG-FKGULM/EC/III/2020).

■ References

1. **Carabelly AN, Firdaus IWAK, Nurmardina PC, Putri DA, Apriasari ML.** The Effect of Topical Toman Fish (*Channa micropeltes*) Extract on Macrophages and Lymphocytes in Diabetes Mellitus Wound Healing. The 1st International Seminar on Smart Molecule of Natural Resources. *Journal of Physics: Conference Series* 2019, 1-9.
2. **Apriasari ML, Ainah Y, Febrianty E, Carabelly AN.** Antioxidant Effect of *Channa micropeltes* in Diabetic Wound of Oral Mucosa. *International Journal of Pharmacology* 2019, 15(1):137-43.
3. **Apriasari ML, Puspitasari D.** Effect of *Channa micropeltes* for increasing Lymphocyte and Fibroblast Cells in diabetic Wound Healing. *Journal of Medical Sciences* 2018, 18(4):205-10.
4. **Apriasari ML, Syhadati MA, Carabelly AN.** Clinical Analysis of *Channa micropeltes* for Treating Wound of Diabetes Mellitus. *Berkala Kedokteran* 2020, 16(1):1-10.
5. **Brancato SK, Albina JE.** Mini Review: Wound Macrophages as Key Regulators of Repair Origin, Phenotype, and Function. *The American Journal of Pathology* 2011, 178(1):19-25.
6. **Koh TJ, DiPietro LA.** Inflammation and Wound Healing: The role of the macrophage. *Expert Rev Mol Med* 2011, 13(e23):1-14.
7. **Kulkarni YA, Suryavanshi SV.** NFκB: Apotential Target in the Management of Vascular Complications of Diabetes. *Frontiers in Pharmacology* 2017, 8:1-12.
8. **Baker RG, Hayden MS, Ghosh S.** NFκB, inflammation and metabolic disease. *Cell Metab* 2011, 13(1):11-22.
9. **Mittal M, Siddiqui MR, Tran K, Reddy SP, Malik AB.** Reactive Oxygen Species in Inflammation and Tissue Injury. *Antioxidants and Redox Signaling* 2014, 20(7):1-108.
10. **Carabelly AN, Utami JP, Aspriyanto D, Reksi MH, Puspitasari D, Rachmadi P.** Effect of *Channa micropeltes* in The Granulation, Fibrosis and Necrosis of Diabetic Wound Healing. *Dentino* 2021, 6(2):1-10.
11. **Apriasari ML, Pramitha SR, Puspitasari D, Ernawati DS.** Anti-Inflammatory Effect of *Musa acuminata* Stem. *European Journal of Dentistry* 2020, 14(2):294-8.
12. **Tan WS, Arulselvan P, Shio-Fern NG, Taib CNM, Sarian MN, Fakurazi S.** Improvement of diabetic wound healing by topical application of Vicenin-2 hydrocolloid film on Sprague Dawley rats. *BMC Complementary and Alternative Medicine* 2019, 19(20):1-16.
13. **Okonkwo U, DiPietro LA.** Diabetes and Wound Angiogenesis. *International Journal of Molecular Sciences* 2017, 18(1419):1-15.
14. **Zhang J, Guan M, Xie C, Luo X, Zhang Q, Xue Y.** Increased Growth Factors Play a Role in Wound Healing Promoted by Noninvasive Oxygen-Ozone Therapy in Diabetic Patients with Foot Ulcers. *Hindawi Publishing Corporation Oxidative Medicine and Cellular Longevity* 2014, 2014:273475.
15. **Ammineni S, Kamili C, Chidrawar VR, Rao UM.** A Review on Angiogenesis and Its Preventive Pathways. *International Journal of Universal Pharmacy and Bio Sciences* 2014, 3(6):50-4.
16. **Majewska I, Darmach EG.** Proangiogenic activity of plant extracts in accelerating wound healing: a new face of old phytomedicines. *Acta Biochimica Polonica* 2011, 58(4):449-60.
17. **Puspitasari D, Apriasari ML.** Analysis of traumatic ulcer healing time under the treatment of the Maui banana (*Musa acuminata*) 25% stem extract gel. *Padjadjaran Journal of Dentistry* 2017, 29(1):21-5.



maharani roxy <maharaniroxy@gmail.com>

Re: Manuscript Accepted for Publication RDS-2022-7-2

6 pesan

maharani roxy <maharaniroxy@gmail.com>
Kepada: Rohan JCF Corp <rohan@jfcfcorp.com>

2 September 2022 16.18

Dear Rohan,

Greeting,

I am still waiting my manuscript to be published in RDS. When it will be done? Thank you.

Regards,

Dr Maharani

Pada tanggal Jum, 15 Jul 2022 12.39, Rohan JCF Corp <rohan@jfcfcorp.com> menulis:

Dear Dr. Maharani,

Thank you for processing the payment and sending us the receipt.

We will forward it to our finance department, and we will let you know the further update.

Regards,

Rohan Reddy

RDS

On Fri, Jul 15, 2022 at 9:05 AM maharani roxy <maharaniroxy@gmail.com> wrote:

Dear Rohan RDS,

To day i have paid the invoice. Here i send you the proof of payment. Please, tell me if you get it. Thank you.

Best regards,

Dr Maharani

Pada tanggal Kam, 14 Jul 2022 21.28, Rohan JCF Corp <rohan@jfcfcorp.com> menulis:

Dear Dr. Maharani,

Thank you for the update.

Regards,

Rohan Reddy

RDS

On Thu, Jul 14, 2022 at 6:33 PM maharani roxy <maharaniroxy@gmail.com> wrote:

Dear Rohan Reddy RDS,

Thank you for the information. Tomorrow i will pay it by bank transfer, so please wait it.

Best regards,

Dr. Maharani Laillyza Apriasari

Pada tanggal Kam, 14 Jul 2022 11.28, Rohan JCF Corp <rohan@jfcfcorp.com> menulis:

Dear Dr. Maharani,

Thank you for your email.

Your article will be published in the September 2022 issue.

After receiving the payment receipt from you, we will process your article through english editing, copy editing and galley proof stages.

We request you to kindly make the payment at the earliest.

Regards,
Rohan Reddy
RDS

On Thu, Jul 14, 2022 at 3:07 AM maharani roxy <maharaniroxy@gmail.com> wrote:

Dear Rohan Reddy RDS,

Thank you for the invoice. Before i pay it, i want to ask you some questions. First, when my manuscript will be published? Second, what the next step after i paid it? Thanks before.

Best regards,

Dr Maharani Laillyza Apriasari

Rohan JCF Corp <rohan@jcfcorp.com>
Kepada: maharani roxy <maharaniroxy@gmail.com>

2 September 2022 16.21

Dear Dr. Maharani,

Thank you for your email.

Your article will be published online by the end of this month.

Regards,
Rohan Reddy
RDS

[Kutipan teks disembunyikan]

maharani roxy <maharaniroxy@gmail.com>
Kepada: Rohan JCF Corp <rohan@jcfcorp.com>

2 September 2022 16.25

Dear Rohan,

Thank you for the information.

Regards,
Dr.Maharani

[Kutipan teks disembunyikan]

maharani roxy <maharaniroxy@gmail.com>
Kepada: Rohan JCF Corp <rohan@jcfcorp.com>

29 September 2022 05.18

Dear Rohan,

I am still waiting for my manuscript to be published on last september. May i know when it will be? Thank you.

Regards,
Dr. Maharani

[Kutipan teks disembunyikan]

Rohan JCF Corp <rohan@jcfcorp.com>
Kepada: maharani roxy <maharaniroxy@gmail.com>

29 September 2022 11.24

Dear Dr. Maharani,

Thank you for your email.

Your article will be updated within a week.

Regards,
Rohan Reddy
RDS

[Kutipan teks disembunyikan]

maharani roxy <maharaniroxy@gmail.com>
Kepada: Rohan JCF Corp <rohan@jfc Corp.com>

29 September 2022 11.35

Dear Rohan,

Thank you for your information.

Regards,
Dr.Maharani

[Kutipan teks disembunyikan]