

The Importance of Ultrasound Findings in Children with Acute Abdominal Pain to Prevent Unnecessary Surgery

by Herlina Uinarni

Submission date: 26-Jun-2020 07:09AM (UTC-0700)

Submission ID: 1350017333

File name: 1_The_Importance_of_Ultrasoundnull (656.81K)

Word count: 4824

Character count: 26792

The Importance of Ultrasound Findings in Children with Acute Abdominal Pain to Prevent Unnecessary Surgery

Herlina Uinarni^{1,2*}, Conny Tanjung², Huldani³, Aminuddin Prahatama Putra⁴, Mashuri⁵, Bayu Indra Sukmana⁶, Heru Wahyudi⁷, Abdullah Zuhair⁸, Aderiel Gabrian Tarius⁸, Wisnu Wiryawan⁸, Renie Kumala Dewi⁹, Yunita Feby Ramadhany¹⁰, Harun Achmad¹⁰

¹Department of Anatomy, School of Medicine and Health Sciences Atma Jaya Chatolic University of Indonesia

²Departement of Radiology, Pantai Indah Kapuk Hospital, Jakarta, Indonesia

³Departement of Physiology, Faculty of Medicine, Lambung Mangkurat University, Banjarmasin, Indonesia

⁴Departement of Radiology, Faculty of Medicine, Lambung Mangkurat University, Banjarmasin, Indonesia,

⁵Departement Biology, Faculty of Teacher Training and Education, Lambung Mangkurat University, Banjarmasin, Indonesia

⁶Departement of Oral Radiology, Dentistry Medical Faculty, Lambung Mangkurat University, Banjarmasin, Indonesia

⁷General Practitioner, Ratu Zalecha Hospital, Martapura, Indonesia,

⁸Student of Medical Education, Faculty of Medicine, Lambung Mangkurat University, Banjarmasin, Indonesia

⁹Departement of Pediatric Dentistry, Dentistry Medical Faculty, Lambung Mangkurat University, Banjarmasin, Indonesia

¹⁰Departement of Pediatric Dentistry, Hasanuddin University, Makassar, South Sulawesi, Indonesia.

*Corresponding author: herlina.uinarni@atmajaya.ac.id

18

Article History:

Submitted: 10.01.2020

Revised: 12.03.2020

Accepted: 24.04.2020

ABSTRACT

Background: Abdominal pain is common in children that can manifest as acute or chronic. In some cases, it requires immediate management. The most difficult challenge is to make diagnosis to identify the cause.

Objective: This study is aimed to demonstrate the evidence of the use of abdominal ultrasonography (AUS) to determine the cause of pain in relation to surgical decision.

Methods: Patients with acute abdominal pain were referred for AUS. Prospective cross-sectional method was done in 268 children aged 5 to 15 years old, in which 116 of them are male. Patients who did not require surgery and outpatients were asked to make a response whether the improvement during and after the treatment. Patient who were required surgical, will be confirmed by histopathology.

Results: No abnormalities (53.73%). The abnormal findings were: enterocolitis (13.43%), mesenteric adenitis (12.68%), constipation (6.72%), appendicitis (6.34%), cystitis (5.97%), adrenal tumor (0.07%)

and intussusception (0.04%). Findings shows, the use of AUS to determine the cause were able to reduce surgical decision from 27.98% to 7.46%. Thus, ultrasonography changed the management plan in 20.52% of patients.

Conclusion: The AUS is useful for evaluation abdominal pain in children. An accurate diagnosis is important to prevent unnecessary surgery.

Keywords: Abdominal Ultrasound, Acute Abdominal Pain, Children.

Correspondence:

Herlina Uinarni

Department of Anatomy, School of Medicine and Health Sciences, Atma Jaya Chatolic University of Indonesia

Department of Radiology, Pantai Indah Kapuk Hospital, Jakarta, Indonesia

Indonesia

E-mail: herlina.uinarni@atmajaya.ac.id

DOI: [10.31838/srp.2020.4.56](https://doi.org/10.31838/srp.2020.4.56)

©Advanced Scientific Research. All rights reserved

INTRODUCTION

Abdominal pain in paediatrics can manifest as either acute or recurrent pain. Acute abdominal pain is defined as a severe, sudden, and persistent pain that requires surgical intervention. Appley defined recurrent abdominal pain as an attack that occurred at least 3 times in 3 months within the past 1 year.¹ Epidemiological data shows that 10-12% of boys in the age 5-10 suffered from abdominal pain, but the incidence rate keep on decreasing later on. Girls are more prone to functional abdominal pain than boys with the ratio of (15.9% vs 11.5%).²

Barr classified abdominal pain into 3 groups: organic, dysfunctional and psychogenic. Organic pain is caused by a particular disease, such as urinary tract infection. Diagnosis of an organic disease as the cause of recurrent abdominal pain have been reported, but only found in 5-15.6% of the cases.³ Dysfunctional pain is caused by a variety of normal physiology and is divided into two categories, the specific pain syndrome (if the mechanism to produce pain is known) and nonspecific pain syndrome (if the mechanism is unclear or unknown). Psychogenic pain is caused by either emotional or psychosocial stress in absence of organic abnormalities or

dysfunction. The cause of recurrent abdominal pain is the biggest contributing factor of psychophysiology.^{1,3}

Diagnosing abnormalities of the abdominal organs requires radiological imaging in order to find the cause of abdominal pain in children. The imaging techniques such as fluoroscopy, computed tomography (CT-scan) and magnetic resonance imaging (MRI) are advanced, but plain abdominal radiography remains the modality of choice to assess the signs and symptoms of suspicious bowel pathologies. On the other hand, AUS plays a very significant role in detecting the presence of abdominal organ pathology in pediatric patients. In our hospital, AUS is the first modality of choice in assessing pediatric patients with abdominal pain. In certain conditions in which AUS could not be done optimally, such as the presence of excessive intestinal gas, an additional procedure such as X-Ray is conducted to eliminate the presence of abdominal organ perforation. AUS alone have often been able to identify the cause of some common conditions such as: gastroenteritis, mesenteric lymphadenopathy, appendicitis, constipation, as well as rare conditions such as intussusception, duplication cysts, adrenal tumor and pyloric stenosis. This article is a presentation of

the cases found using AUS in children with acute abdominal pain emphasized in children aged 5-15 years. Cases such as mesenteric lymphadenitis, cystitis, colitis, appendicitis and constipation are found using AUS. Using AUS as the modality to determine the cause of abdominal pain were able to reduce surgical decision and changed the management plan in some of the patients.

The study protocol was reviewed and approved by ethics committee of Atmajaya University. (N0: 16/04/KEP-FKAUA/2012). No additive evaluation was ordered for the patients enrolled in this study hence, no informed consent was requested from the patients and their parents. However study aims was explained for their parents and they were informed that they were entered in our study.

METHODS

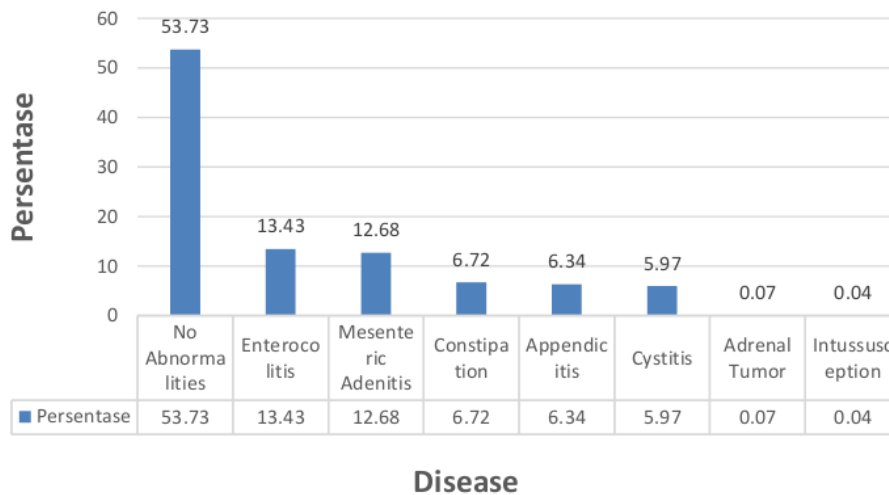
Prospective cross-sectional method was conducted in this study. Total of 268 children were involved, ranged from age 5 to 15 years old, in which 116 of them are male and 152 of them are female. The children are they who came with the complaint of colic/acute abdominal pain of any reasons, and who sought for treatment to the pediatric outpatient clinics at Pantai Indah Kapuk Hospital. After the pediatricians found out that the patients were presented with acute abdominal pain, they were referred to the department of radiology for AUS examination to determine the source of pain. Based on the result, pediatricians would decide whether the patients need to be admitted to hospital or not. The

inclusion criterion was acute abdominal pain. The exclusion criteria were chronic abdominal pain (pain for more than 3 months and affected the child's daily activities), incomplete data (when not all of the abdominal organs could be evaluated due to excessive gas), absence of post-therapeutic result, and absence of operative and histopathology report. The examinations were done using General Electric S6 ultrasound machine and was performed in all abdominal and pelvic areas by radiologists (the researcher), using sector and linear transducers. All organs that could be assessed by ultrasound were carefully analyzed. All images were printed on paper, but only images with pathological findings were copied to the compact disc.

RESULTS

A total of 268 children, 5 to 15 years of age, who came with abdominal pain were examined from June 2012 to Mey 2013. The result of AUS showed 53.73% children had no abdominal organ abnormalities. The abnormal findings were, respectively: enterocolitis (13.43%), mesenteric adenitis (12.68%), constipation (6.72%), appendicitis (6.34%), cystitis (5.97%), adrenal tumor (0.07%) and intussusception (0.04%). Surgery was planned in 27.98% patients beforehand, but after the ultrasound procedure was done the needs for surgical intervention decreased to 7.46%. Thus ultrasonography changed the management plan in 20.52% of patients. Most of the patients did not require any surgical management.

Graph 1. Findings of Abdominal Ultrasonography (AUS) in Acute Abdominal Pain



DISCUSSION

From the most to the least common findings, the result of the AUS examination were as follows: 1. No abnormalities of abdominal organs, 2. Enlargement of the lymph node, 3. Cystitis, 4. Colitis, 5. Hydronephrosis, 6. Appendicitis, 7. Constipation, intussusception, 8. Adrenal tumor. Some of the cases will be discussed below. No abdominal organ abnormality, this condition was found in 90% of children at the age of 5- 10 years old. In this study, 10% of the patients have organic abdominal pain, while reported prevalence of organic abdominal pain in children varied between 10% and 30%.⁴

Spleen, the mucosa-associated lymphoid tissue, and the lymph nodes are our body's second line of immune system. Lymph node diameter varies between 0.2- 2.5 cm, depends on the function and location of the lymph node as well as the age of the patient.^{5,6} Enlargement of nodes (lymphadenopathy) are usually caused by inflammation process, either by local or systemic conditions. Some example of local inflammation resulting in mesenteric lymphadenopathy are infections such as: appendicitis, diverticulitis, cholecystitis, and pancreatitis. Lymphadenopathy can also be caused by malignancies (Hodgkin/Non-Hodgkin's disease, leukemia, metastasis, etc.) as well as immunological processes.

Mesenteric lymphadenopathy may also be occurred as part of

an inflammatory response in the case of perforation of the abdominal organs.⁶ Lymph node morphological assessments are mainly based on clinical history, location, age, palpation, experience and physical exam, while ultrasound findings are only secondary data, the definite diagnosis are by histopathology.⁵ Lymph node was often found in the lower right abdomen near the terminal ileum, caecum and appendix.^{5,6,7,8}

Enlarged mesenteric nodes were found in lower right region (88%) in which 28% of them was categorized as mesenteric lymphadenitis.⁶ Mesenteric nodes are considered enlarged when the size of the short axis is >8 mm.^{7,8} (Figure 1). Mesenteric lymphadenitis is an inflammation of the lymph node in the abdominal mesentery. Its main symptom is abdominal pain, often located in the lower right region to right iliac fossa, while some of the cases could heal spontaneously or felt intermittently. The pain is described as a non-localized pain in the abdomen that goes together with peristaltic movement, while appendicitis pain often start around the umbilical area then moves to the right iliac fossa, rarely goes to another area. Another difference is that one or two weeks prior to the pain there are history of common cold and throat infection. It was estimated that 1 in 5 children who were clinically diagnosed with appendicitis was actually suffering from lymphadenitis.⁹

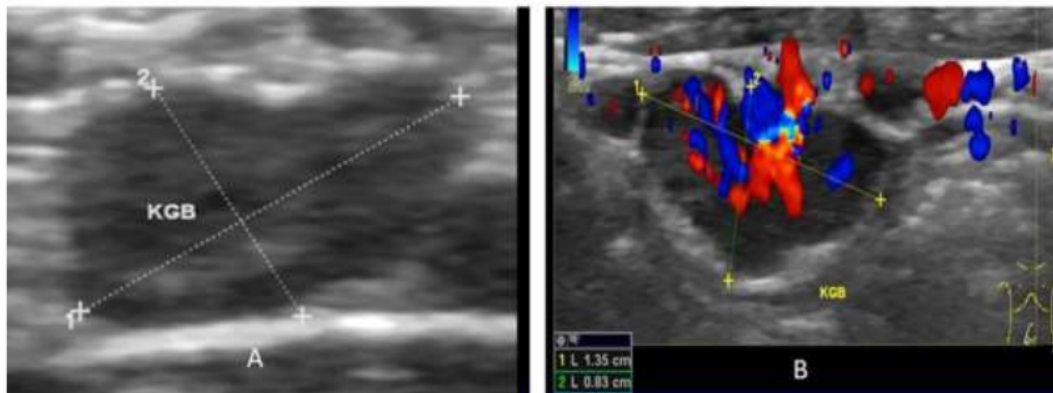


Figure 1: Enlarged nodes, Gray-scale ultrasound (A)

The cause of mesenteric lymphadenitis is frequently evolved from common cold cause by viral infection, *Yersinia enterocolitica*, Pseudo-tuberculosis, *Streptococcus viridans* or *Campylobacter jejuni*.^{8,9} The source of infection spreads to intestinal wall by invasion to the lymph nodes around the intestines. All parts of the intestines may be affected, but small intestines are the most common. Enlargement of nodes cause the mesenteries to stretch, in which will further aggravating the pain. Some of these conditions could be self-limiting but in certain cases, these conditions could get worse where the pus would be formed and cause more extensive infection.⁹ Mesenteric adenitis is diagnosed based on: clinical history, physical examination, laboratory and radiological

examination. Increase in white blood cell count (showing a typical condition of infection) in complete blood test and positive *Yersinia enterocolitica* serology test will support the diagnosis of mesenteric adenitis. Through AUS, enlarged lymph node (Figure 1) in the form of hypoechoic nodules will be seen, which is different from the surrounding tissue and mesenteric thickening will also support the diagnosis.⁹

Cystitis is part of urinary tract infection (UTI) defined as the colonization of pathogens that occurs anywhere along the urinary tract: kidneys, ureters, bladder, and urethra. Traditionally, UTI is classified based on the site of infection: pyelonephritis (kidney), cystitis (bladder), urethritis (urethra) and based on the severity (with or without

28
complication). UTI is one of the most common infections in the pediatric patients. UTI complications occur when the urinary tract is infected because of structural or functional abnormalities, or the presence of a foreign object, such as urinary catheter. Abnormalities in AUS were found in 12% of the study population who were diagnosed with UTI. Vesicoureteral reflux was diagnosed in about 50% of the children with UTI aged less than 1

Doppler ultrasound (B)

year. In pediatric patient it is more simple and practical to categorize UTI as the first-episode infection or recurrent case. Unlike UTI in adult which is generally benign, UTI in the pediatric population is believed to be one of the causes of

22
acute morbidity and chronic medical conditions, such as hypertension and renal failure in adulthood. Definitive diagnosis of UTI is the urine culture.¹⁰ The route of infection in UTI is through fecal-perineal-urethral-bladder. Because of anatomical structure differences, at the same age of one year of the first year of life, girls have a higher risk of UTI compared to boys. In girls, the periurethral and vaginal area are moist; therefore becoming a suitable medium for the growth of uropathogens. The short urethra in women is also contributing for the uropathogens to reach the bladder easily. A typical ultrasound picture of cystitis shows thickening of the lateral and posterior wall in a half-filled bladder (Figure 2). Another sign of cystitis is the presence of debris (found in the bladder) that moves when child is repositioned.^{10,11}

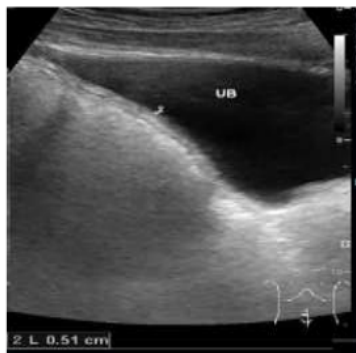

Figure 2: Cystitis in ultrasound, the thickness of the bladder wall >3.0mm

Initially AUS was used to assess intestinal morphology, the pylorus and surrounding structures on infants with vomiting. Compression ultrasonography was needed to assess the appendix and other intestinal loops. Now ultrasound is used in assessing intestinal morphology including the thickness of the bowel wall, bowel dilatation, muscular hypertrophy, blood flow and the presence of a mass or other abnormalities.¹² The size of normal bowel wall thickness is <3mm.¹³

The digestive system which extends from oesophagus down to rectum, have a characteristic multi-lamellated appearance in AUS, compatible with their histological structure. This pattern distinguishes the intestine from adjacent structures, and disruption of the pattern could help in diagnosing intestinal pathology. Bowel wall thickening is the most common sign of intestinal disease. Thickening with concentric pattern is a sign of benign disease while eccentric pattern is usually a sign of malignancy, but some of them are overlapping. In general, the abnormal intestine structures are more easily seen with ultrasound compared to normal condition due to the decreased bowel movement.¹⁴

Until these days, CT has become a reliable tool to evaluate acute abdominal pain. However, considering the radiation effect especially on pediatric patients, the use of AUS to evaluate intestine is still the modality of choice.¹⁴ Fat tissue of the mesenteries and omentum are usually easier to see

through the ultrasound, unless under inflammatory condition. Oedema and inflammatory cell infiltration are more likely to increase the echogenicity of fat tissue.^{14,15} Doppler imaging help to evaluate whether hyperemia is present and the necrotic part could be detected if there is no blood flow.¹⁶ The information got by Doppler ultrasound completed the overall intestinal morphology. Increase of vascularization could indicate inflammatory disease and infection.^{14,15}

Dynamic analysis using AUS, has the benefits to observe intestinal motility, compressibility, and positional change in real time. Decrease in intestinal peristaltic movement is a nonspecific indicator of an unhealthy small intestine. A number of conditions, such as small intestinal obstruction, ischemia, enteritis and infiltration process can be the underlying cause of a decrease in peristaltic movement, while hyperperistaltic movement may appear in early partial intestinal obstruction. Healthy bowel can also be compressed and shifted by the pressure transducer. This technique is commonly used to assess appendicitis, intussusception, intestinal malignancy, or distention of lumen obstruction.¹⁴ Appendicitis, an infection of the appendix presenting as an acute abdominal pain is an emergency condition that is common in childhood. It often requires immediate surgery.^{16,17,18,19} It is believed that most of the cases of appendix lumen obstruction is due to fecal impaction or

faecolith, in which then invaded with the bacteria. The appendix may rupture in some cases, then forming a peri-appendicular abscess. In physical examination patients with appendicitis have classic symptoms, consisting of periumbilical pain migrating to the right lower quadrant, accompanied by fever and leukocytosis. However, the classic sign are not always there, and the symptoms can be nonspecific or overlapping with other causes of abdominal pain.⁷

The use of CT-scan has been the first choice of imaging of acute abdominal pain, with a sensitivity of 96% and specificity to 97%. However, due to the considerations in radiation dose in patients doing CT and increased theoretical risk of radiation-induced cancer in children, so its use is limited. AUS to evaluate disease primarily assess the appendix in several studies have shown that the same accuracy with CT. Therefore, AUS should be used as a primary diagnostic modality in the evaluation of suspected

case of acute appendicitis in children. In 1986, Puylaert reported assessment techniques to evaluate acute appendicitis with compression ultrasound. Since then, many studies about the use of AUS as a diagnostic tool have been published.^{17,19} AUS criteria for the diagnosis of appendicitis blind identification includes a tubular structure that cannot be compressed to a diameter of 6 mm or more⁵. Since 1990, several studies have shown that high-resolution ultrasound is an accurate method for diagnosing acute appendicitis in children. In children, ultrasound for appendicitis had a sensitivity of 97.9% and specificity 91.7%²⁰. AUS image of acute appendicitis (Figure 3) shows: target sign in axial view with diameter more than 6 mm and tubular structure in longitudinal view, distention and obstruction of lumen, no peristaltic movement, non-compressible, increased echogenicity of the surrounding structures, free pericaecal or perivesical fluid, signs of local ileus paralytic and appendicolith.

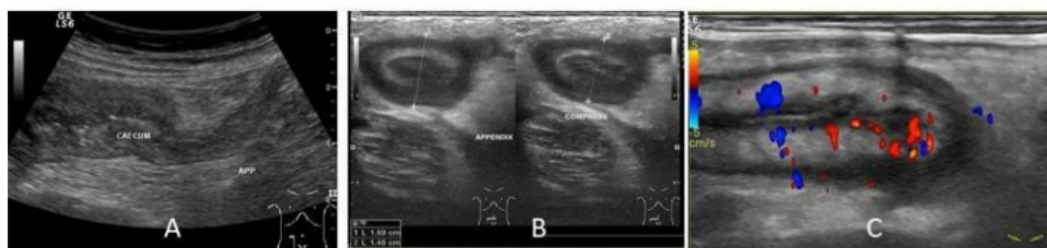


Figure 3: Ultrasound normal appendix at the terminal of caecum (A). Uncompressed appendix in acute appendicitis (B). Appendix in longitudinal view with Doppler ultrasound, thickening of appendix wall in acute appendicitis (C).

AUS findings in perforation shows: tubular homogenous structure and nonvisualized appendix wall, absence of peristaltic movement, homogenous pericaecal area, presence of mass without peristaltic movement, intestinal loop thickening with the decrease of peristaltic movement and the presence of sludge inside the urinary bladder. In the condition when patients with typical symptoms of appendicitis not detected by AUS (the appendix is not visualized, or doubtful), it is recommended that AUS examination should be repeated again in accordance with clinical data. In fact, it has been reported that 98% of false-negative ultrasound findings are due to the nonvisualization of the appendix. Factors contributed to result of ultrasound are: the retrocaecal location of the appendix and obese patients. In patients with these conditions, it is more difficult to use high frequency transducer because of the lower spatial resolution. In this case, further evaluation with CT can be considered, as suggested by several researchers.¹⁹ The maximum outer wall diameter must be less than 6 mm and mural thickness should less than 2 mm. Compression of the appendix should be done and documented. Secondary signs such as free water, fecolith, and the fat surrounding the hypochoic area should also be documented. Doppler

imaging is helpful to evaluate the presence of hyperemia, in which blood flow is decreased or absent in necrotic appendix.¹⁶

The physiology of defecation is a complex process involving coordinated activity of abdominal and pelvic muscles, and anal sphincter relaxation, stimulated by distention of the rectum by the stool. After continence has been reached, defecation may be inhibited by external anal sphincter contraction. Difficulty of passing stool occurs when there is abnormal contraction of the sphincter and pelvic floor whendefecating. Constipation is a common problem in children. Generally, children will be considered having constipation if they pass stool less than three times a week, and when the stool is large, hard, and dry. The prevalence of constipation is reported to fall between 0.3% to 2.8%, more commonly found in children with less fiber consumption. In the school age, constipation occurs more in boys than in girls (ratio 3:1) and mostly functional (no objective evidence of pathological condition).²¹

No general definition is applied about constipation. Subjective criteria are mostly used, such as defecation frequency and stool consistency. Constipation usually occurs in children with underlying anorectal/spinal abnormality.

However, functional idiopathic constipation commonly occurs in children. There are many etiological factors of constipation, and it is important to differentiate whether they are functional or organic.²² Clinical evaluation of constipation is often difficult with only plain abdominal x-ray, which is commonly used in diagnosing constipation. Objective scoring technique includes the amount of stool in the abdomen to evaluate constipation is introduced by researchers like Barr et al, Leech et al, and Blethyn et al. Criteria, such as duration of transit by recording time needed for the stool to come out. This technique is done by collecting stools or taking plain abdominal x-ray every day for 4-5 days. Some literatures state normal colon transit time is <66 hours, constipation is when the transit time is 66-100 hours, and also very delayed type to reach >100 hours.²³ Plain abdominal x-ray often used to support the clinical history and examination.

Researchers recommend to evaluate stool retention using ultrasound. In chronic constipation, rectal ampulla which is the upper part of superior rectum to levator ani muscle will get bigger (megarectum). Children with constipation had transverse diameter of rectal ampulla, bigger compared to children without constipation.²³ Singh et al reported the usage of transpubic ultrasound to measure rectal diameter which is crescent-shaped in children with constipation. The crescent-shaped rectum is measured posterior to the bladder. Measurement of rectal diameter and evaluation of stool retention are done with ultrasound when the bladder is full or half empty the examinations that could be done as follows.²⁴ To measure the transverse diameter of rectal ampulla, ultrasound probe should be placed superior to symphysis. Measurement needs to be repeated due to possibility in measuring the upper part of anus diameter instead of the rectal ampulla. This is because of the probe deflection in transverse plane. The largest measurement are taken as the final result. Whether the rectal ampulla is empty or not is determined by evaluating impacted stool in plane of a completely filled bladder. Impacted stool will be displayed as either well defined, with or without haustrations.^{23,24} Evaluating the stool filling the splenic flexure in ultrasound is based on the visualization of the left kidney through spleen window. Longitudinal axis of ultrasound cut along the spleen's long axis and left kidney. Lastly, evaluating the transverse colon is based on the visualization of the mesogastrium structure through left liver lobe window.²³ The median value for rectal width in constipated children are 3.4 cm.^{24,25,26}

CONCLUSIONS

In conclusion, in many pediatric patients with abdominal pain, who had neither anatomical nor organ abnormality detected, ultrasound examination does not contribute to make a diagnosis. Abdominal Ultrasound is useful to evaluate presence of organ abnormality particularly to identify appendicitis and other causes such adenitis because both cases have similar clinical presentation despite of different

management. AUS also decrease the needs to use abdominal x-ray.

REFERENCES

1. Yousif A.E & Aziz, M.Y. (2012). Biomechanical analysis of the human femur bone during normal walking and standing up, *IOSR Journal of Engineering*, 2(8): 13-19.
2. Saps M, Seshadri R, Sztainberg M, et al. (2009). A prospective school-based study of abdominal pain and other common somatic complaints in children. *J Pediatr*; 154:322.
3. Korterink JJ, Diederik K, Benninga MA, Tabbers MM. (2015). Epidemiology of pediatric functional abdominal pain disorders: a meta-analysis. *PLoS One*; 10:e0126982.
4. Boediarso, Aswitha. (2010). Sakit Perut pada Anak. Dalam: Juffrie, Mohammad, dkk., ed. *Buku Ajar Gastroenterologi-Hepatologi*. Jilid 1. Jakarta: IDAI, 149-164.
5. Farion KJ, Michalowski W, Rubin S, Wilk S, Correll R, Gaboury I. (2008). Prospective evaluation of the MET-AP system providing triage plans for acute pediatric abdominal pain. *Int J Med Inform*.77(3):208-218.
6. Schmidt G. (2011). *Differential Diagnosis in Ultrasound Imaging: A Teaching Atlas*. Thieme.
7. Karmazyn B, Werner EA, Rejaie B, Applegate KE. (2005). Mesenteric lymph nodes in children: what is normal? *Pediatr Radiol*. Aug 1;35(8):774-7.
8. Lucey BC, Stuhlfaut JW, Soto JA. (2005). Mesenteric Lymph Nodes: Detection and Significance on MDCT. *Am J Roentgenol*. Jan 1;184(1):41-4.
9. Simanovsky N, Hiller N. (2007). Importance of Sonographic Detection of Enlarged Abdominal Lymph Nodes in Children. *J Ultrasound Med*. 2007 May 1;26(5):581-4.
10. Mesenteric Lymphadenitis. [ABDOPAIN.com](http://www.abdopain.com/mesenteric-lymphadenitis.html). Available from: <http://www.abdopain.com/mesenteric-lymphadenitis.html>
11. Chang SL, Shortliffe LD. (2009). Pediatric Urinary Tract Infections. *Pediatr Clin North Am*. Jun 1;53(3):379-400.
12. Vrljićak K, Milošević D, Batinić D, Kniewald H, Nižić L. (2006). The Significance of Ultrasonography in Diagnosing and Follow-up of Cystic Cystitis in Children. *Coll Antropol*. Apr 10;30(2):355-9.
13. Cohen HL, McGahan JP, Hertzberg BS, Meilstrup JW, Needleman L, Hashimoto BE, et al. (2008). AIUM practice guideline for the performance of an ultrasound examination of the abdomen and/or retroperitoneum. *J Ultrasound Med*. Feb;27(2):319-26.
14. Chiorean L, Dietrich S, Braden B3, Cui X, Dietrich CF. (2014). Transabdominal ultrasound for standardized measurement of bowel wall thickness in normal children and those with Crohn's disease. *Med Ultrason*. Dec;16(4):319-24.

15. Maturen KE, Wasnik AP, Kamaya A, Dillman JR, Kaza RK, Pandya A, et al. (2011). Ultrasound Imaging of Bowel Pathology: Technique and Keys to Diagnosis in the Acute Abdomen. *Am J Roentgenol*. Dec 1;197(6):W1067-75.
16. Wilson SR. (2005). The gastrointestinal tract. In: RumackC, WilsonSR, CharbonneauJW, JohnsonJM, eds. *Diagnostic ultrasound*. St Louis, MO: Elsevier Mosby;269-320.
17. Linam LE, Munden M. (2012). Sonography as the First Line of Evaluation in Children With Suspected Acute Appendicitis. *J Ultrasound Med*. Aug 1;31(8):1153-7.
18. Siegel MJ. (2002). *Pediatric Sonography*. Lippincott Williams & Wilkins.
19. Puig S, Hörmann M, Rebhandl W, Felder-Puig R, Prokop M, Paya K. (2003). US as a primary diagnostic tool in relation to negative appendectomy: six years experience. *Radiology*. Jan;226(1):101-4.
20. Mittal MK, Dayan PS, Macias CG, Bachur RG, Bennett J, Dudley NC, Bajaj L, Sinclair K, Stevenson MD, Kharbanda AB. (2013). Performance of ultrasound in the diagnosis of appendicitis in children in a multicenter cohort. *Pediatric Emergency Medicine Collaborative Research Committee of the American Academy of Pediatrics. Acad Emerg Med*. Jul;20(7):697-702. doi: 10.1111/acem.12161.
21. Smith AGC. (2005). Constipation and toileting issues in children. *Med JAust*. ;182(5):242-6.
22. Van der Wal MF, Benninga MA, Hirasing RA. (2005). The Prevalence of Encopresis in a Multicultural Population: *Journal of Pediatric Gastroenterology and Nutrition*. *J PediatrGastroenterolNutr*;40(3):345-8.
23. Bijos A, Czerwionka-Szaflarska M, Mazur A, Romanczuk W. (2007). The usefulness of ultrasound examination of the bowel as a method of assessment of functional chronic constipation in children. *PediatrRadiol* ;37:1247-1252.
24. Huldani, Pattelongi I, Massi MN, Idris I, Bukhari A, Widodo ADW, Achmad H. (2020). Research Reviews Effect of Exercise on DAMP's of HMGB1, Proinflammatory Cytokines and Leukocytes. *Sys Rev Pharm*. 11(4): 306 31
25. Singh SJ, Gibbons NJ, Vincent MV, Sithole J, Nwokoma NJ, Alagarswami KV. (2005). Use of pelvic ultrasound in the diagnosis of megarectum in children with constipation. *J Pediatr Surg*. Dec 1;40(12):1941-1.
26. Russeng SS, Salmah AU, Saleh LM, Achmad H, Rosanita ANR. (2020). The Influence of Workload, Body Mass Index (BMI), Duration of Work toward Fatigue of Nurses in Dr. M. Haulussy General Hospital Ambon. *Sys Rev Pharm*; 11(4): 288 292.

The Importance of Ultrasound Findings in Children with Acute Abdominal Pain to Prevent Unnecessary Surgery

ORIGINALITY REPORT

19%

SIMILARITY INDEX

9%

INTERNET SOURCES

14%

PUBLICATIONS

9%

STUDENT PAPERS

PRIMARY SOURCES

1	Falahi, Gholamhosein, Farahmand, Fatemeh, Khodadad, Ahmad, Mohsenipour, Reihaneh, Motamed, Farzaneh, Najafi, Mehri, Seifirad, Soroush and Yusefi, Azizolah. "Red Flags of Organic Recurrent Abdominal Pain in Children: Study on 100 Subjects", Tehran University of Medical Sciences Press, 2013. Publication	2%
2	Submitted to Suan Sunandha Rajabhat University Student Paper	2%
3	www.aium.org Internet Source	2%
4	Textbook of Clinical Pediatrics, 2012. Publication	1%
5	www.ncbi.nlm.nih.gov Internet Source	1%
6	staging.mja.com.au Internet Source	1%

-
- 7 www.coursehero.com 1%
- Internet Source
-
- 8 Artur Bijoś. "The usefulness of ultrasound examination of the bowel as a method of assessment of functional chronic constipation in children", *Pediatric Radiology*, 11/14/2007 1%
- Publication
-
- 9 Stefan Puig, Marcus Hörmann, Winfried Rebhandl, Rosemarie Felder-Puig, Mathias Prokop, Kurosh Paya. "US as a Primary Diagnostic Tool in Relation to Negative Appendectomy: Six Years Experience", *Radiology*, 2003 1%
- Publication
-
- 10 www.ajronline.org 1%
- Internet Source
-
- 11 www.isca.in 1%
- Internet Source
-
- 12 Aminuddin Prahatama Putra, Muslimin Ibrahim, Huldani Huldani, Bayu Indra Sukmana, Fauziah Fauziah, Harun Achmad. "Are There Levels of Students Morales? The Effects of Biological Problem Solving on Moral Development", *International Education Studies*, 2020 1%
- Publication
-
- 13 Submitted to Universitas Katolik Indonesia Atma

Jaya
Student Paper

1%

14

Leann E. Linam, Martha Munden. "Sonography as the First Line of Evaluation in Children With Suspected Acute Appendicitis", Journal of Ultrasound in Medicine, 2012

Publication

<1%

15

"Imaging of Acute Appendicitis in Adults and Children", Springer Science and Business Media LLC, 2012

Publication

<1%

16

Schmidt, Guenter. "Introduction", Differential Diagnosis in Ultrasound Imaging, 2006.

Publication

<1%

17

Submitted to Rutgers University, New Brunswick

Student Paper

<1%

18

Submitted to Lambung Mangkurat University

Student Paper

<1%

19

"Abstracts", Journal of Anatomy, 2020

Publication

<1%

20

Submitted to Academic Library Consortium

Student Paper

<1%

21

Submitted to Central Queensland University

Student Paper

<1%

Narjes Morovati Moez, Rasoul Yousefi Mashouf,

22 Iraj Sedighi, Leili Shokoohizadeh, Mohammad Taheri. "Phylogroup classification and investigation the relationships between phylogroups and antibiotic resistance patterns of uropathogenic E. coli isolated from pediatric urinary tract infection", Gene Reports, 2020
Publication <1%

23 www.myhealth.gov.my
Internet Source <1%

24 Herlina Uinarni, Felicia Nike. "Duplication of ureter in a 7-year-old: a case report", Radiology Case Reports, 2020
Publication <1%

25 oapub.org
Internet Source <1%

26 hkjpaed.org
Internet Source <1%

27 emedicine.medscape.com
Internet Source <1%

28 www.tandfonline.com
Internet Source <1%

29 "Evidence-Based Emergency Imaging", Springer Science and Business Media LLC, 2018
Publication <1%

30 idoc.pub
Internet Source <1%

31

Submitted to University of Liverpool

Student Paper

<1%

32

A. Rokitansky. "Invited commentary to: "Is diagnostic laparoscopy in children with recurrent abdominal pain justified?"", European Surgery, 1998

Publication

<1%

33

Submitted to Turun yliopisto

Student Paper

<1%

34

Learning Imaging, 2011.

Publication

<1%

35

Submitted to King's College

Student Paper

<1%

36

"Textbook of Clinical Pediatrics", Springer Science and Business Media LLC, 2012

Publication

<1%

Exclude quotes

Off

Exclude matches

Off

Exclude bibliography

On

The Importance of Ultrasound Findings in Children with Acute Abdominal Pain to Prevent Unnecessary Surgery

GRADEMARK REPORT

FINAL GRADE

/100

GENERAL COMMENTS

Instructor

PAGE 1

PAGE 2

PAGE 3

PAGE 4

PAGE 5

PAGE 6

PAGE 7
