

Mast Cell Essential Roles: Will it be a Novel Tool for Differentiating the Severity of Pediatric Appendicitis?

by Hery Poerwosusanta Dkk

Submission date: 22-Jun-2022 11:17PM (UTC+0700)

Submission ID: 1861372373

File name: I_for_Differentiating_the_Severity_of_Pediatric_Appendicitis.pdf (1,009.67K)

Word count: 3573

Character count: 20636



Mast Cell Essential Roles: Will it be a Novel Tool for Differentiating the Severity of Pediatric Appendicitis?

Hery Poerwosusanta^{1*}, Gunadi Gunadi², Pricilia Gunawan³, Aditya Rifqi Fauzi², Angga Setya Budi⁴, Adam Rahardyan Poerwosusanta⁵, Elvira Esmeralda Poerwosusanta⁵, Donny Aditia⁶, Ika Kustiyah Oktavianti⁶, Nia Kania⁶, Zairin Noor¹

¹Department of Surgery, Faculty of Medicine, Universitas Lambung Mangkurat, Banjarmasin, South Kalimantan, Indonesia; ²Department of Surgery, Faculty of Medicine, Public Health and Nursing, Universitas Gajah Mada, Dr. Sardjito Hospital, Yogyakarta, Indonesia; ³Department of Pediatric, Faculty of Medicine, Universitas Lambung Mangkurat, Banjarmasin, Indonesia; ⁴Department of Emergency, Siaga Agung Islam Hospital, Banjarmasin, South Kalimantan, Indonesia; ⁵Department of Emergency, Siaga Surgical Hospital, Banjarmasin, South Kalimantan, Indonesia; ⁶Department of Anatomical Pathology, Faculty of Medicine, Universitas Lambung Mangkurat, Banjarmasin, Indonesia

Abstract

Edited by: Slavica Hristomanova-Mikovska
Citation: Poerwosusanta H, Gunadi G, Gunawan P, Fauzi AR, Budi AS, Poerwosusanta AR, Poerwosusanta EE, Aditia D, Oktavianti IK, Kania N, Noor Z. Mast Cell Essential Roles: Will it be a Novel Tool for Differentiating the Severity of Pediatric Appendicitis? *Open Access Macedonian J Med Sci*. 2022 Apr 27; 10(A):812-816. <https://doi.org/10.3889/oamjms.2022.8597>
Keywords: Appendicitis; mast cell; total leukocyte; Leukocyte profile; Neutrophil-lymphocyte ratio; Platelet-to-lymphocyte ratio (TLR); thrombocyte-to-neutrophil ratio (TNR); Alvarado score
***Correspondence:** Hery Poerwosusanta, Department of Surgery, Faculty of Medicine, Universitas Lambung Mangkurat, Banjarmasin, South Kalimantan, Indonesia. E-mail: hpoerwo@ulm.ac.id
Received: 11-Jan-2022
Revised: 03-Feb-2022
Accepted: 17-Apr-2022
Copyright: © 2022 Hery Poerwosusanta, Gunadi Gunadi, Pricilia Gunawan, Aditya Rifqi Fauzi, Angga Setya Budi, Adam Rahardyan Poerwosusanta, Elvira Esmeralda Poerwosusanta, Donny Aditia, Ika Kustiyah Oktavianti, Nia Kania, Zairin Noor
Funding: This research did not receive any financial support
Competing Interest: The authors have declared that no competing interest exists
Open Access: This is an open-access article distributed under the terms of the Creative Commons Attribution-NonCommercial 4.0 International License (CC BY-NC 4.0)

BACKGROUND: Appendicitis is an undesirable diagnosis, and the Alvarado score (AS) alone is insufficient in recognizing it. Many novel laboratory indicators, such as leukocytes and mast cells, differentiate.

AIM: Our objective was to demonstrate that mast cells had a greater influence on appendicitis severity than the AS, neutrophils, and platelets.

MATERIALS AND METHODS: An observational research in which 35 individuals with acute appendicitis at our institutions were identified for the appendix grade and allocated to one of two groups: Complicated or non-complicated. The AS and white blood cell count were calculated using the neutrophil-lymphocyte ratio (NLR), platelet-to-lymphocyte ratio (PLR), thrombocyte-to-neutrophil ratio (TNR), and total leukocyte. Mast cell count and granulation are evaluated using pathological anatomy.

RESULTS: TLR could not distinguish between severe appendicitis and others, but some showed potential. NLR, TNR, total leukocyte, ASs, mast cell count, and degranulation demonstrated good sensitivity-specificity values.

CONCLUSIONS: Mast cells have the potential to become a promising approach for predicting complicated pediatric appendicitis.

Introduction

Acute appendicitis is frequent in children and adolescents [1]. The exact pathophysiology of appendicitis is unclear, however, it may develop if not properly identified. Appendectomy [2] and histological examination [3] are now the most common procedures, particularly among the young.

The Alvarado score (AS) is a screening test for acute appendicitis, which may cause serious morbidity if not detected early. However, AS is inadequately sensitive to diagnose appendicitis, resulting in unnecessary surgery or misdiagnosis [4]. Although appendix ultrasonography has high accuracy, there are still issues and limits for detecting uncomplicated appendicitis [5], and it has a relatively poor negative predictive value

[6]. The neutrophil profile has been widely examined in appendicitis; however, the primary role determinants in the neutrophil ratio have never been addressed.

Although the mechanisms are uncertain, increased mast cells are responsible for initiating neutrophil and lymphocyte infiltration in the appendicitis immune response [7], [8], [9]. As a result, we sought to demonstrate the importance of mast cells over the AS, neutrophils, and platelets in the severity of appendicitis.

Material and Methods

Patients with uncomplicated and complicated appendicitis who were not identified to be comorbid,

aged 0–18 years, consented to be research participants in the study at Ulin Hospital, Banjarmasin, Indonesia, from August to December 2020. To calculate the minimum samples for each group, the formula for a two-sided continuous result [10] is used:

$$n = \left(\frac{(Z_{\alpha} + Z_{\beta})}{0.5 \ln \left(\frac{1+r}{1-r} \right)} \right)^2 + 3 = \left(\frac{1.64 + 0.84}{0.5 \ln \left(\frac{1+0.6}{1-0.6} \right)} \right)^2 + 3 = 15.8 = 16$$

Uncomplicated appendicitis, also known as 1st grade appendicitis, is characterized as inflamed appendix (simple), <10,000 leukocytes, and no fever. The lower right abdominal pain with localized/generalized peritonitis, leukocytes >10,000, and fever are all symptoms of complicated appendicitis, which can be classified as second grade (gangrenous), third grade (ruptured with localized free fluid), fourth grade (perforated with a regional abscess), and fifth grade (perforated with diffused peritonitis) (Figure 1) [11].

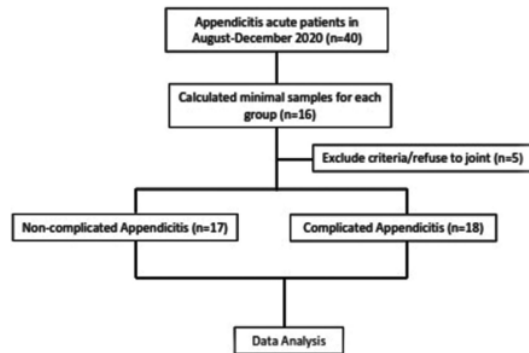


Figure 1: Research step of the 40 patients, 35 were willing to be research subjects, 17 were non-complicated, and 18 had complicated appendicitis

The leukocytes, differential count, neutrophil-to-leukocyte ratio, platelet-to-leukocyte ratio, platelet-to-neutrophil ratio, and leukocyte count profile were measured using venous blood for surgery preparation. According to Gomes *et al.*, the patient was classified into five stages of appendicitis after surgery, and pathological examinations were performed to quantify the quantity and degranulation of mast cells in the mesoappendix, stained with toluidine blue, and assessed by two blinded pathologists [12].

The first grade of appendicitis is characterized as uncomplicated appendicitis, whereas the subsequent grades are classified as complicated appendicitis, resulting in two classes that are analyzed using unpaired independent t-test statistic methods. The averages and standard deviations of data acquired from total leukocyte and mast cell count investigations will be examined. Sensitivity and specificity for each variable were computed for each data set.

The primary variables, total leukocyte, TNR, TLR, NLR, and mast cell degranulation and count are investigated using the spearman rho correlation to see whether they are involved in challenging, complicated, or uncomplicated appendicitis. The outcome of linear regression stated as a coefficient will demonstrate either a strong or mild influence on appendicitis, which was previously categorized into two categories.

This research was authorized by the Institutional Review Board of Universitas Lambung Mangkurat, Banjarmasin, Indonesia (No. 265/KEPK.FK ULM/EC/VIII/2020).

Results

This research involved 40 participants with pathologist confirmed acute appendicitis, five of whom were left out due to their reluctance to participate. Seventeen of the 35 individuals had uncomplicated appendicitis, which was paired with 18 patients in the complicated appendicitis group.

The patients' average age is 7.25 years, with the majority being between the ages of 1 and 17. There has never been a case of complicated appendicitis in a child under the age of 1 year (Table 1).

Table 1: Primary characteristic data of the patient

Variable	Uncomplicated appendicitis (n = 17) N,%	Complicated appendicitis (n = 18) N,%	p-value
Gender			
Male	9 (52.94)	15 (83.33)	0.46
Female	8 (47.06)	3 (16.67)	0.12
Age (years)			
≤1	4 (23.53)	0 (0)	NA
1–17	8 (47.06)	11 (61.11)	
>17	5 (29.41)	7 (38.89)	
Appendicitis grade			
1 st grade	17 (100)	0	NA
2 nd grade	0	3 (16.67)	
3 rd grade	0	8 (44.44)	
4 th grade	0	5 (27.78)	
5 th grade	0	2 (11.11)	

*p-value considered significant if p<0.05.

To obtain the mean and standard deviation of data, total leukocyte, TNR, TLR, and NLR leukocyte profiles were studied; thus, it was analyzed using an unpaired independent T-test, which was then tested for sensitivity and specificity for two classes differences, resulting in the analysis of a receiver operating characteristic (ROC) curve.

There are no significant variations across TLR classes in ROC curve analysis, and the lowest sensitivity and specificity are 61.1% and 58.8%, respectively. While the mast cell profile differs significantly between the two groups, the distinction between complicated and uncomplicated appendicitis is clear (Table 2).

Except for TNR, which has a negative correlation, the Spearman rho test shows that other

Table 2: Significance and single ROC analysis identifying sensitivity and specificity of the test alone

Variable	Appendicitis non-complicated (n = 17)	Appendicitis complicated (n = 18)	Significance* (p)	ROC analysis
Leukocyte profile	Mean ± SD	Mean ± SD		
Leukocyte count	9.582.35 ± 2.350.59	18.627.8 ± 5.195.56	0.000	Sensitivity 88.9% Specificity 88.2%
Thrombocyte-to-neutrophil ratio (TNR)	103.17 ± 55.11	26.8 ± 15.24	0.000	Sensitivity 94.1% Specificity 94.4%
Thrombocyte-to-lymphocyte ratio (TLR)	263.65 ± 225.20	280.7 ± 145.83	0.350	Sensitivity 61.1% Specificity 58.8%
Neutrophil-to-lymphocyte ratio (NLR)	4.43 ± 5.51	12.6 ± 7.18	0.000	Sensitivity 77.8% Specificity 76.5%
Mast cell profile				
Total mast cells (cells/100 µm ²)	1.14 ± 1.01	7.1 ± 2.58	0.000	Sensitivity 100% Specificity 100%
Mast cells degranulation (%)	1 ± 2.24	31.3 ± 8.6	0.007	Sensitivity 100% Specificity 100%
Alvarado score	4.53 ± 2.40	8.5 ± 0.86	0.000	Sensitivity 88.9% Specificity 94.1%

*Analysis was done using independent t-test. *p-value considered significant if p<0.05.

indications indicate a complex appendicitis diagnosis. It implies that when the TNR is higher, individuals are more likely to get uncomplicated appendicitis [13] rather than complicated appendicitis. Of strength, total leukocyte, NLR, and TLR are three additional leukocyte profiles that might signal the chance of complicated appendicitis. Mast cell profiles, such as mast cell count and granulation, have been associated with complicated appendicitis and the AS (Table 3).

Table 3: Analysis of the variable effect on diagnosing complicated/uncomplicated appendicitis

Variable	Spearman rho correlation		Linear regression	
	(r)	p-value	β coefficient	p-value
Inflammation response				0.000
Leukocyte profile				0.000
Leukocyte count	0.759	0.000	0.753	0.000
Thrombocyte-to-neutrophil ratio (TNR)	-0.741	0.000	-0.702	0.000
Thrombocyte-to-lymphocyte ratio (TLR)	0.175	0.313	0.046	0.791
Neutrophil-to-lymphocyte ratio (NLR)	0.671	0.000	0.547	0.001
Mast cell profile				0.000
Total mast cells (cells/100 µm ²)	0.870	0.000	0.839	0.000
Mast cells degranulation (%)	0.895	0.000	0.926	0.000
Alvarado score	0.690	0.000	0.754	0.000

In the linear regression, excluding TLR, all factors that strongly correlate to complicated appendicitis are shown in Figure 2. Mast cell profile can be seen in Figure 3.

Discussion

The most prevalent causes of juvenile appendicitis are fecalith blockage [14] and bacterial hematological spread [15]. Obstruction causes dilatation, which promotes bacterial growth in the appendix lumen, resulting in ischemia and necrosis of the appendix wall. Bacterial growth and necrotic tissue reduce the inflammatory response. Pathological samples from one instance of appendicitis in infants under 1 year old were obtained from incidental appendicitis connected to the last operation for Hirschsprung disease. Acute appendicitis in children under the age of 1 year is rare, difficult to diagnose, and lacks typical symptoms. Rotavirus infection, the most prevalent cause of enterocolitis, has been shown to have no connection to the development of appendicitis [16]. Because of easy communication and a variety of low-fiber diets, older children are more likely to be detected with appendicitis [17], [18]. The inflammatory response

is a well-coordinated mechanism that eliminates germs and dead tissue.

All innate and adaptive immune response cells are involved in controlling the elimination process. The cells work in tandem on the inflammatory response, with polymorphonuclear (PMNs) dominating initially, followed by macrophages and mast cells. Mast cells have two phases of function: Early and late. Mast cells live for 30 days. Cells produce cytokines, chemokines, and vasoactive chemicals in an autocrine, paracrine, and endocrine way to impact the inflammatory response. Mast cells, which are produced in the bone marrow and contain a large number of cytoplasmic granules [19], are engaged in the inflammatory response that kills pathogens. Mast cells possess a large number of receptors for cytokine activation; hence, they play an essential role in the amplification and resolution of inflammation. Mast cells also function in innate and adaptive immunity as mediators of cell populations and germ eradication. In the early stages of inflammation, mast cells influence neutrophil activation by identifying pathogen-associated molecular patterns (PAMPs) through pattern recognition receptors (PRRs) as part of toll-like receptors (TLRs) and nucleotide-binding oligomerization domain (NOD)-like receptors (NLRs) [20]. Mast cells degranulate in response to bacterial toxins, antimicrobial peptides, complement proteins, and Fc receptor stimulation. Mast cells generate histamine, proteases, TNF-, *de novo* lipid mediator synthesis, and the transcription and release of antimicrobial and immunomodulatory cytokines and chemokines during degranulation. Mast cells' position in tissues surrounding blood arteries and nerves, the host's external environment interface, and first contact with the pathogen [21] implies an early role in bacterial elimination. Histamine-producing mast cell degranulation causes vasodilation, which promotes chemotaxis and bacterial phagocytosis. TLR activation in the lipopolysaccharide membrane lowers the calcium influx threshold, allowing mast cells to degranulate and release cytokines [20]. The results of mast cell-t-cell crosstalk aid in regulating the inflammatory response. When mast cells degranulate, TNF production through the lymphotoxin receptor (LT-R) stimulates CD4+ T cells and releases IL-4 and IL-6. Mast cells activate CD8+ T lymphocytes through MHC Class I, resulting in more effective phagocytosis [22]. The appendix is a lymphoid organ

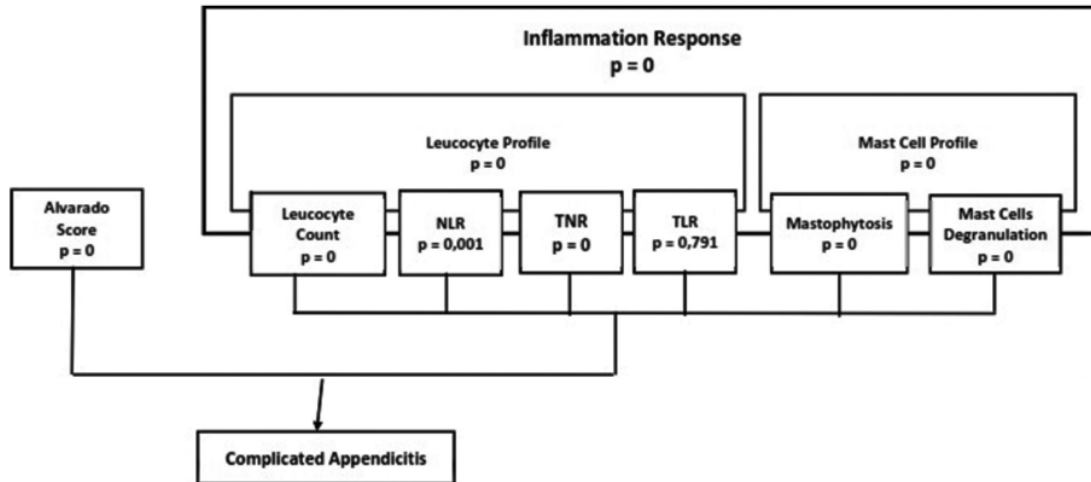


Figure 2: Statistical analysis of dummy variable linear regression. All factors, excluding TLR, have strongly correlated to complicated appendicitis

with a well-developed inflammatory response system that includes lymphocytes and other cells, most notably mast cells.

When an infection progresses to a severe, systemic level, relative thrombocytopenia develops due to decreased platelet synthesis, hemodilution, platelet consumption, sequestration in microvessels, and immune-mediated destruction. TNR is associated with vascular permeability [23], [24], while leukocyte count provides a complete picture of inflammatory leukocyte orchestral variables. In severe infections, lymphocytes employ nitric oxide (NO) to inhibit platelet aggregation [25]. Unlike Ceylan *et al.* [26], the TNR was insignificant, suggesting that the patients with complicated appendicitis were not seriously ill.

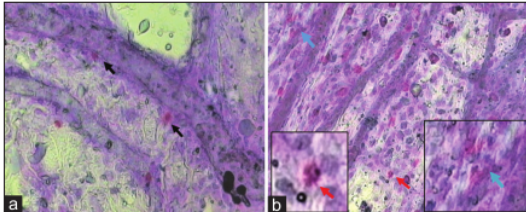


Figure 3: Mast cells profile. (a) From the omentum of an uncomplicated appendix and the mast cells are perivascular, intact with the nucleus and purplish (black arrow). (b) Omentum complicated appendix shows an increase in the number (red arrow) and mast cell degranulation (blue arrow)

The AS in uncomplicated appendicitis was 4.532.40 (the lowest score was two and the highest score was seven), which was consistent with the previous study [4], and the pathological diagnosis was acute appendicitis. This shows that the AS can distinguish between simple and complicated appendicitis and may be used as a therapeutic signal in uncomplicated appendicitis. The AS contains components for leukocyte count and neutrophilia (shift

to the left), signaling that further scoring components (mast cell profile) are needed to increase diagnosis accuracy in uncomplicated appendicitis.

Conclusions

20 Mast cells play an essential role in the immune system because they work with innate and adaptive immune cells. Because of their excellent specificity and sensitivity, mast cells are a one-of-a-kind approach for discriminating between simple and complex appendicitis. Mast cell samples can only be collected after surgery, while what is necessary is completed before surgery. Pre-operative histamine levels as a mast cell product will be studied more in the future.

References

- Boshnak N, Boshnaq M, Elgohary H. Evaluation of platelet indices and red cell distribution width as new biomarkers for the diagnosis of acute appendicitis. *J Investig Surg.* 2018;31(2):121-9. <https://doi.org/10.1080/08941939.2017.1284964> PMID:28635513
- Kong VY, Sartorius B, Clarke DL. Acute appendicitis in the developing world is a morbid disease. *Ann R Coll Surg Engl.* 2015;97(5):390-5. <https://doi.org/10.1308/003588415x14181254790608> PMID:26264094
- Swank HA, Eshuis EJ, Ubbink DT, Bemelman WA. Is routine histopathological examination of appendectomy specimens useful? A systematic review of the literature. *Colorectal Dis.* 2011;13(11):1214-21. <https://doi.org/10.1111/j.1463-1318.2010.02457.x>

- PMid:20958910
4. Singla A, Singla S, Singh M, Singla D. A comparison between modified Alvarado score and RIPASA score in the diagnosis of acute appendicitis. *Updates Surg.* 2016;68(4):351-5. <https://doi.org/10.1007/s13304-016-0381-0>
PMid:27338243
 5. Pedram A, Asadian F, Roshan N. Diagnostic accuracy of abdominal ultrasonography in pediatric acute appendicitis. *Bull Emerg Trauma.* 2019;7(3):278-83. <https://doi.org/10.29252/beat-070311>
PMid:31392228
 6. Hosseini A, Omidian J, Nazarzadeh R. Investigating diagnostic value of ultrasonography in acute appendicitis. *Adv Biomed Res.* 2018;7(1):113. https://doi.org/10.4103/abr.abr_79_18
PMid:30123787
 7. Katkar R, Choudhary S, Singh N. Role of mast cells in surgically resected specimens of appendices. *Indian J Pathol Oncol.* 2018;5(4):667-70. <https://doi.org/10.18231/2394-6792.2018.0127>
 8. Yang Z, Esebua M, Layfield L. The role of mast cells in histologically "normal" appendices following emergency appendectomy in pediatric patients. *Ann Diagn Pathol.* 2016;24:1-3. <https://doi.org/10.1016/j.anndiagpath.2016.06.003>
PMid:27649944
 9. Chittawadgi BB, Mhetre SC, Chittawadgi BB. A morphometric analysis of diameter of blood vessels in relation to degree of eosinophils and basophils (mast cells) infiltration for analysis of severity and prognosis of acute appendicitis. *Indian J Pathol Oncol.* 2016;3(3):463-9. <https://doi.org/10.5958/2394-6792.2016.00087.9>
 10. Vishwakarma G. In: Sami T, Sedgwick P, editors. *Sample Size and Power Calculation.* Singapore: Singapore Press Holdings Limited; 2017. p. 234-46.
 11. Gomes CA, Sartelli M, Di Saverio S, Ansaloni L, Catena F, Coccolini F, *et al.* Acute appendicitis: Proposal of a new comprehensive grading system based on clinical, imaging and laparoscopic findings. *World J Emerg Surg.* 2015;10(1):1-6. <https://doi.org/10.1186/s13017-015-0053-2>
PMid:26640515
 12. Ribatti D. The staining of mast cells: A historical overview. *Int Arch Allergy Immunol.* 2018;176(1):55-60. <https://doi.org/10.1159/000487538>
PMid:29597213
 13. Anuradha GP, Anita AM, Seemant SK, Pratima S. Mast cell profile in appendicitis. *Indian J Pathol Oncol.* 2017;4(4):555-9.
 14. Pisano M, Capponi MG, Ansaloni L. Acute appendicitis: An open issue. Current trends in diagnostic and therapeutic options. In: *Microbiology for Surgical Infections: Diagnosis, Prognosis and Treatment.* Netherlands: Elsevier Inc.; 2014. p. 97-110. <https://doi.org/10.1016/b978-0-12-411629-0.00006-4>
 15. do Nascimento Junior PL, Brandt CT, Petroianu A. Differences between inflamed and non-inflamed appendices diagnosed as acute appendicitis. *Ann Med Surg.* 2021;62:135-9. <https://doi.org/10.1016/j.amsu.2021.01.044>
PMid:33520210
 16. Koehler RL, Phillips R, Diaz-Miron J. Acute appendicitis and rotavirus infection in an infant. *J Pediatr Surg Case Rep.* 2020;57:101453. <https://doi.org/10.1016/j.epsc.2020.101453>
 17. Damanik B, Fikri E, Nasution IP. Relation between fiber diet and appendicitis incidence in children at H. Adam malik central hospital, Medan, North Sumatra-Indonesia. *Bali Med J.* 2016;5(2):84. <https://doi.org/10.15562/bmj.v5i2.225>
 18. AlHarmi RA, Almahari SA, AlAradi J, Alqaseer A, AlJirdabi NS, Ahmed FA. Seasonal variation in cases of acute appendicitis. *Surg Res Pract.* 2021;2021:1-5. <https://doi.org/10.1155/2021/8811898>
 19. Gurish MF, Austen KF. Developmental origin and functional specialization of mast cell subsets. *Immunity.* 2012;37(1):25-33. <https://doi.org/10.1016/j.immuni.2012.07.003>
PMid:22840841
 20. Elieh Ali Komi D, Wöhrl S, Bielory L. Mast cell biology at molecular level: A comprehensive review. *Clin Rev Allergy Immunol.* 2020;58(3):342-65. <https://doi.org/10.1007/s12016-019-08769-2>
PMid:31828527
 21. Pundir P, Liu R, Vasavda C, Serhan N, Limjunyawong N, Yee R, *et al.* A connective tissue mast-cell-specific receptor detects bacterial quorum-sensing molecules and mediates antibacterial immunity. *Cell Host Microbe.* 2019;26(1):114-22. <https://doi.org/10.1016/j.chom.2019.06.003>
PMid:31278040
 22. Gri G, Frossi B, D'Inca F, Danelli L, Betto E, Mion F, *et al.* Mast cell: An emerging partner in immune interaction. *Front Immunol.* 2012;3:120. <https://doi.org/10.3389/fimmu.2012.00120>
PMid:22654879
 23. Chaudhary N, Raju K, Kamarthi P. Profile of platelet parameters in coronavirus disease-positive cases-an observational study. *Biomed Res Ther.* 2021;8(10):4649-54. <https://doi.org/10.15419/bmrat.v8i10.700>
 24. Djordjevic D, Rondovic G, Surbatovic M, Stanojevic I, Udovicic I, Andjelic T, *et al.* Neutrophil-to-lymphocyte ratio, monocyte-to-lymphocyte ratio, platelet-to-lymphocyte ratio, and mean platelet volume-to-platelet count ratio as biomarkers in critically ill and injured patients: Which ratio to choose to predict outcome and nature of bacteremia? *Mediators Inflamm.* 2018;2018:3758068. <https://doi.org/10.1155/2018/3758068>
PMid:30116146
 25. Foley JH, Conway EM. Cross talk pathways between coagulation and inflammation. *Circulation Res.* 2016;118(9):1392-408. <https://doi.org/10.1161/circresaha.116.306853>
PMid:27126649
 26. Ceylan B, Aslan T, Çınar A, Kurt AR, Akkoyunlu Y. Can platelet indices be used as predictors of complication in subjects with appendicitis? *Wien Klin Wochenschr.* 2016;128(8):620-5. <https://doi.org/10.1007/s00508-015-0760-4>
PMid:25869761

Mast Cell Essential Roles: Will it be a Novel Tool for Differentiating the Severity of Pediatric Appendicitis?

ORIGINALITY REPORT

14%

SIMILARITY INDEX

11%

INTERNET SOURCES

11%

PUBLICATIONS

4%

STUDENT PAPERS

PRIMARY SOURCES

1	eprints.ugd.edu.mk Internet Source	2%
2	bmcsurg.biomedcentral.com Internet Source	1%
3	www.ijirms.in Internet Source	1%
4	Anna Lyakhovitsky, Joel Dascalu, Theodoulos Drousiotis, Aviv Barzilai, Sharon Baum. "Hematological Inflammatory Markers in Patients with Pemphigus Vulgaris", <i>Dermatology</i> , 2021 Publication	1%
5	www.hindawi.com Internet Source	1%
6	worldwidescience.org Internet Source	1%
7	Natalia Cybulska, Tomasz Łopaciński, Mariusz Sieminski. "Efficient Organization of The Diagnostic Process In The Emergency	1%

Department of Patients With Acute
Appendicitis During The COVID-19 Pandemic",
Research Square Platform LLC, 2021

Publication

8	Argul Issilbayeva, Almagul Kushugulova, Assel Meiramova, Samat Kozhakhmetov et al. "Epidemiological Trends of Rheumatoid Arthritis and PADI4, PTPN22, and HLA-DRB9 Genes Distribution in the Kazakhstan Population", Open Access Macedonian Journal of Medical Sciences, 2021 Publication	1 %
9	aip.scitation.org Internet Source	<1 %
10	koreascience.kr Internet Source	<1 %
11	app.trdizin.gov.tr Internet Source	<1 %
12	www.pubfacts.com Internet Source	<1 %
13	www.iosrjournals.org Internet Source	<1 %
14	doaj.org Internet Source	<1 %
15	Harapan Parlindungan Ringoringo. "Parapagus dicephalus conjoined twins with	<1 %

tribrachius and a single heart – A scarce variant of conjoined twins: A case report",
Human Pathology: Case Reports, 2021

Publication

16

Submitted to Universitas Airlangga

Student Paper

<1 %

17

bouldenpublishing.com

Internet Source

<1 %

18

www.land-care.org.uk

Internet Source

<1 %

19

Luciana P. Tavares, Hong Yong Peh, Wan Shun Daniel Tan, Hadas Pahima et al.

"Granulocyte-targeted therapies for airway diseases", Pharmacological Research, 2020

Publication

<1 %

20

Steven Willows, Marianna Kulka. "Harnessing the Power of Mast Cells in unconventional Immunotherapy Strategies and Vaccine Adjuvants", Cells, 2020

Publication

<1 %

21

Zhongbo Yang, Magda Esebua, Lester Layfield. "The role of mast cells in histologically "normal" appendices following emergency appendectomy in pediatric patients", Annals of Diagnostic Pathology, 2016

Publication

<1 %

22

bmcoralhealth.biomedcentral.com

Internet Source

<1 %

23

issuu.com

Internet Source

<1 %

24

researchoutput.csu.edu.au

Internet Source

<1 %

25

ris.utwente.nl

Internet Source

<1 %

26

www.science.gov

Internet Source

<1 %

27

Koichi Maeda, Toru Kuratani, Daisuke Yoshioka, Kyongsun Pak, Kazuo Shimamura, Koichi Toda, Yoshiki Sawa. "Predicting patient-prosthetic mismatch by aortic root evaluation before aortic valve replacement", *The Journal of Thoracic and Cardiovascular Surgery*, 2018

Publication

<1 %

28

Eman Moawad Elhabashi, Reham Farouk Tawfik, Fatma Maamoun Abou-Hashima, Arwa Mohamed El Shafei, Fayrouz El-Aguizy. "Preparedness Assessment of Physicians during Coronavirus Disease-19 Pandemic: A Cross-sectional Study", *Open Access Macedonian Journal of Medical Sciences*, 2021

Publication

<1 %

Exclude quotes On

Exclude matches Off

Exclude bibliography On