

Research Article

A Rare Case: Spontaneous Omental Bleeding After Tenckhoff Catheter Placement

MOHAMMAD RUDIANSYAH¹, RUDI SUPRIYADI², RIA BANDIARA², RULLY MARSIS AMIRULLAH ROESLI²

¹Division of Nephrology & Hypertension, Department of Internal Medicine, Faculty of Medicine, Universitas Lambung Mangkurat/Ulin Hospital Banjarmasin, Indonesia

²Division of Nephrology & Hypertension, Department of Internal Medicine, Faculty of Medicine, Universitas Padjadjaran/Hasan Sadikin Hospital Bandung, Indonesia

*Corresponding Author

Email ID: rudiansyah@ulm.ac.id

Received: 08.11.20, Revised: 08.12.20, Accepted: 17.01.21

ABSTRACT

Omental bleeding may occur due to the rupture of an omental blood vessel. Some case associated with trauma, neoplasms, omental torsion, varicose veins, aneurysms, and vasculitis. A case of 27 years old female with nephritis lupus, hypertension, and end-stage kidney disease on routine hemodialysis who came up to Tenckhoff Catheter placement for continuous ambulatory peritoneal dialysis with Bandung technique. She was diagnosed with lupus for 11 years. She got omental bleeding after Tenckhoff catheter placement. This patient had no signs of trauma, vascular injury, or hematoma after an exploratory laparotomy to find the cause and source of bleeding.

Keywords: omental bleeding, tenckhoff catheter, peritoneal dialysis, chronic kidney disease, CAPD

INTRODUCTION

Omental bleeding may occur due to the rupture of an omental blood vessel. The first report of omental bleeding occurred at the Montreal General Hospital in 1918.¹ Some case reported omental bleeding has been associated with trauma, neoplasms, omental torsion, varicose veins, aneurysms, and vasculitis. Idiopathic omental bleeding is a potentially life-threatening with acute abdomen as the most common manifestation. Most patients with visceral artery rupture have previous vascular diseases, such as hypertension and arteriosclerosis. The weakness of the tunica media can cause rupture of blood vessels with a sudden increase in pressure.¹⁻³

Hereby, we report a rare case of omental bleeding due to Tenckhoff catheter placement in a chronic kidney disease patient with systemic lupus erythematosus. This patient had no signs of trauma, vascular injury, or hematoma after an exploratory laparotomy to find the cause and source of bleeding. This case never has been reported in Indonesia yet.

Case Report

We presented a case of 27 years old female with nephritis lupus, hypertension, and end-stage kidney disease (ESKD) on routine hemodialysis (HD) who came up to Tenckhoff Catheter placement for continuous ambulatory peritoneal dialysis (CAPD) with Bandung technique. She was diagnosed with lupus for 11 years before

admission. She had a history of cyclophosphamide treatment. She got amlodipine 10 mg, captopril 25 mg for three times a day, folic acid 5 mg one for day, methylprednisolone 20 mg, calcium carbonate 500 mg for three times a day, sodium bicarbonate 500 mg for three times a day, and omeprazole 20 mg for twice a day. She was known as an ESRD survivor with routine regular HD once a week for 2 months before admission.

At admission, she was generally stable; fully alert, blood pressure 160/100 mmHg, pulse 80 times per minute (TPM), respiration 20 TPM with a temperature of 36.5 °C. She looked moon face and pallor. Her belly was soft without ascites. Hemoglobin 8.8 gr/dL, leukocytes 8200/ μ L, Platelets 324,000/ μ L, sodium 138 mEq/L, potassium 3.8 mEq/L, chloride 99 mEq/L, urea 65 mg/dl, creatinine 7.2 mg/dL, random blood sugar 98 mg/dL, SGOT 25 IU/L, SGPT 25 IU/L.

On the first day of treatment, she had no complaints, and on the second day of treatment, she was hemodialyzed. On the third day, the tenckhoff catheter for CAPD was placed on her stomach. The technique of tenckhoff catheter placement used Bandung method; a Seldinger technique with modification. There were no complications during the operation, inflow, and outflow from CAPD was smooth and clear. After procedure she was hemodynamically stable.

One day post-surgery there was blood inside the drain. The drain was flushed with an aqueous solution and 1000 units of heparin, rinsing is carried out for approximately 14 hours but it was still bloody (Figure 1). She was consulted with the urology department and digestive surgery

department. They considered she had peritonitis due to intra-abdominal bleeding. Hemoglobin level was dropped into 3.5 g/dL, PT 15 seconds, and APTT 34 seconds. She was given packed-red cell (PRC) transfusion.

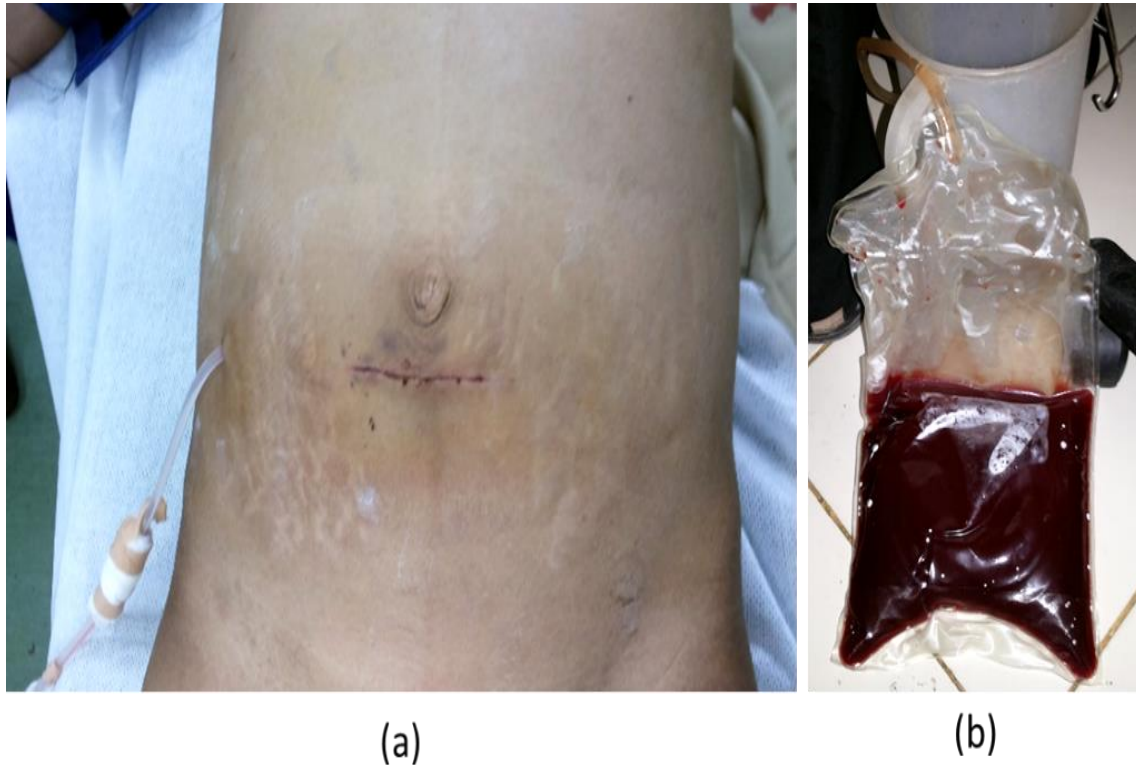


Fig.1: (a) Scar after CAPD catheter placement and (b) hemorrhagic peritoneal fluid

Exploratory laparotomy was done on her by digestive consultant surgeons, and they did not find any tear in the omental or bleeding (Figure 2). There is no hematoma, rupture of vessels blood or vulnus in abdominal wall, omental and intestine. She was planned for fasting in 1 day, normal saline infusion 1000 cc per 24 hours,

amlodipine 10 mg once daily, valsartan 160 mg once daily, clonidine 0.15 mg three times a day, methylprednisolone 20 mg once daily, cefotaxime injection 1 gr twice daily, omeprazole injection 40 mg once daily, Vitamin K injection 1 ampoule every 8 hours, and tranexamic acid injection 250 mg once daily.

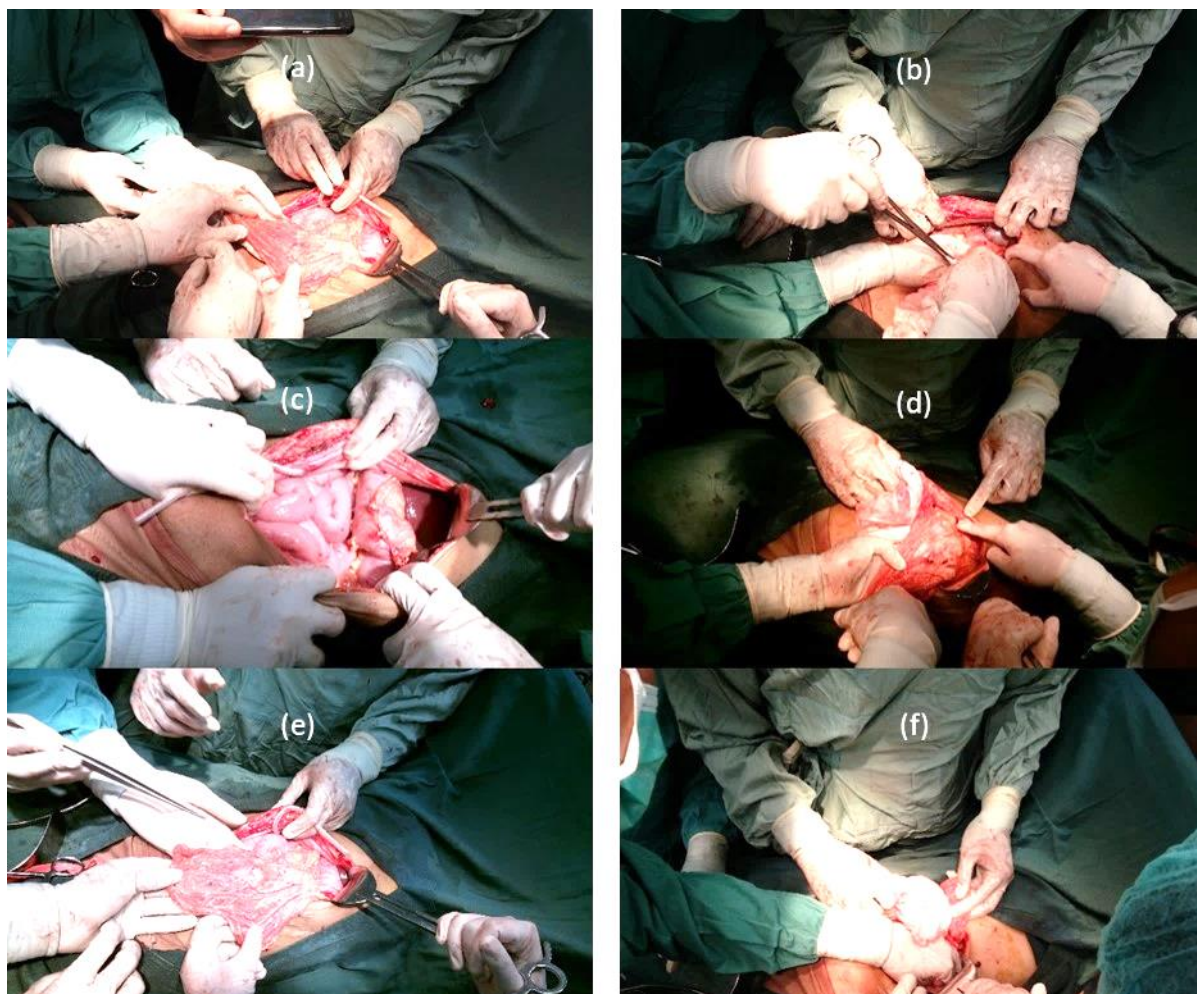


Fig.2: Exploratory laparotomy (a) first incision (b) omental opening (c) bleeding exploration (d) no source of intraabdominal bleeding (e) and omental closure (f) wound closure layer by layer

DISCUSSION

In this case, the patient had been diagnosed with ESKD caused by systemic lupus erythematosus (SLE). SLE is a systemic disease that affects many organs. The level of kidney involvement varies, reaching as high as 60% of the adult SLE population. Nephritis lupus may progress to ESRD within 10-15 years after the initial diagnosis is made in about 10-30% of patients. In this patient, a history of SLE has been diagnosed about 11 years ago. Kidney damage is an important predictor of death in SLE patients. Management of patients with ESKD associated with lupus nephritis requires attention and monitoring of SLE disease activity regularly and continuously.⁴ Prolonged use of immunosuppressant preparations in lupus nephritis patients with severe renal insufficiency remains controversial. In this patient, she used oral methylprednisolone 20 mg each day. Long-term exposure to steroids or cytotoxic drugs in patients with nephritis lupus, has been shown to accelerate the process of atherosclerosis and increase the risk of infectious

complications. The immunosuppressant dose evaluation needs to be reconsidered especially if the patient had ESRD that requires kidney replacement therapy. Currently, promising therapeutic options for the treatment of lupus nephritis are the use of biological drugs such as mycophenolate mofetil (MMF), anti-CD-20, and other biological drugs. But whether the use of these biological preparations will reduce the progression of the disease to end-stage renal failure is not well-established. Although the use of prednisone monotherapy compared to a combination of prednisone and cyclophosphamide or azathioprine can reduce the cumulative incidence of end-stage kidney disease, there are still 20% of patients who experience progression to end-stage renal failure.^{5,6,7} She had undergone routine HD once per week for 2 months. Studies on the survival of lupus nephritis patients with renal replacement therapy have been widely reported. Mojcić et al. suggested that the 5-year survival of lupus patients on dialysis was 80-90% compared to

non-SLE dialysis patients and better than other systemic autoimmune diseases.⁸ In general, clinical and serological disease activity decreases during dialysis, although the level of use of immunosuppressant drugs cannot be reduced.⁶ Patients who progress to rapidly deteriorating kidney function due to progressive lupus nephritis will experience several different things. In 10-20% of patients, kidney function will recover within 4 months which allows cessation of HD, but the rest still requires routine dialysis.^{7,8}

Hemodynamic stability and preservation of residual renal function (RRF) are benefit in the using of peritoneal dialysis (PD), may be performed at home and the cost can be held down. PD uses the peritoneal membrane and dialysate to dispose extra waste and fluid from the body. PD may correct electrolyte and fluid imbalances, also reduces systemic cytokines effects significantly. PD may clear cytokines, including tumor necrosis factor- α (TNF- α), interleukin 1 (IL-1), IL-6, and IL-10.^{2,8,9} In the acute period of SLE should focus for future studies in the relationship between severity, duration, and inflammatory factors.

PD as the renal replacement therapy is a method of adjuvants that treats patients with severe organ dysfunction likely nephritis lupus. Apart from maintaining RRF, PD also improves the nutritional status of patients, and maintain condition and ensure continuation of immunosuppressive therapy in SLE. Besides PD can be a treatment option for patients with severe nephritis lupus and acute kidney injury who require continuous action immunosuppressive therapy.^{4,10,11}

A retrospective multicenter data showed that ESKD patients related to nephritis lupus may survive 5 and 10 years with HD or PD, with a no significant trend toward excess PD.^{10,11} This was independent of the lower technique-related survival rates in the PD group than in the HD group because of the higher incidence of intra-abdominal infection during the 5 to 10 years of follow-up. For patients with immunosuppressive treatment, PD can be considered in avoiding incidents and failures based on the higher technique associated with peritonitis.^{10,11} PD may be better in patients with a history of antiphospholipid antibody syndrome (antiphospholipid syndrome/APLS) for the frequent possibility of access failure vascular in HD.¹²

This patient was planned to switch HD into CAPD. The patient was operated the CAPD Tenckhoff catheter placement using the Seldinger Technique with Bandung modification. During the Tenckhoff catheter placement, the operation went smoothly without any complications and there was no significant bleeding. She was hemodynamically

stable and conscious because she was given local anesthesia only. It has been reported in some literature for the Seldinger Technique with Bandung Modification including its advantages and disadvantages.¹³⁻¹⁵ Advantages of the technique are local anesthesia only, low mortality, shorter training periods so that the need for HD is reduced, lower cost, less tissue trauma, fewer complications such as wrong position infections and longer periods of PD catheter.¹⁶

Abdominal bleeding can be an indication for emergency exploratory laparotomy. This patient was considered an acute abdomen and massive bleeding, hemoglobin level was dropped to 3.5 gr/dL so that open laparotomy was performed to stop the bleeding while looking for the source of bleeding. But no source of bleeding was found. This was most likely due to spontaneous omental bleeding.

Omental bleeding (hemoperitoneum) is abdominal cavity bleeding with various causes and is associated with peritoneal dialysis. The occurrence of omental bleeding or hemoperitoneum was first reported in 1918 at the Montreal General Hospital.¹ The occurrence is quite often around 13% as reported by Miftah et al (2014).¹⁷ The incidence of omental bleeding in CAPD is often associated with various conditions or causes such as trauma, neoplasms, omental torsion,^{18,19} varicose veins, aneurysm,²⁰ and vasculitis²¹ and spontaneous idiopathic.

Omental bleeding is known to occur after penetrating or blunt trauma, including high-speed slowing due to an intraabdominal adhesion. This patient had no such condition. The pathological conditions related to spontaneous bleeding include segmental arterial mediolysis, SLE, Ehlers-Danlos syndrome type IV, fibromuscular dysplasia, hypertension, polycythemia, and Wegener's granulomatosis.^{22,23} This patient had SLE and may be associated with spontaneous bleeding of the omentum,. This condition also explained why there was no source of bleeding when open laparotomy surgery was performed. Besides that, one of the causes of spontaneous omentum bleeding was vasculitis disease where SLE is also included.²¹ Unfortunately in this patient, omentum tissue was not taken for a histopathology examination. Histopathology can help to establish the diagnosis. Patients with vasculitis or autoimmune disease may have focal necrotizing vasculitis in omental venules.²¹

The diagnosis of this case was not optimal because there was no histopathology confirmation. Some literature suggested that SLE can be a trigger for spontaneous omental bleeding. Also, it was still possible that the administration of heparin when a blockage

occurs because blood clots aggravate bleeding. In this case, it was different from that reported by Ahmadi *et al.*, the presence of a large hematoma in the right upper quadrant omentum without active bleeding.²⁴ Whereas in this case there was no hematoma or source of bleeding. Omental bleeding can occur in 3-4% of mechanical complications of peritoneal dialysis

(MCPD).¹⁷ This was considered as a mild complication and not a risk factor for peritonitis or technical failure. Hypertension can also trigger spontaneous omental bleeding, although in this case, the cause was less likely because the patient's blood pressure before, during, and after surgery was no more than 150/100 mmHg.

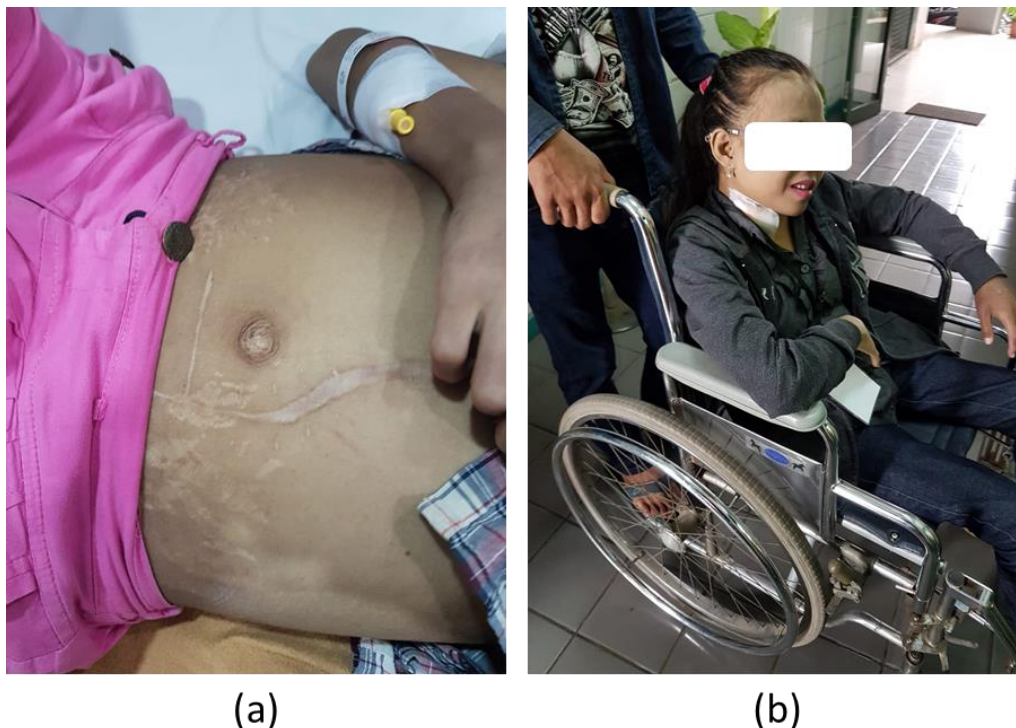


Fig.3: Patient's condition after 1.5 years of surgery (a) the scars and (b) undergoing routine HD

Patient with autoimmune disease may have vasculitis and this condition tend to increase bleeding risk. It should be our concern to prevent and manage spontaneous bleeding. Spontaneous omental bleeding after Tenckhoff catheter placement may occur, and exploratory laparotomy may not find any source of bleeding.

If something like this happens, there's no need to panic. It is necessary to rinse adequately with normal saline and maintain hemoglobin. After 1.5 years of surgery, the patient was in good condition with good scars and undergoing routine HD (Figure 3). Teaching points related to the case can be seen in Table 1.

Table 1: Teaching points

1.	Omental bleeding (hemoperitoneum) is abdominal cavity bleeding with various causes.
2.	The incidence of omental bleeding is often associated with various conditions or causes such as trauma, neoplasms, omental torsion, varicose veins, aneurysm, and vasculitis and spontaneous idiopathic.
3.	It is important to make the appropriate diagnosis to get proper management.

CONSENT

We got written informed consent for publication of this case report from the patient and any accompanying images.

FUNDING

No Financial support was received.

CONFLICT OF INTEREST

The authors declared no conflict of interest.

ACKNOWLEDGMENTS

We thank the patient for allowing us to publish this case report.

AUTHOR CONTRIBUTIONS

MR and RS made the patient's description and drafted the manuscript. MR was the operator. RS, RB, and RMAR gave the critical analysis to the paper. MR, RS and RB made the discussion. All authors read and approved the final manuscript.

REFERENCES

1. Eberts EM. Case of Spontaneous Haemorrhage from the Great Omentum. *Can Med Assoc J*. 1920; 10(5): 461-463.
2. Bettini N, Goueffic Y, Marret O, Heymann MF, Costargent A, Patra P, et al. Hemoperitoneum Due to Rupture of an Omental Arterial Aneurysm. *J Chir (Paris)*. 2007; 144(6): 544-545.
3. Borioni R, Garofalo M, Innocenti P, Fittipaldi D, Tempesta P, Colagrande L, et al. Hemoperitoneum due to spontaneous rupture of an aneurysm of the left gastroepiploic artery. *J Cardiovasc Surg (Torino)*. 1999; 40(1): 63-64.
4. Maroz N, Segal MS. Lupus Nephritis and End-stage Kidney Disease. *Am J Med Sci*. 2013; 346(4): 319-323.
5. Kazatchkine MD, Kaveri S V. Immunomodulation of Autoimmune and Inflammatory Diseases with Intravenous Immune Globulin. Mackay IR, Rosen FS, eds. *N Engl J Med*. 2001; 345(10): 747-755.
6. Rudiansyah M, Lubis L, Bandiara R, Supriyadi R, Afiatin, Gondodiputro RS, et al. Java Barb Fish Gallbladder-Induced Acute Kidney Injury and Ischemic Acute Hepatic Failure. *Kidney Int Reports*. 2020; 5(5): 751-753.
7. Tanaka T, Kishimoto T. Targeting Interleukin-6: All the Way to Treat Autoimmune and Inflammatory Diseases. *Int J Biol Sci*. 2012; 8(9): 1227-1236.
8. Mojciak CF, Kuppel JH. End-stage renal disease and systemic lupus erythematosus. *Am J Med*. 1996; 101(1): 100-107.
9. Rudiansyah M, Lubis L, Bandiara R, Sanjaya BM, Nur'amin HW, Martakusumah AH, et al. The Correlation between Fibroblast Growth Factor 23 (FGF23) and Iron Profile in Chronic Kidney Disease Patients on Dialysis with Anemia. *Sys Rev Pharm*. 2020; 11(6): 780-784.
10. Kang S-H, Chung B-H, Choi S-R, Lee J-Y, Park H-S, Sun I-O, et al. Comparison of Clinical Outcomes by Different Renal Replacement Therapy in Patients with End-Stage Renal Disease Secondary to Lupus Nephritis. *Korean J Intern Med*. 2011; 26(1): 60.
11. Zhou Y, Yu Y, Tang Z, et al. Peritoneal dialysis treatment for severe lupus nephritis patients complicated with essential organ dysfunction. *Experimental And Therapeutic Medicine*. 2015; 10: 2253-2258.
12. Shafi ST, Gupta M. Risk of Vascular access Thrombosis in Patients with Systemic Lupus Erythematosus on Hemodialysis. *J Vasc Access*. 2007; 8(2): 103-108.
13. Supriyadi R. Tenckhoff Catheter Insertion Techniques With the Bandung Method. In: Universitas Padjadjaran, Proceeding Workshop Nefrologi Intervensi & Simposium Dialisis. Bandung; 2015.
14. Rayendra H, Gondodiputro R, Bandiara R, Martakusumah H, Supriyadi R, Afiatin M, et al. A Study of Clinical Profile of Continuous Ambulatory Peritoneal Dialysis Patient with Tenckhoff Catheter Insertion Using Bandung Technique. *Nephrology*. 2015; 20: 64.
15. Jonny, Supriyadi R, Roesli R, Bak Leong G, Hilman LP, Arini FC. A Simple Tenckhoff Catheter Placement Technique for Continuous Ambulatory Peritoneal Dialysis (CAPD) Using the Bandung Method. *Int J Nephrol*. 2020
16. Asif A. American Society of Diagnostic and Interventional Nephrology Section Editor: Stephen Ash: Peritoneal Dialysis Access-Related Procedures by Nephrologists. *Semin Dial*. 2004; 17(5): 398-406.
17. Miftah M, Asseban M, Bezzaz A, Kallat A, Iken A, Nouini Y, et al. Mechanical Complications of Peritoneal Dialysis. *Open J Nephrol*. 2014; 04(03): 103-109.
18. Karayiannakis AJ, Polychronidis A, Chatzigianni E, Simopoulos C. Primary Torsion of the Greater Omentum: Report of a Case. *Surg Today*. 2002; 32(10): 913-915.
19. Nihei Z, Kojima K, Uehara K, Sawai S, Kakihana M, Hirayama R, et al. Omental bleeding with spontaneously derotated torsion. *Jpn J Surg*. 1991; 21(6): 700-702.
20. Park DJ, Oh K-H, Kim SJ, Joo KW, Han JS, Kim S, et al. True Aneurysm rupture of omental artery leading to hemoperitoneum and shock in a CAPD patient. *Nephrol Dial Transplant*. 2005; 20(10): 2292-2292.
21. Kroot EJA. Involvement of the omentum in Wegener's granulomatosis. *Ann Rheum Dis*. 2003; 62(12): 1238-1239.
22. Henry D, Satgunam S. Idiopathic omental bleeding. *J Surg Case Reports*. 2012; 2012(9): 2-2.
23. Rudiansyah M, Bandiara R, Supriyadi R, et al. The severe varicella zoster infection with kidney transplant patient using immunosuppressant. *International Journal of Pharmaceutical Research*. 2021; 13(1): 852-857.
24. Ahmadi N, Hong JSY, Mackie WS. Spontaneous idiopathic omental haemorrhage: a rare cause of right iliac fossa pain. *Surg Case Reports*. 2016; 2: 37.