

# Martapura\_river\_water\_leads\_to\_testes\_alteration\_in\_rats.pdf

*by*

---

**Submission date:** 25-Dec-2021 11:29AM (UTC+0700)

**Submission ID:** 1735569816

**File name:** Martapura\_river\_water\_leads\_to\_testes\_alteration\_in\_rats.pdf (1.15M)

**Word count:** 3093

**Character count:** 16364

PAPER · OPEN ACCESS

## Martapura river water leads to testes alteration in rats

3

To cite this article: I Yuliana *et al* 2019 *J. Phys.: Conf. Ser.* **1374** 012010

View the [article online](#) for updates and enhancements.



**IOP ebooks™**

Bringing together innovative digital publishing with leading authors from the global scientific community.

Start exploring the collection—download the first chapter of every title for free.

## Martapura river water leads to testes alteration in rats

I Yuliana<sup>1\*</sup>, H Khatimah<sup>1</sup>, L Rosida<sup>1</sup>, N S Skripsiana<sup>1</sup> and E Suhartono<sup>2</sup>

<sup>1</sup>Biomedical Department, Faculty of Medicine, Lambung Mangkurat University, South Kalimantan, Indonesia

<sup>2</sup>Biochemistry and Biomolecular Department, Faculty of Medicine, Lambung Mangkurat University, South Kalimantan, Indonesia

\*Corresponding author's email: dr.idayuliana@gmail.com

**Abstract.** The Martapura River is the main river in the Banjar district. Local residents use the water for life, even though the river has been polluted. This study aims to analyze changes in testicular morphometry and histology due to drinking water from the Martapura River. A total of 32 male Sprague Dawley rats were randomly divided into two groups (n = 16 per group). The control group was given aquades as drinking water. The treatment group is a group that has been drinking from the water of the Martapura River for 30 days. After euthanasia, the testes were processed and stained with hematoxylin-eosin. Testicular size, number of seminiferous tubules, spermatogonia cells, primary spermatocyte cells, and Leydig cells were analyzed microscopically. Martapura river water significantly induces testicular enlargement (p = 0.0036). In addition, there was a decrease in the number of seminiferous tubules (p < 0.001), spermatogonia cells (p = 0.002), primary spermatocytes cells (p < 0.001), and Leydig cells (p < 0.001) significantly compared to the control group. We conclude that drinking the water from the Martapura River triggers changes in morphometry and histological structure of the testis so that it can disrupt male reproductive function.

### 1. Introduction

Martapura and Banjarmasin are areas in South Kalimantan that is passed by the Martapura River. This river has been polluted by various pollutants such as heavy metals Pb, Cd, Hg and Fe [1], [2]. The heavy metal has been known to have a bad influence on health, for example Pb affects tissue structure of the testes [3-7]. Besides Pb, mercury also causes the reduction of purkinje cerebellum diameter [8]. Cadmium causes interference in various organs including brain [9], [10], kidney [6], [11], liver [12], [13], ovary [11], [14-16] bone and muscle [17].

The mechanism of organ damage due to heavy metals dissolved in the Martapura River water is still unclear. However, some previous studies have stated that pathomechanism of organ damage to cellular level through changes in cell signal cascade pathways, cell to cell adhesion, damage to protein structure, and oxidative stress [10], [18]. Cellular damage by heavy metals begins with mild injury stage occurs due to activation of the autophagy process and non-proliferative repair. If exposure to heavy metal concentrations increases, there will be a mechanism for releasing cell-to-cell bonds, and disruption of cell signaling pathways that have an impact on cell necrosis and apoptosis [19], [2].

Testes are reproductive organs in men who are susceptible to damage due to heavy metals. The testes function to produce male germ cells in the seminiferous tubules and the hormone testosterone by Leydig cells [21], [22]. These organs can experience various disorders that can cause a decrease in



2  
Content from this work may be used under the terms of the Creative Commons Attribution 3.0 licence. Any further distribution of this work must maintain attribution to the author(s) and the title of the work, journal citation and DOI.

function. There are many factors that influence decreased testicular function caused by cell damage. One of the factors is testicular poisoning by heavy metals. Based on research reports it is known that heavy metals can cause testicular germ cell damage in the form of apoptosis and cell necrosis in rodents, banded knife fish, *Pseudosciaenacrocea* (large yellow croaker), and *Oreochromis niloticus* (Nile tilapia) [22-24].

Research on the impact of heavy metals on the testes has been widely carried out, but the impact of the Martapura river water on the testes has not been widely studied (because there is no primary and secondary data on the incidence of male infertility in the Martapura region). Therefore, this research needs to be conducted as primary research.

## 2. Subject and methods

Total number of study subjects were 32 rats (*Rattus novergicus*), males, aged 2-6 months, and weight 250 - 300 g; obtained from BVET Banjarbaru. The study group was divided into 2 groups (16 groups each) namely the control group (given aquades) and treatment (given the Martapura river) for 30 days. Before the treatment period, the rats were acclimatized for 7 days. Rats are maintained according to maintenance standards in standard laboratories. Given a special cage made of plastic boxes with a size of 60 cm x 50 cm x 22 cm given a cage under the form of dry husk and given a lid from the wire each cage is only filled with 4 tails. For cage beds are replaced once a week continuously. Fedded specifically for animals, given an ad libitum drink. Evaluated physical and psychological conditions of rats every day.

Rats were given Martapura river water as a substitute for drinking water ad libitum. Rats were sacrificed on the 31st day and continued the process of making testicular histopathology with HE staining.

Rats were sacrificed by anesthesia using pentobarbital sodium drug. After the rat was declared dead, an autopsy of the abdomen was performed to isolate the testes organ. The size of testes was measured using a ruler (units of cm). Testes organ pieces were immediately fixed by soaking the organ in fixative solution (formol saline) for 24 hours or more.

Starting with the deparafinization process by means of preparations that are ready to be soaked first in a solution of xylol I and xylol II for 2 minutes. Continued the hydration process in an alcohol solution with a decreasing concentration of concentration, namely from 100% -95% -90% -80% -70% for 2 minutes each. Then the preparation is incubated in Hematoxylin Harris solution for 15 minutes, then rinsed in running water for 5-7 minutes. Preparations are dipped in ammonium or 0.4% carbonate lithium quickly as much as 3-10 x, then checking color differentiation under a light microscope. The preparation is rinsed again in running water for 1 minute. The preparation is dipped in lithium carbonate solution so that the preparation is bright blue. Preparations are rinsed in running water for 10-20 minutes. The preparation is incubated in 1% eosin for 2 minutes. The process of dehydration is continued by dipping the preparation into alcohol with a concentration that increases slowly, each for 2 minutes. The preparations were soaked in xylol I and xylol II solution for 2 minutes each. Continued sealing and covered with a cover glass. The preparation is ready to be observed under a light microscope.

The number of seminiferous tubules, Leydig cell, spermatogonium cells, and primary spermatocytes cells was analyzed microscopically using the binocular camera<sup>Nikon</sup> and software<sup>Image Raster</sup>, with a 10 µm and 100 µm scale and magnification of 10 x and 40 x.

The results of the research data were analyzed by independent t-test to evaluate alteration in size of testes, the number of seminiferous tubules, Leydig cell, spermatogonium cells, and primary spermatocytes cells in the control and treatment groups. In this study using a 95% confidence interval and significant data if p value <0.05.

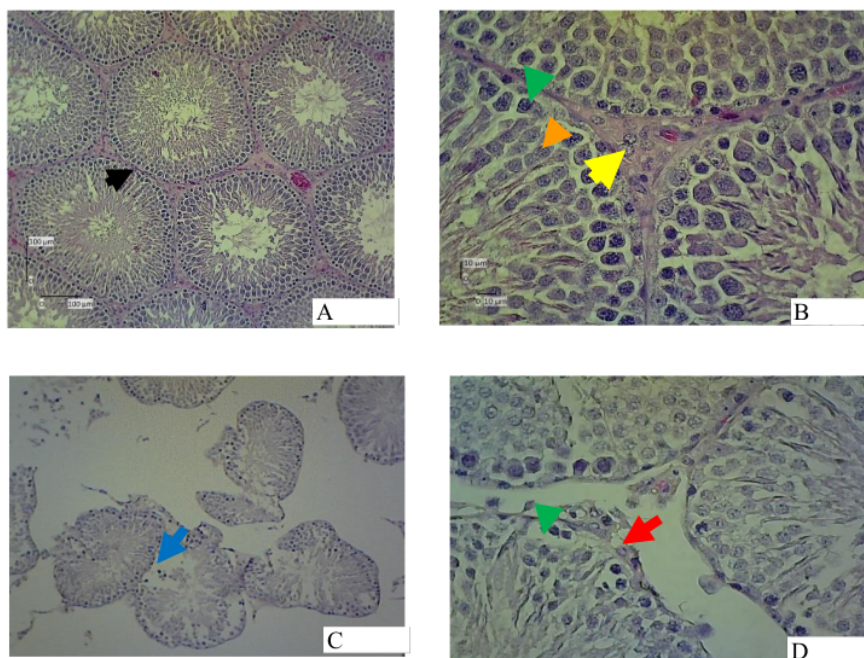
## 3. Result and discussion

Morphological alterations from both control and treatment groups can be seen in and Table 1 and Figure 1.

**Table 1.** Morphological alterations from both control and treatment groups.

Alteration on testes	Control	Treatment	P
Testicular size	2.49±0.58	2.893±0.62	0.03
Number of seminiferous tubules	8.44±1,2	6.19±1.03	0.00
Number of Leydig Cells	11.3±1.9	8.12±1.03	0.00
Number of spermatogonium cells	28.05±1.05	18.30±1.78	0.00
Number of primary spermatocytes cells	42.08±1.00	32.05±0.58	0.00

The testes function to produce male germ cells in the seminiferous tubules and testosterone by Leydig cells [21],[22]. These organs can experience various disorders that can lead to a decrease in function because it is an organ that is susceptible to damage due to heavy metals contaminating river water. Testicular damage in the study results was marked by enlargement of testicular size (Table 1). These conditions indicate the process of cell damage that begins with cell degeneration conditions include hydropic degeneration, fatty degeneration, swollen degeneration and vacuole degeneration[26],[27]. This is consistent with the study of Vergilio CS *et al* (2015) which shows that heavy metal exposure can cause changes in size testis [22]. The phenomenon of enlargement of the macroscopic size of the testes in the treatment group compared to the testis size of the treatment group due to the oedem process in the interstitial tissue in the testicular organs. This is confirmed by the existence of microscopic evidence of hydrophic degeneration, swollen degeneration and distance between seminiferous tubules which causes enlargement of testicular size in the treatment group (Figure 1).



**Figure 1.** Microscopic analysis of testes control group (A, B) and treatment (C, D); black arrow (seminiferous tubule); yellow arrow (Leydig cell); brown arrow (spermatosit primer); green arrow (spermatogonium); blue arrow (odem); green arrow (hypertopy cell); red arrow head (vacuole cell); (HE stain, binocular camera with 10  $\mu\text{m}$  and 100  $\mu\text{m}$  with magnification of 10 x and 40 x).

Martapura River water administration causes cell and tissue damage in the form of a significant decrease in the number of seminiferous tubules, Leydig cells, spermatogonia cells and primary spermatocytes cells in the treatment groups (Table 1 and Figure 1). In Figure 1 found fatty degeneration in the form of vacuole cells and hypertrophy cells as a marker of hypertrophic degeneration. The decrease in the number of seminiferous tubules and Leydig cells indicates the occurrence of germ cell death and Leydig cells due to the process of necrosis and apoptosis. This is in accordance with the research of Teiichiro Aoyagi *et al.* (2002); N Shiraishiet *al* (2001), FW Santos *et al* (2004), Wu X *et al* (2017) which statement that heavy metals cause a decrease in the number of germ cells in the seminiferous tubules and interstitial tissue proliferation [20],[28-30]. Wu X *et al* research (2017) shows that heavy metals can cause a decrease in the number of Leydig cells [30].

There are several pathomechanism theories mentioning cell damage in organs due to heavy metals. Exposure to heavy metals with low concentrations causes the process of oxidative stress, changes in the cascade pathway of cell signals, changes in cell adhesion to cells and damage to protein structure. The mechanism of celldamage through the pathway of oxidative stress because heavy metals such as iron, mercury, copper, nickel, cadmium and arsenic can be explained because of the ability of these molecules to form Reactive Oxygen Species (ROS). Reactive Oxygen Species causes cell damage through a mechanism of decreasing lipid bilayer and changes in DNA[31]. The accumulation of ROS in tissues characterized by the formation of active species such as hydroxyl radicals ( $\cdot\text{OH}$ ), hydrogen peroxidase ( $\text{H}_2\text{O}_2$ ) and single oxygen ( $\text{o}=\text{o}$ ) will cause disruption of balance between oxidants - antioxidants.

The active species will act with biomolecules such as proteins, nucleic acids, and lipids which cause lipid peroxidation, protein denaturation, and DNA mutations which result in changes in the

normal activity of cells, tissues, organs and even the physiological system of the body [10],[18],[32]. At the beginning exposure to heavy metals in cells will cause mild injury stage injury that occurs due to activation of the autofagi process and non-proliferative repair. If exposure to heavy metal concentrations increases, there will be a mechanism for releasing cell-to-cell bonds, and disruption of cell signaling pathways that have an impact on cell necrosis and apoptosis [19],[20].

#### 4. Conclusion

Conclusion from research is administration of Martapura river water can cause alteration morphometry and histological structure of the testis in rats. Major conclusion as follows :

1. Significantly increased testicular size in the treatment groups ( $p = 0.03$ )
2. Significantly decreased number of seminiferous tubules, Leydig cells, spermatogonia cells and primary spermatocyte cells in the treatment groups ( $p = 0.00$ )
3. Microscopic features in the testis treatment groups obtained hydrophic degeneration, swollen degeneration and distance between seminiferous tubules, vacuole cells and hypertrophy cells as a marker of hypertrophic degeneration.

#### References

- [1] Festiani S 2015 Martapura river high pollution. *Republika.Co.Id.* 19 April 2015
- [2] Fokus Batulicin 2011 River water quality in South Kalimantan decreases. 11 April 2011. Available [www.Fokusbatulicin.Com](http://www.Fokusbatulicin.Com)
- [3] Triadayani A L, RirisAryawati and GustiDiansyah 2010 The Effect of Lead Metal (Pb) on Testis Tissue of Duck Grouper (*Cromileptes Altivelis*) *Maspari Journal* 0142-47
- [4] Wiguna A, Hadi and Amarwati S 2017 Effect Of Administration Of Mercury Per Oral On Histopathological Features Of Wistar Rat Liver. *Jurnal Kedokteran Diponegoro.* **16** 673-681
- [5] Wang L, Xu T, Lei W *et al* 2011 Cadmium-Induced Oxidative Stress And Apoptotic Changes In The Testis Of Freshwater Crab, *Sinopotamon Heannense Plos One* **6** E27853
- [6] Karantika Ea, Supianur, Edyson and Suhartono E 2016 Kinetic paramaters analysis of liver and kidney catalase under the influence of cadmium (Cd) and mercury (Hg) in vitro *The Journal Of Tropical Life Science* **6** (2) 84
- [7] Hirako A, Takeoka Y, Furukawa S and Sugiyama A 2017 Effects Of Cadmium Exposure OnMedaka (*Oryzias Latipes*) Testes *J. Toxicol. Pathol.* **30** 255–260
- [8] Widyasari, Sunarti and Mufidah 2015 Purkinje cell diameter of rat (*Rattus Wistar L*) after induced water polluted with gold ore processing waste *Jurnal Biotik* **3** (1) 15-20
- [9] Somade P M, Adnaik R S, Mohite Sk *et al* 2014 Cadmium toxicity exposure-induced oxidative stress in postnatal development of wistar rats *Journal Of Toxicology And Environmental Health Sciences* **3** 269
- [10] Kamel M and Padhy P K 2013 Oxidative stress and heavy metals: an appraisalwith reference to environmental Biology *Int. Res. J. Biological Sci.* **2** (10) 91-101
- [11] Suhartono E, Faturahman and Iskandar T 2015 *Reproductive system disorders due to cadmium exposure* (Yogyakarta: Gosyen Publishing)
- [12] Koyu A, Gokcimen A, Ozguner F *et al* 2006 Evaluation of the effect of cadmium on rat liver *Moll. Cell Biochem.* **284** (1-2) 81-5
- [13] Kar R, Seema G, Halder S *et al* 2015 Cadmium exposure induces oxidative stress by decreasing expression of antioxidant enzymes in mice liver *International Journal Of Clinical Biochemistry And Research* **2** (2) 89-96
- [14] Ramadhani R, Eko S and Meitria S 2014 Perbedaan kadar advanced oxidation protein product (Aopp) ovarium tikus putih (*Rattus novergicus*) yang terpajan cadmium dan tidak terpajan cadmium *Jurnal Berkala Kedokteran* **10** (1) 111-120
- [15] Kara, Karata F and Canatan H 2005 Effet of single dose cadmium chloride administration on oxidative stress in male and female rats *Turk. J. Vet. Anim. Sci.* **29** 37-42

- [16] Arizal H M, Eko S and Bakhriansyah 2014 Effects of cadmium exposure to MDA levels on white rat ovaries *Berkala Kedokteran* **2** 1-8
- [17] Morsy A A, Salama K H A, Kamel H A and Mansour M M F 2012 Effect of heavy metals on plasma membrane lipids and antioxidant enzymes of *Zygophyllum* species *Eurasia J.Biosci.* **6** 1-10
- [18] Djohan C R T 2015 Accumulation of black lead in meat and bone of domestic and local chicken (lead accumulation in meat and bones of domestic and broiler chicken) *Jurnal Veteriner* **16** (4) 542-552
- [19] Xu C, Johnson J E, Singh P K *et al* 1996 In Vivo studies of cadmium-induced apoptosis in testicular tissue of the rat and its modulation by a chelating agent *Toxicology* **107** (1) 1–8
- [20] Aoyagi T, Ishikawa H, Miyaji K, Hayakawa K and Hata M 2002 cadmium-induced testicular damage in a rat model of subchronic intoxication *Reproductive Medicine And Biology* **1** (2) 59–63
- [21] Ross M H and Pawlina W 2006 *Histology A Text And Atlas With Colerated Cell And Molecular Biology* (Philadelphia :Lippincott Williams & Wilkins)
- [22] Junqueira L C 2000 *Basic Histology* (Jakarta: EGC)
- [23] Vergilio C S, Moreira R V, Carvalho C E and Melo E J 2015 Evolution of cadmium effects in the testis and sperm of the tropical fish *Gymnotus Carapo* *Tissue Cell* **47** 132–139
- [24] Luo Y, Shan D, Zhong H, Zhou Y, Chen W, Cao J *et al* 2015 Subchronic effects of cadmium on the gonads,expressions of steroid hormones and sex-related genes in *Tilapia Oreochromis Niloticus* *Ecotoxicology* **24** 2213–2223
- [25] Sheng Z, Yang W X and Zhu J Q 2015 Metallothionein from pseudosciaenacrocea: expression and response to cadmium induced injury in the testes *Ecotoxicology* **24** 779–794
- [26] Price S A and Lorraine M W 2006 *Pathophysiology of the Clinical Concept of Disease Processes* (Jakarta: EGC)
- [27] Spector 2006 *Introduction to General Pathology* (Yogyakarta: Gadjah Mada University)
- [28] Shiraishi N and Waalkes M P 1996 Acquired tolerance to cadmium-induced toxicity in the rodent testes *Toxic Subst. Mech.* **15** 27-42
- [29] Santos F W, Oro T, Zeni G, Rocha J B, DoNascimento P C and Nogueira C W 2004 Cadmium induced testicular damage and its response to administration of Succimer and diphenyldiselenide in mice *Toxicol. Lett.* **152** 255-263
- [30] Wu X, Guo X, Wang H, Zhou S, Li L, Chen X *et al* 2017 A brief exposure to cadmium impairs Leydig cell regeneration in the adult rat testis *Sci. Rep.* **7** (1) 6337
- [31] Valko M, Morris H and Cronin M T D 2005 Metals, Toxicity And Oxidative Damage *Current Medicinal Chemistry* **12** (10) 1161-208
- [32] Faix S, Faixova Z, Boldizarova K and Javorsky P 2005 The effect of long-term high heavy metal intake on lipid peroxidation of gastrointestinal tissue in sheep *Vet. Med.–Czech.* **50** (9) 401–405



# Martapura\_river\_water\_leads\_to\_testes\_alteration\_in\_rats.pdf

## ORIGINALITY REPORT

10%

SIMILARITY INDEX

9%

INTERNET SOURCES

8%

PUBLICATIONS

9%

STUDENT PAPERS

## PRIMARY SOURCES

1

Submitted to Universitas Sebelas Maret

Student Paper

6%

2

Submitted to University of Greenwich

Student Paper

2%

3

repo-dosen.ulm.ac.id

Internet Source

2%

Exclude quotes On

Exclude matches < 2%

Exclude bibliography On