

REKAM JEJAK DIGITAL

**Parapagus dicephalus conjoined twins with tribrachius
and a single heart –A scarce variant of conjoined twins: A case report**

HUMAN PATHOLOGY: CASE REPORTS

STATUS JURNAL DI SCOPUS DAN IMPACT FAKTORNYA SAAT INI

Home > Journals > Human Pathology: Case Reports



Human Pathology: Case Reports

Continued as [Human Pathology Reports](#)

Publishing options: Subscription

ISSN: 2214-3300

[Track your paper](#) v

[View articles](#)

Human Pathology: Case Reports, a companion title to the respected *Human Pathology*, is an open access online journal devoted solely to the publication of quality case reports, which involve all aspects of pathology, regardless of the system affected. The journal welcomes case reports and images in pathology submissions covering

[Read full aims & scope](#)

[CiteScore](#) ↗

0.3

[CiteScore Tracker](#) ↗

0.3

[Top Readership](#) ↗

US JP CN

View historical data and other metrics on [Journal Insights](#).

 Fully OA pathology journal now accepting original research
Human Pathology Reports
formerly Human Pathology: Case Reports

 **Submit today!**

SCIMAGO RANK JURNAL

Only Open Access Journals
 Only SciELO Journals
 Only WoS Journals ?

Display journals with at least 0 Citable Docs. (3years) ▼ Apply

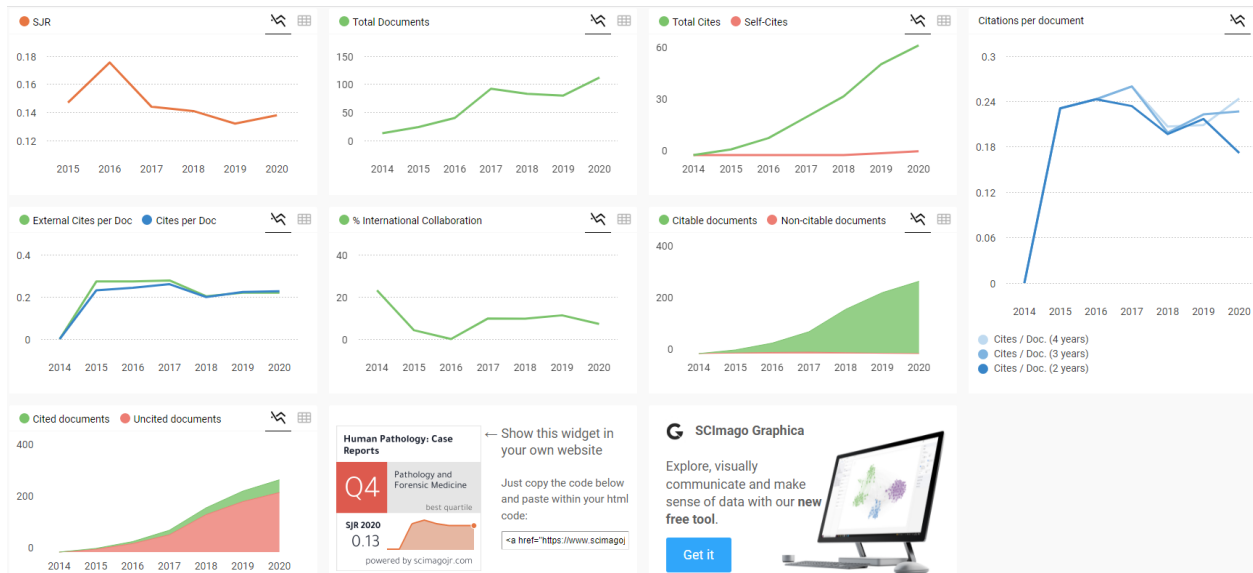
[Download data](#)

1 - 6 of 6 ◀ ▶

Title	Type	↓ SJR	H index	Total Docs. (2020)	Total Docs. (3years)	Total Refs. (2020)	Total Cites (3years)	Citable Docs. (3years)	Cites / Doc. (2years)	Ref. / Doc. (2020)
1 Brain Pathology	journal	1.986 Q1	132	117	295	5604	1170	229	3.52	47.90
2 Aging and Disease	journal	1.808 Q1	54	122	270	10311	1855	265	6.50	84.52
3 Pathology Research International	journal	0.398 Q3	21	0	14	0	32	14	2.00	0.00
4 Human Pathology: Case Reports	journal	0.132 Q4	5	112	255	1892	58	255	0.17	16.89
5 Journal of Plastination	journal	0.102 Q4	1	10	14	156	0	10	0.00	15.60
6 International Journal of Physiology, Pathophysiology and Pharmacology (discontinued)	journal		27	3	26	117	48	26	0.00	39.00

Human Pathology: Case Reports

COUNTRY United States 	SUBJECT AREA AND CATEGORY Medicine ↳ Pathology and Forensic Medicine	PUBLISHER Elsevier Inc.	H-INDEX 5
PUBLICATION TYPE Journals	ISSN 22143300	COVERAGE 2014-2020	INFORMATION Homepage How to publish in this journal HPCR@elsevier.com



Human Pathology: Case Reports

Q4 Pathology and Forensic Medicine
best quartile

SJR 2020
0.13

powered by scimagojr.com

— Show this widget in your own website

Just copy the code below and paste within your html code:

``

SCImago Graphica

Explore, visually communicate and make sense of data with our new free tool.

[Get it](#)

SUBMISSION ARTIKEL: TANGGAL 25 FEBRUARI 2021

Gmail interface showing an email from Human Pathology Case Reports. The subject is "Submission to Human Pathology: Case Reports - manuscript number". The email body contains the following text:

"This is an automated message."

Manuscript Number: HPCR-D-21-00035
Parapagus dicephalus conjoined twins with trirachilus and a single heart - a case report

Dear Dr RINGORINGO,

Your above referenced submission has been assigned a manuscript number: HPCR-D-21-00035.

To track the status of your manuscript, please log in as an author at <https://www.editorialmanager.com/hpcr/>, and navigate to the "Submissions Being Processed" folder.

Thank you for submitting your work to this journal.

Kind regards,
Human Pathology Case Reports

More information and support

You will find information relevant for you as an author on Elsevier's Author Hub: <https://www.elsevier.com/authors>

FAQ: How can I reset a forgotten password?
https://service.elsevier.com/app/answers/detail/a_id/28452/supporthub/publishing/

For further assistance, please visit our customer service site: <https://service.elsevier.com/app/home/supporthub/publishing/>

Here you can search for solutions on a range of topics, find answers to frequently asked questions, and learn more about Editorial Manager via interactive tutorials. You can also talk 24/7 to our customer support team by phone and 24/7 by live chat and email

In compliance with data protection regulations, you may request that we remove your personal registration details at any time. (Use the following URL: <https://www.editorialmanager.com/hpcr/login.asp?err>) Please contact the publication office if you have any questions.

TANGGAPAN PEER REVIEW JOURNAL

REVISE YOUR MANUSCRIPT : 19 APRIL 2021 – 27 MEI 2021

19 APRIL 2021

Decision on submission to **Human Pathology: Case Reports** External inbox x

Human Pathology Case Reports <em@editorialmanager.com>
to me

Mon, Apr 19, 2021, 9:56 PM

English → Czech [Translate message](#) Turn off for: English x

Manuscript Number: HPCR-D-21-00035

Parapagus dicephalus conjoined twins with trirachius and a single heart - a scarce variant of conjoined twins: a **case report**

Dear Dr RINGORINGO,

Thank you for submitting your manuscript to **Human Pathology: Case Reports**.

I have completed my evaluation of your manuscript. The reviewers recommend reconsideration of your manuscript following minor revision and modification. I invite you to resubmit your manuscript after addressing the comments below. Please resubmit your revised manuscript by Jun 18, 2021.

When revising your manuscript, please consider all issues mentioned in the reviewers' comments carefully: please outline every change made in response to their comments and provide suitable rebuttals for any comments not addressed. Please note that your revised submission may need to be re-reviewed.

All revised manuscripts must include the following two sections just before the reference section:

1. Author Disclosure statement
2. Ethics Statement including Patient Consent Statement

Please refer to the information for authors for more information. Any revised paper not formatted according to journal requirements will be returned to the author.

To submit your revised manuscript, please log in as an author at <https://www.editorialmanager.com/hpcr/>, and navigate to the "Submissions Needing Revision" folder under the Author Main Menu.

Human Pathology: Case Reports values your contribution and I look forward to receiving your revised manuscript.

Kind regards,

Shi Wei, MD, PhD
Editor-in-Chief
Human Pathology: Case Reports

11 MEI 2021

Decision on submission to **Human Pathology: Case Reports** External inbox x

Human Pathology Case Reports <em@editorialmanager.com>
to me

Tue, May 11, 2021, 11:11 PM

English → Czech [Translate message](#) Turn off for: English x

Manuscript Number: HPCR-D-21-00035R1

Parapagus dicephalus conjoined twins with trirachius and a single heart - a scarce variant of conjoined twins: a **case report**

Dear Dr RINGORINGO,

Thank you for submitting your manuscript to **Human Pathology: Case Reports**.

I have completed my evaluation of your manuscript. The reviewers recommend reconsideration of your manuscript following minor revision and modification. I invite you to resubmit your manuscript after addressing the comments below. Please resubmit your revised manuscript by Jul 10, 2021.

When revising your manuscript, please consider all issues mentioned in the reviewers' comments carefully: please outline every change made in response to their comments and provide suitable rebuttals for any comments not addressed. Please note that your revised submission may need to be re-reviewed.

All revised manuscripts must include the following two sections just before the reference section:

1. Author Disclosure statement
2. Ethics Statement including Patient Consent Statement

Please refer to the information for authors for more information. Any revised paper not formatted according to journal requirements will be returned to the author.

To submit your revised manuscript, please log in as an author at <https://www.editorialmanager.com/hpcr/>, and navigate to the "Submissions Needing Revision" folder under the Author Main Menu.

Human Pathology: Case Reports values your contribution and I look forward to receiving your revised manuscript.

Kind regards,

Shi Wei, MD, PhD
Editor-in-Chief
Human Pathology: Case Reports

Gmail | human pathology case report | Active | 36 of many

Editor and Reviewer comments:

Reviewer #1: Dear Authors,

Thank you for the opportunity to review this paper reporting on a **case** of a rare variant of conjoined twins. This pattern of twinning has been reported previously in the literature, but it is rare, and this **case** does provide the relatively unusual feature of shared thoracic organs and three arms.

What was the reason the mother was not imaged via prenatal ultrasound? Was it due to a low-resource environment, or her choice? If a low-resource environment, this is a unique feature itself, and I suggest that it be emphasized. Generally reports of these types of cases from low-resource environments are underrepresented in the literature, and they often present unique challenges important to know about.

In general, this **report** would benefit from some editing of the English syntax and word choice for clarity. Example in the Introduction: "Generally stillbirth or only a few hours or a few days of death." The meaning is unclear. Many examples of this exist throughout the **report**, and in some cases, compromise the clarity of the message.

The following suggestions are offered for improvement:

Case presentation
 "One pair of superior extremities and one other superior limb showed the humeral, radial, ulnar, and five phalanges." This text implies that you can see these things on the radiograph, but in Fig 2, it looks like the middle arm details are not well-visualized, and the phalanges of the other two arms are also not well-visualized. I assume the digit number was verified on physical exam, so that information can be moved there. More precision is needed here.

Discussion

- "Parallel duplication of two notochords" - It's not clear here that the embryos start out separate, as two parallel notochords that later fuse. I recommend to say something like: "Lateral conjoining is thought to occur due to close approximation of parallel notochords of the two embryos early in development." (Although there is some controversy about the embryologic origin of conjoining, I believe your statement that "the most accepted" hypothesis is a reasonable approach.)
 "parapagus are conjoined to the upper chest" - do you mean that parapagus twins are conjoined below the upper chest?
- The parapagus component of the terminology is explained in the discussion. However, you mention other terms omphalopagus and dicephalus, which the diverse readership of this journal may not know. A brief statement about the general assignment of terminology for anatomic classification will be helpful (e.g. to explain that anatomic classification is based on the most obvious joined structures, followed by "pagus" which means that they are joined.)
- How many vessels were in the umbilical cord? This has implications for degree of fusion/separation of internal structures.
- Second paragraph in discussion, beginning "The pure parapagus." I suggest making it more clear in the text exactly how this **case** differs from the "pure parapagus." This is unclear as written (e.g. your **case** has 3 arms, one heart, and one pair of lungs). Are you trying to say that your **case** differs from the **cases** of dicephalus with 2-3 arms? This is unclear.
- "The anus is positive" do you mean the anus is patent? Present?
- The following reference details a similar **case** to this one, with slightly different degree of separation of the twins, and may be of interest and use in this **report**.
 Bovendeert J.M, Nieuwstein R.A.J, Bleys R.L.A.W, Cleypool C.G.J. A parapagus dicephalus tripus trirachius conjoined twin with a unique morphological pattern: a **case report**. J Med Case Rep. 2020 Oct 3;14(1):176.

Gmail | human pathology case report | Active | 33 of many

Editor-in-Chief

Human Pathology Case Reports

Editor and Reviewer comments:

The authors need to address the following:

- The high resolution figures should be submitted SEPARATELY but not embedded in the text.
- There should be a separate Figure legends section in the text.
- Figure 2 is not acceptable in its current form. ALL the confidential information should be removed. The figure should be cropped to remove all unnecessary background.
- Figure 1 should be labeled "Gross photograph of parapagus dicephalus trirachius"
- Figure 2 should be labeled "Conventional babygram of the conjoined twins"
- All above are common rules for all scientific journals, but not unique to this journal. If the authors are unclear, any previously published **case report** in this journal would be a good reference.

13 MEI 2021

Gmail | human pathology case report | Active | 30 of many

Send Back to Author: Request to Edit Submission | External | Inbox x

Human Pathology Case Reports <emg@editorialmanager.com>
 to me

Thu, May 13, 2021, 12:38 AM

English > Czech > Translate message | Turn off for: English x

Article Title: Parapagus dicephalus conjoined twins with trirachius and a single heart - a scarce variant of conjoined twins. a **case report**
 Corresponding Author: Dr HARAPAN PARLINDUNGAN RINGORINGO

Dear Dr RINGORINGO,

Your submission entitled "Parapagus dicephalus conjoined twins with trirachius and a single heart - a scarce variant of conjoined twins: a **case report**" has been received by Human Pathology Case Reports. However, before we can proceed with the review process we ask you to address the following:

Please include a patient consent statement just before the reference section of your manuscript. Thank you!

Please log onto Elsevier Editorial System as an Author:
<https://www.editorialmanager.com/hpcr/>

- Go to the menu item "Submissions/Revisions Sent Back to Author".
- Click "Edit Submission/Revision".
- Click on the relevant submission step on the left-hand menu.
- Provide or modify the item/information as requested.
- Go to "Attach Files" and "Build PDF for my Approval".
- View and Approve your new PDF file including the changed item(s), or if needed, Edit again.

Thank you for submitting your work to the journal, and if you have any questions, please do not hesitate to contact me.
 Yours sincerely,
 Human Pathology Case Reports

Have questions or need assistance?
 For further assistance, please visit our customer service site: <http://help.elsevier.com/app/answers/list/p/5435/>. Here you can search for solutions on a range of topics, find answers to frequently asked questions, and learn more about Editorial Manager via interactive tutorials. You can also talk 24/5 to our customer support team by phone and 24/7 by live chat and email.

21 MEI 2021

Send Back to Author: Request to Edit Submission (External) Inbox x

Human Pathology Case Reports <em@editorialmanager.com>
to me

English > Czech > Translate message Turn off for: English x

Article Title: Parapagus dicephalus conjoined twins with trirachius and a single heart - a scarce variant of conjoined twins: a case report
Corresponding Author: Dr HARAPAN PARLINDUNGAN RINGORINGO

Dear Dr RINGORINGO,

Your submission entitled "Parapagus dicephalus conjoined twins with trirachius and a single heart - a scarce variant of conjoined twins: a case report" has been received by Human Pathology Case Reports. However, before we can proceed with the review process we ask you to address the following:

1. Please submit your manuscript with the figures as separate files not embedded in the text.
2. Please make sure you are submitting 1 copy of your re-revised manuscript with changes tracked and 1 copy with no changes showing.

Please log onto Elsevier Editorial System as an Author:
<https://www.editorialmanager.com/hpcr/>

1. Go to the menu item "Submissions/Revisions Sent Back to Author".
2. Click "Edit Submission/Revision".
3. Click on the relevant submission step on the left-hand menu.
4. Provide or modify the item/information as requested.
5. Go to "Attach Files" and "Build PDF for my Approval".
6. View and Approve your new PDF file including the changed item(s), or if needed, Edit again.

Thank you for submitting your work to the journal, and if you have any questions, please do not hesitate to contact me.
Yours sincerely,
Human Pathology Case Reports

27 MEI 2021

Send Back to Author: Request to Edit Submission (External) Inbox x

Human Pathology Case Reports <em@editorialmanager.com>
to me

English > Czech > Translate message Turn off for: English x

Article Title: Parapagus dicephalus conjoined twins with trirachius and a single heart - a scarce variant of conjoined twins: a case report
Corresponding Author: Dr HARAPAN PARLINDUNGAN RINGORINGO

Dear Dr RINGORINGO,

Your submission entitled "Parapagus dicephalus conjoined twins with trirachius and a single heart - a scarce variant of conjoined twins: a case report" has been received by Human Pathology Case Reports. However, before we can proceed with the review process we ask you to address the following:

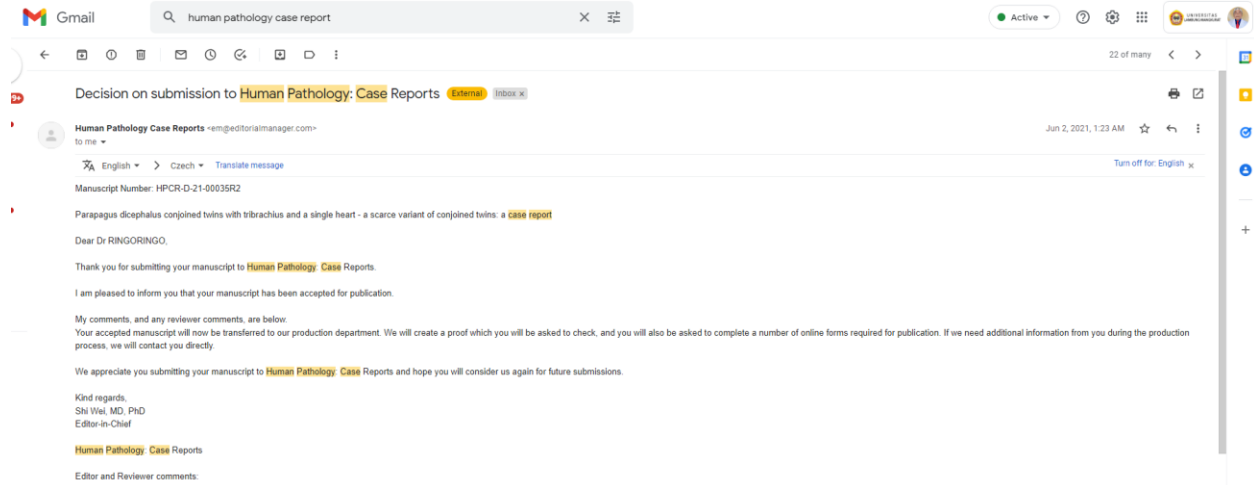
1. Please submit only 2 manuscript files: the current revised manuscript with changes marked and the current version with no changes marked. Do not include earlier versions.
2. Please submit both Fig 1 and Figure 2 as separate files.
3. The Figure legends should appear after the references.
4. Please make sure no patient information is identifiable in your figures.

Please log onto Elsevier Editorial System as an Author:
<https://www.editorialmanager.com/hpcr/>

1. Go to the menu item "Submissions/Revisions Sent Back to Author".
2. Click "Edit Submission/Revision".
3. Click on the relevant submission step on the left-hand menu.
4. Provide or modify the item/information as requested.
5. Go to "Attach Files" and "Build PDF for my Approval".
6. View and Approve your new PDF file including the changed item(s), or if needed, Edit again.

Thank you for submitting your work to the journal, and if you have any questions, please do not hesitate to contact me.
Yours sincerely,
Human Pathology Case Reports

ACCEPTED MANUSCRIPT : 2 JUNI 2021



← Submissions with an Editorial Office Decision for Author

Page: 1 of 1 (1 total completed submissions)

Results per page 10

Action	Manuscript Number	Title	Initial Date Submitted	Status Date	Current Status	Date Final Disposition Set	Final Disposition
Action Links	HPCR-D-21-00036	Parapagus dicephalus conjoined twins with tribrachius and a single heart - a scarce variant of conjoined twins: a case report	Feb 24, 2021	Jun 01, 2021	Completed - Accept	Jun 01, 2021	Accept

Page: 1 of 1 (1 total completed submissions)

Results per page 10

[Log In](#) [Register](#) [Help](#)

Track Your Accepted Article

The easiest way to check the publication status of your accepted article

[Parapagus dicephalus conjoined twins with tribrachius and a single heart - a scarce variant of conjoined twins: a case report](#)

Article reference	EHPC_200533
Journal	Human Pathology: Case Reports
Corresponding author	Harapan Parlindungan Ringoringo
First author	Harapan Parlindungan Ringoringo
Received at Editorial Office	24 Feb 2021
Article revised	27 May 2021
Article accepted for publication	1 Jun 2021
DOI	10.1016/j.ehpc.2021.200533



ISSN 2214-3300

Last update: 2 Sep 2021

[Share via email](#)

Feedback

INVOICE REGULAR PUBLICATION FEE : 15 JUNI 2021

Invoice

Mailing Address	Supply to	Customer reference	ECR-101642310
Harapan Parindungan Ringoringo Kompleks Citra Megah Raya III No.14 RT 07 / RW 02 Kelurahan Loktabat Utara – Kecamatan Banjarbaru Utara Banjarbaru 70712 Indonesia	Harapan Parindungan Ringoringo Kompleks Citra Megah Raya III No.14 RT 07 / RW 02 Kelurahan Loktabat Utara – Kecamatan Banjarbaru Utara Banjarbaru 70712 Indonesia	Invoice number	OAD0000126972
		Invoice date	15-JUN-2021
		Due date	15-JUL-2021
		Terms	30 Days
		Your PO	
		Customer tax reg no	-

Line	Product reference	Item	Qty	Net unit price	Net amount	Tax	Total amount
1	EPR-1001B7	Human Pathology: Case Reports - Article Publishing Charge Article: Parapagus dicephalus conjoined twins with tribrachius and a single heart - a scarce variant of conjoined twins: a case report Author: Dr. Harapan Parindungan Ringoringo PII: S2214330021000626 Tax @ 0.00%	1	750.00	750.00	0.00	750.00
Total					750.00	0.00	750.00
Total due						USD	750.00

BUKTI TRANSFER REGULAR PUBLICATION FEE:

Thank you for your payment.

Something not right? Call Customer Support on +1 888 955 5291.

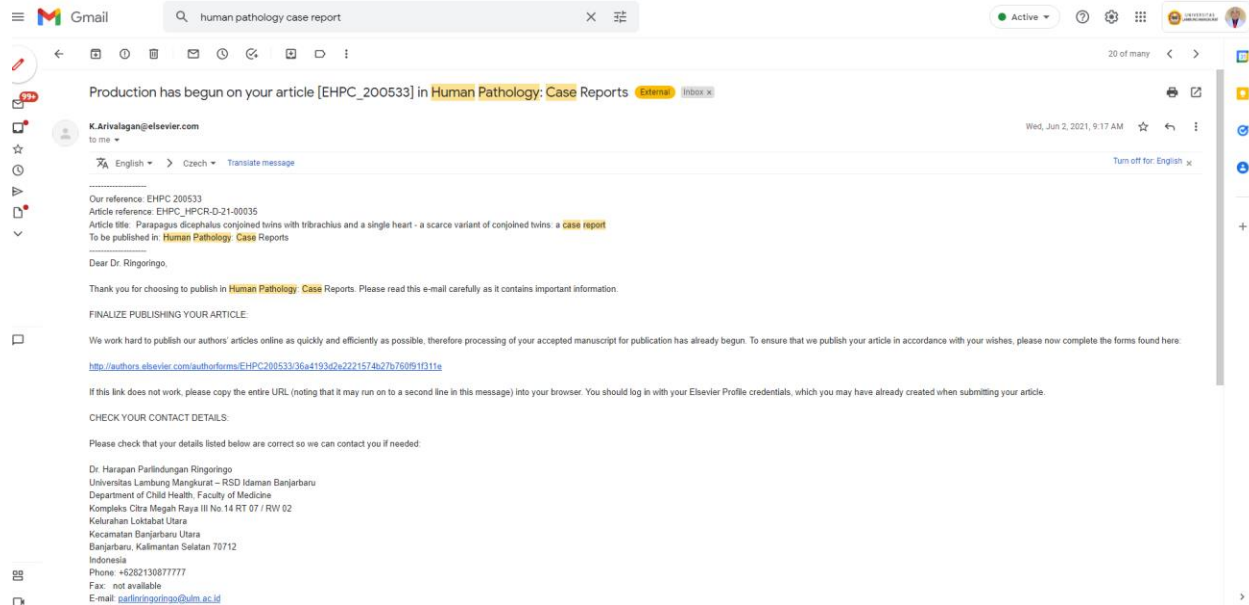
Your Invoice

Customer ID	3357851
Invoice number	OAD0000126972
Invoice date	15th June 2021
Invoice amount	\$750.00
You paid	\$750.00

[< Pay another invoice](#)




PRODUCTION OF ARTICLE : 2 JUNI 2021



GALLERY PROOF PUBLICATION:

Case Report

Parapagus dicephalus conjoined twins with tribrachius and a single heart – A scarce variant of conjoined twins: A case report

 The corrections made in this section will be reviewed and approved by a journal production editor.

Q2 Harapan Parlindungan **Ringoringo*** parlinringoringo@ulm.ac.id

Department of Child Health, Faculty of Medicine, Universitas Lambung Mangkurat, RSD Idaman Banjarbaru, Indonesia

*Address: Kompleks Citra Megah Raya III No.14 RT 07 / RW 02, Kelurahan Loktabat Utara, Kecamatan

Q3 Banjarbaru Kalimantan Selatan, 70712 Utara, Indonesia

Keywords:

Parapagus dicephalus, Conjoined twins, Tribrachius, ~~A single heart~~ A single heart

Q4 Funding

No funds, no grants, or other support was received.


Patient consent statement

Here the author share link the patient consent statement for publication.
<https://drive.google.com/file/d/1T6SVXhfgaOEA6KLn2hI62VsHr3YR88C1/view?usp=sharing>.

Declaration of Competing Interest

The author ~~s~~ declares ~~that they~~ the author have ~~has~~ no known competing financial interests or personal relationships that could have ~~appeared to influence~~ influenced the work reported in this paper.

References

 The corrections made in this section will be reviewed and approved by a journal production editor. The newly added/removed references and its citations will be reordered and rearranged by the production team.

[1] Tan K.L., Goon S.M., Salmon Y., Wee J.H., Cnjoined Twins, Acta Obstet. Gynecol. Scand. 50 (4) (1971) 373–380, doi:10.3109/00016347109157342.

ARTICLE PUBLISHED : 21 JUNI 2021

Share your article [EHPC_200533] published in **Human Pathology: Case Reports** External Inbox x


Elsevier - Article Status <Article_Status@elsevier.com> to me
Mon, Jun 21, 2021, 11:48 PM
English > Czech Translate message Turn off for English

ELSEVIER
Share your article!

Dear Dr. Ringoringo,

We are pleased to let you know that the final open access version of your article *Parapagus dicephalus conjoined twins with tribrachius and a single heart - a scarce variant of conjoined twins: a case report* is now available online, containing full bibliographic details.

The URL below is a quick and easy way to share your work with colleagues, co-authors and friends. Anyone clicking on the link will be taken directly to the final version of your article on ScienceDirect.



Your article link:
[https://authors.elsevier.com/sd/article/S2214-3300\(21\)00062-6](https://authors.elsevier.com/sd/article/S2214-3300(21)00062-6)

Click on the icons below to share with your network:

[f](#) [t](#) [in](#) [+](#) [m](#)

You can also use this link to download a copy of the article for your own archive. It also provides a quick and easy way to share your work with colleagues, co-authors and friends. And you are welcome to add it to your homepage or social media profiles.