

# Combined endoscopy- laparoscopy-gastronomy extraction for rapunzel syndrome

*by* Poerwosusanto Hery

---

**Submission date:** 17-Nov-2020 11:33AM (UTC+0700)

**Submission ID:** 1448624407

**File name:** copy-laparoscopy-gastronomy\_extraction\_for\_rapunzel\_syndrome.pdf (3.33M)

**Word count:** 1492

**Character count:** 8756



## Combined endoscopy-laparoscopy-gastrostomy extraction for Rapunzel syndrome

Hery Poerwosusanta<sup>a,\*</sup>, Pricilia G. Halim<sup>b</sup>, Adrian Sitompul<sup>a</sup>, Agung Ari Wibowo<sup>a</sup>

<sup>a</sup> Department of Surgery, Faculty of Medicine, Universitas Lambung Mangkurat, Banjarmasin, Indonesia

<sup>b</sup> Department of Pediatric, Faculty of Medicine, Universitas Lambung Mangkurat, Banjarmasin, Indonesia

### ARTICLE INFO

#### Keywords:

Rapunzel syndrome  
Endoscopy-laparoscopy-gastrostomy  
Minimally invasive surgery

### ABSTRACT

**Introduction:** Rapunzel syndrome (RS) is an uncommon diagnosis in children with less than 40 cases reported. Open-laparotomy-gastrostomy, as standard treatment, has many risks, while single endoscopy or laparoscopy is quite hard to be performed for too many trichobezoars. We present a case of RS treated successfully with the first combination of endoscopy-laparoscopy-gastrostomy.

**Case:** A 9-year-old girl with episodic abdominal pain, recurrent vomiting, anorexia, constipation, non-tender abdominal enlargement, trichophagia, and trichotillomania was diagnosed as RS from barium meal and endoscopy examination. We performed combined endoscopy-laparoscopy-gastrostomy to remove 400 g of bezoar mass. The patient had a good outcome and a shorter hospital stay.

**Conclusion:** Combined endoscopy-laparoscopy-gastrostomy provide better treatment of choice in a child with Rapunzel syndrome.

**Key messages:** Minimal invasive surgery performed through combined endoscopy-laparoscopy-gastrostomy is the new removal technique for large size trichobezoar.

### 1. Introduction

Since first reported, less than 40 RS cases with various improvised techniques were carried out. Open surgery has higher risks of intestinal adhesion [1,2]. Gastrostomy has the risk of leakage and decreased gastric motility [3]. Minimally invasive surgery could reduce the risk of laparotomy-gastrostomy as standard therapy [4]. However, single laparoscopy or endoscopy usually is not sufficient enough to remove the large size trichobezoar. We reported a rare case of RS that has been treated with the first combined-endoscopy-laparoscopy-gastrostomy techniques with a good outcome.

### 2. Case report

A 9-year-old girl admitted with an episodic abdominal pain around epigastrium for one week before admission. She had partial obstructive symptoms: worsened vomiting after meals, anorexia, constipation, and a non-tender abdominal mass enlarged one year before admission. She had a habit of pulling and swallowing her hair five years

ago, with no history of previous gastrointestinal surgery and other metabolic disorders. The vital signs were within-normal-limit. On physical examination, there was a solid, mobile, irregular border mass on the epigastric region, extended to the periumbilical and right hypochondriac, and increased bowel sounds. Complete-blood-count was within-normal-limit. Upper-gastrointestinal x-ray showed intraluminal filling defects in the stomach and duodenum-bulb that resemble trichobezoar [Fig. 1B].

Endoscopy examination confirmed trichobezoar that extends to the duodenum [Fig. 1C and D] [5]. We decided to remove trichobezoar through combined-endoscopy-laparoscopy-gastrostomy [Fig. 2]. Psychiatrists, pediatrician, and anaesthesiologist collaboration was performed to prevent a recurrence [6].

The procedure was begun by inserting ports and laparoscopic-exploration to detect complications. Avoiding the spillage, the harmonic-scalpel is used for the anterior wall gastrostomy, after approaching, and fixed to the extension umbilical-incision. Four-hundred grams trichobezoar was taken gradually and successfully with a clamp [Fig. 2A and C]. The residue was evaluated through en-

\* Corresponding author. Department of Surgery, Ulin General Hospital/Faculty of Medicine, Universitas Lambung Mangkurat, Jl. A. Yani Km 2,5 No.79, Banjarmasin, South Kalimantan, Indonesia.

E-mail address: [herpoerwo@ulm.ac.id](mailto:herpoerwo@ulm.ac.id) (H. Poerwosusanta).

<https://doi.org/10.1016/j.epsc.2020.101631>

Received 29 July 2020; Received in revised form 20 August 2020; Accepted 21 August 2020

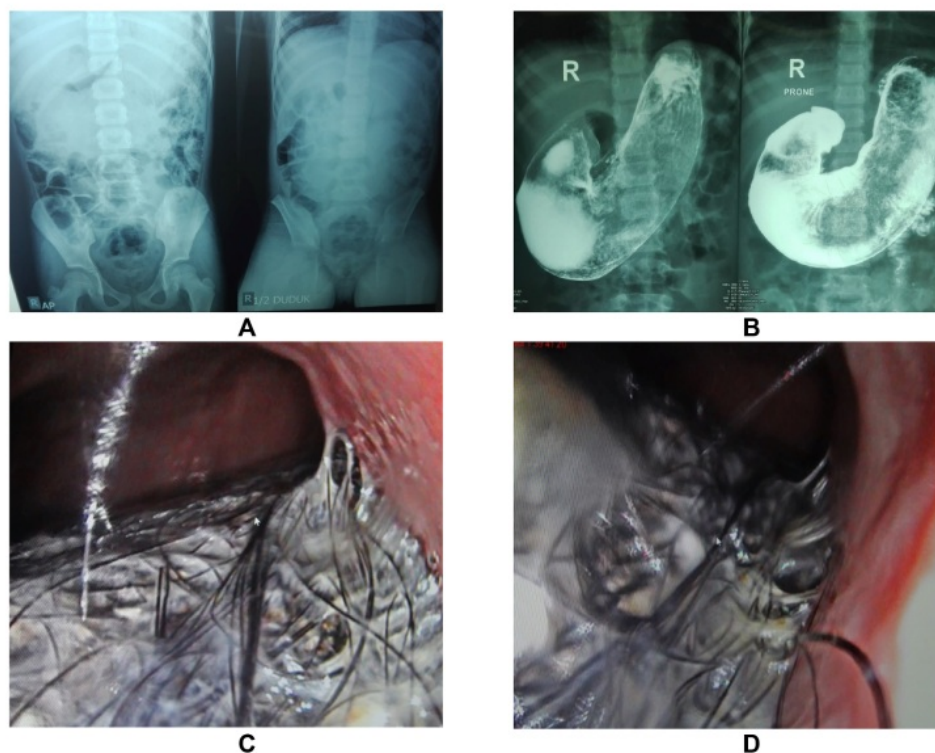
Available online 2 August 2020

2213-5766/© 2020 The Authors.

Published by Elsevier Inc.

This is an open access article under the CC BY-NC-ND license

<http://creativecommons.org/licenses/by-nc-nd/4.0/>.



**Fig. 1.** A) The plain abdominal x-ray showed radiopaque in the stomach. B) The upper GI x-ray, gastric intraluminal mass extended to the duodenal and impressed trichobezoar (Rapunzel syndrome). C) Upper site endoscopy showed trichobezoar. D) Lower site gastro-endoscopy after partially removed.

doscopy-gastrostomy [Fig. 2B], gastrostomy was closed with 2.0-absorbable suture and ending with skin closure [Fig. 2D]. The patient was discharged on the 3rd day after surgery without any complication.

### 3. Discussion

Complete removal is the primary goal in RS. Treatment depends on the size and location of the trichobezoars. Single endoscopy or laparoscopy only works for small trichobezoar (<50 g), and it takes a longer time [7–9]. Laparotomy-gastrostomy is the most used technique in large size trichobezoar [3,10]. A successful combined-endoscopy-laparoscopy-gastrostomy for large trichobezoar gave more benefits than open surgery.

Different from the previous technique [11–13], gastrostomy using harmonic scalpel was performed on the umbilicus extension incision to prevent spillage. The umbilicus extension incision was preventing to make a new other incision. Ideally, stay-suture should be used to avoid stomach damage [12]. Small stomach incision by harmonic scalpel reduced leakage, minimize injury, decreased the risk of a gastric-motility disorder, reduced thermal injury, and earlier enteral feeding. Other advantages of combines endoscopy-laparoscopy-gastrostomy were minimal trauma, precise endoscopic remnant evaluation, needs less than one hour, provide better cosmetic results, and minimizes the risk of anesthesia. Upper GI study and endoscopy were more practical, comfortable to replace contrast-enhanced-computed-tomography (CECT), and quite useful for diagnosing and estimating the size of trichobezoar [14]. Shorter surgery time, lower risk of wound dehiscence, small surgery wound proved that the method was safe. In this paper, we provide a prospective minimally invasive surgical approach for treating RS with a large trichobezoar. The patient

started a smoothie diet on the 2nd day and was discharged on the 3rd day after surgery without complications, it emphasized that this technique was completely safe.

### 4. Conclusion

Combined-endoscopy-laparoscopy-gastrostomy is an applicable and promising method in RS with large size trichobezoar.

#### 3 Consent

Consent to publish the case report was not obtained. This report does not contain any personal information that could lead to the identification of the patient.

#### Ethical approval

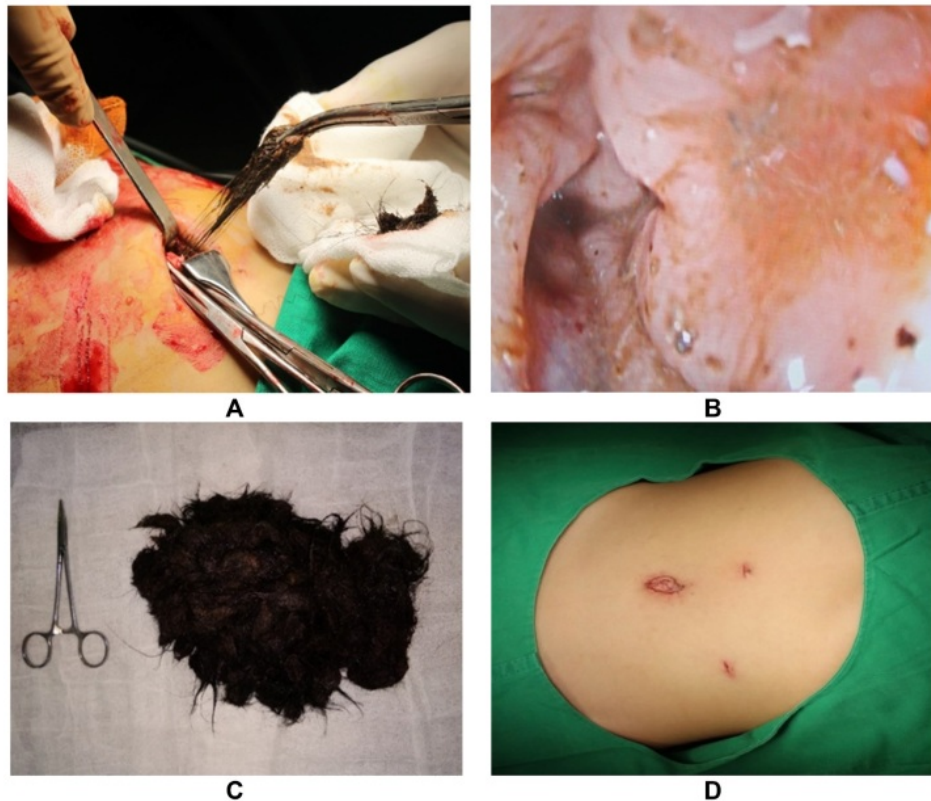
Not applicable.

#### Funding

No funding or grant support

#### Authorship

HP and AS compiled and wrote the manuscript. HP, AS, and AAW led surgical and medical management. AAW and PGH supervised the writing of the manuscript. All authors read and approved the manuscript. All authors attest that they meet the J. Pediatr. Surg. Case Rep. criteria for Authorship.



**Fig. 2.** A) With a harmonic scalpel, gastrotomy approached and fixed in the umbilical-incision, preventing spillage to the peritoneal cavity. B) Upper and lower site endoscopy evaluation ensured the trichobezoar remnant. C) The 400 g of trichobezoar has been removed. D) The excellent postoperative wound.

#### 1 Declaration of competing interest

The authors declare that they have no known competing financial interests or personal relationships that could have appeared to influence the work reported in this paper.

#### Acknowledgements

We also want to thank you for the collaboration of nurses from the surgery ward.

#### References

- [1] Wang Z, Cao F, Liu D, Fang Y, Li F. The diagnosis and treatment of Rapunzel syndrome. *Acta Radiol Open* 2016;5:1–4.
- [2] Vaughan Jr ED, Sawyers JL, Scott HW. The Rapunzel syndrome: an unusual complication of intestinal bezoar. *Surgery* 1968;63:339–43.
- [3] Gorter RR, Kneepkens CM, Mattens EC, Aronson DC, Heij HA. Management of trichobezoar: case report and literature review. *Pediatr Surg* 2010;26:457–63.
- [4] Shahab MA, Shahab A, Javid S. Management of Rapunzel syndrome in a four-month pregnant female with twins: the first reported case?. *Cureus* 2018;10:1–5.
- [5] Ripolles T, García-Aguayo J, Martínez MJ, Gil P. Gastrointestinal bezoars: sonographic and CT characteristics. *Am J Roentgenol* 2001;177:65–6.
- [6] Eng K, Kay M. Gastrointestinal bezoars: history and current treatment paradigms. *Gastroenterol Hepatol* 2012;8:776–7.
- [7] Dixit A, Raza MA, Tiwari R. Gastric trichobezoar with Rapunzel syndrome: a case report. *J Clin Diagn Res. JCDR* 2016;10:10–1.
- [8] Cannalire G, Conti L, Celoni M, Grassi C, Cella A, Bensi G, et al. Rapunzel syndrome: an infrequent cause of severe iron deficiency anemia and abdominal pain presenting to the pediatric emergency department. *BMC Pediatr* 2018;18:125–9.
- [9] Nirasawa Y, Mori T, Ito Y, Tanaka H, Seki N, Atomi Y. Laparoscopic removal of a large gastric trichobezoar. *J Pediatr Surg* 1998;33:663–5.
- [10] Athanasiou A, Michalinos A, Moris D, Spartalis E, Dimitrakallis N, Kaminiotis V, et al. Rapunzel syndrome: a rare presentation with giant gastric ulcer. *Case Rep Med* 2014;10:1–4.
- [11] Cintolo J, Telem DA, Divino CM, Chin EH, Midulla P. Laparoscopic removal of a large gastric trichobezoar in a 4-year-old girl. *J Soc Laparoendosc Surg* 2009;13:608–11.
- [12] Fraser JD, Leys CM, St Peter SD. Laparoscopic removal of a gastric trichobezoar in a pediatric patient. *J Laparoendosc Adv Surg Tech* 2009;19:835–7.
- [13] Dom HF, Gillick JL, Stringel G. Laparoscopic intragastric removal of giant trichobezoar. *J Soc Laparoendosc Surg* 2010;14:259–62.
- [14] Lalith S, Gopalakrishnan KL, Ilangovan G, Jayajothi A. Rapunzel syndrome. *J Clin Diagn Res* 2017;11:TD01–2.

# Combined endoscopy-laparoscopy-gastronomy extraction for rapunzel syndrome

## ORIGINALITY REPORT

9%

SIMILARITY INDEX

12%

INTERNET SOURCES

7%

PUBLICATIONS

7%

STUDENT PAPERS

## PRIMARY SOURCES

1

Submitted to Chester College of Higher Education

Student Paper

3%

2

Submitted to University of Wales Institute, Cardiff

Student Paper

2%

3

[joi-journal.springeropen.com](http://joi-journal.springeropen.com)

Internet Source

2%

4

Submitted to German University of Technology in Oman

Student Paper

2%

Exclude quotes On

Exclude matches < 2%

Exclude bibliography On